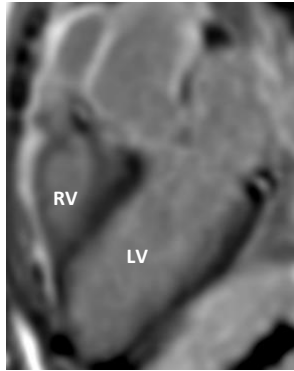
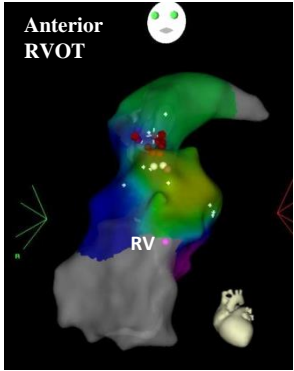
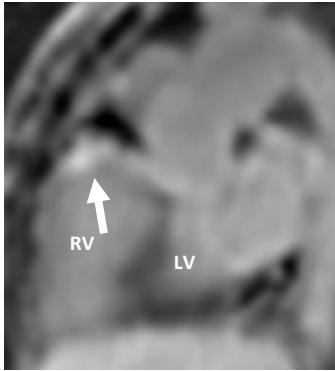
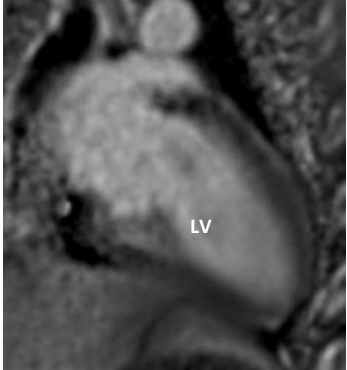
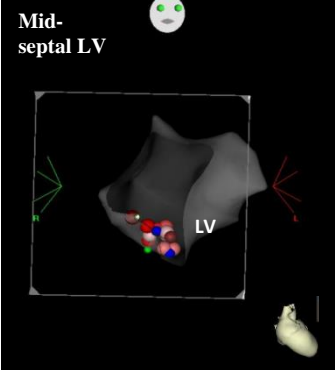
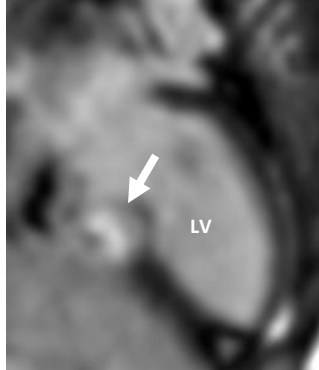
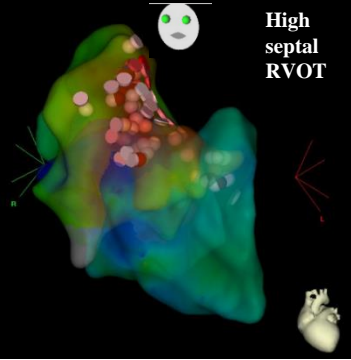
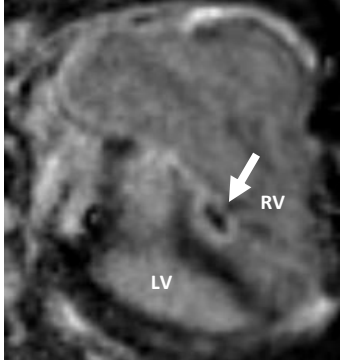
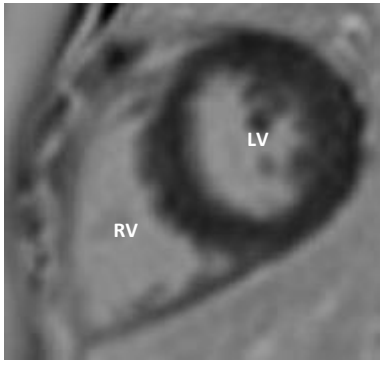
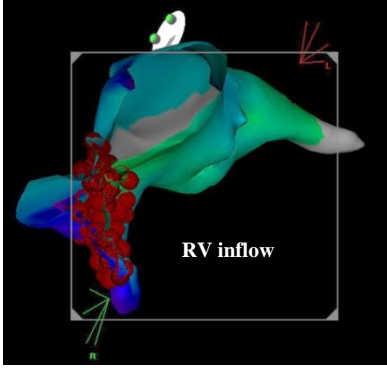
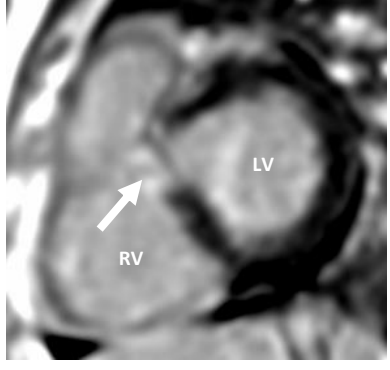
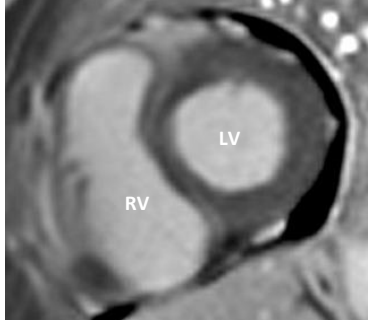
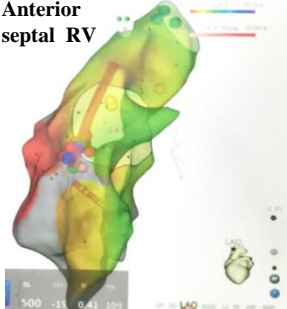
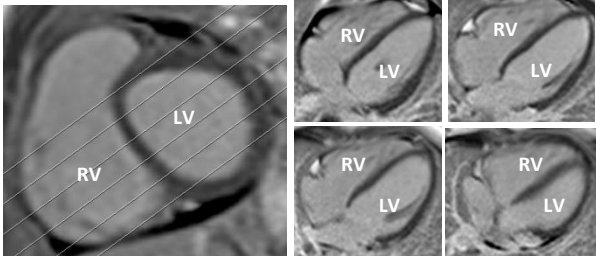
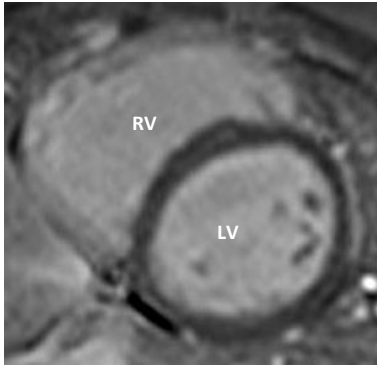
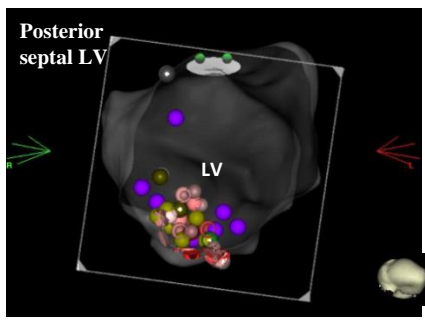
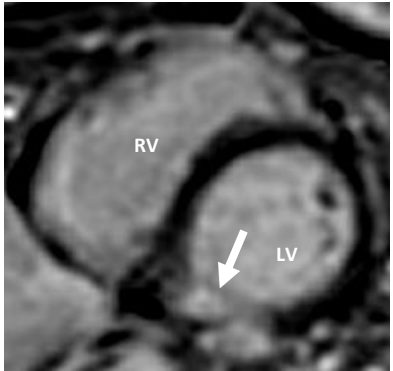
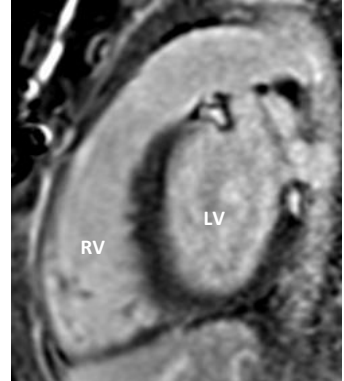
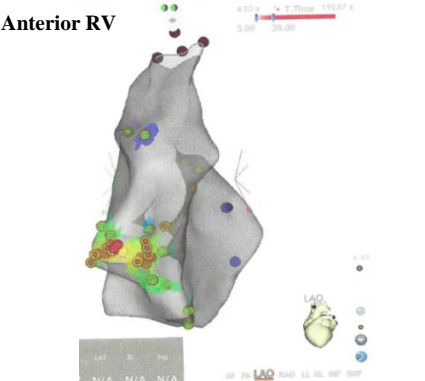
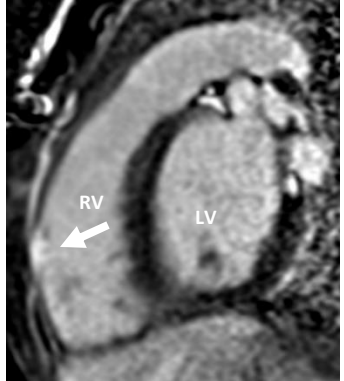
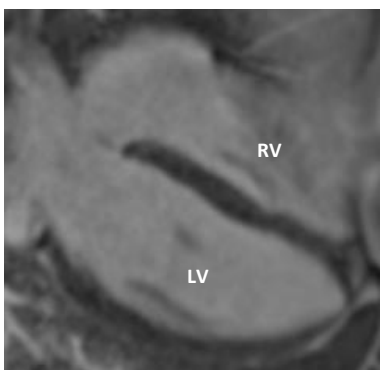
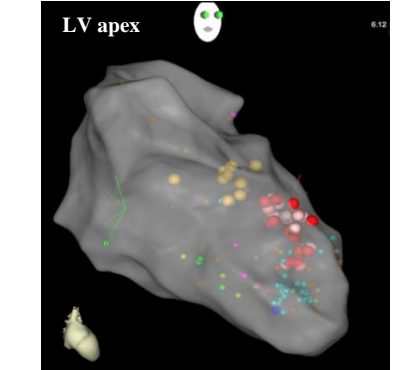
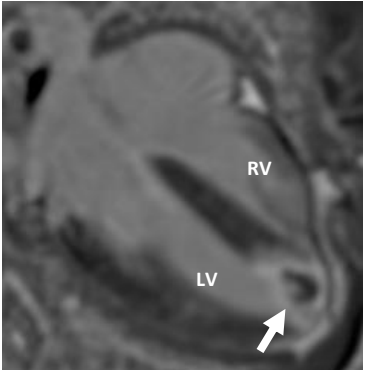
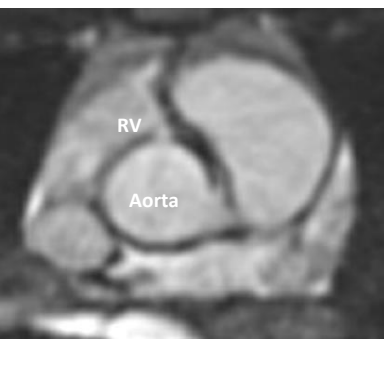
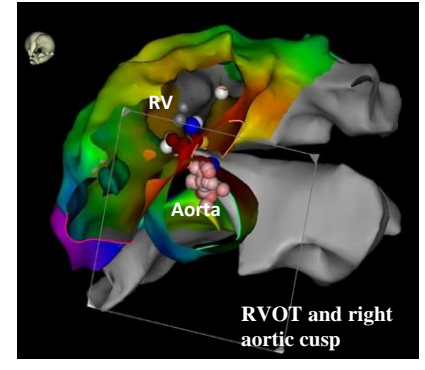
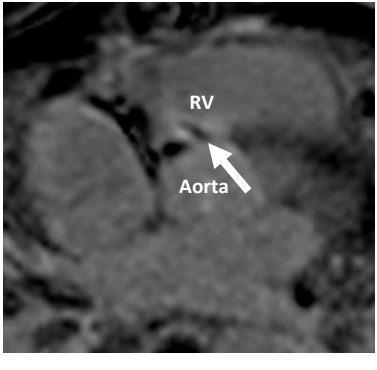

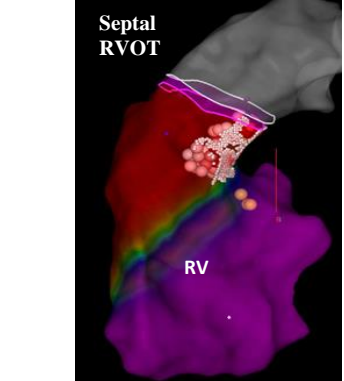


Case	Pre-ablation CMR (No LGE identified)	Ablation location and 3D electroanatomic map with ablation sites (red dots)	Post-ablation CMR LGE (white arrows)
1			
2			
3	<p>No pre-ablation CMR</p>		
4			
5			 <p>No visible LGE in cross-sectional short/long axis planes</p>

6		 <p>Posterior septal LV</p>	
7		 <p>Anterior RV</p>	
8		 <p>LV apex</p>	
9*		 <p>RVOT and right aortic cusp</p>	
10		 <p>Septal RVOT</p>	