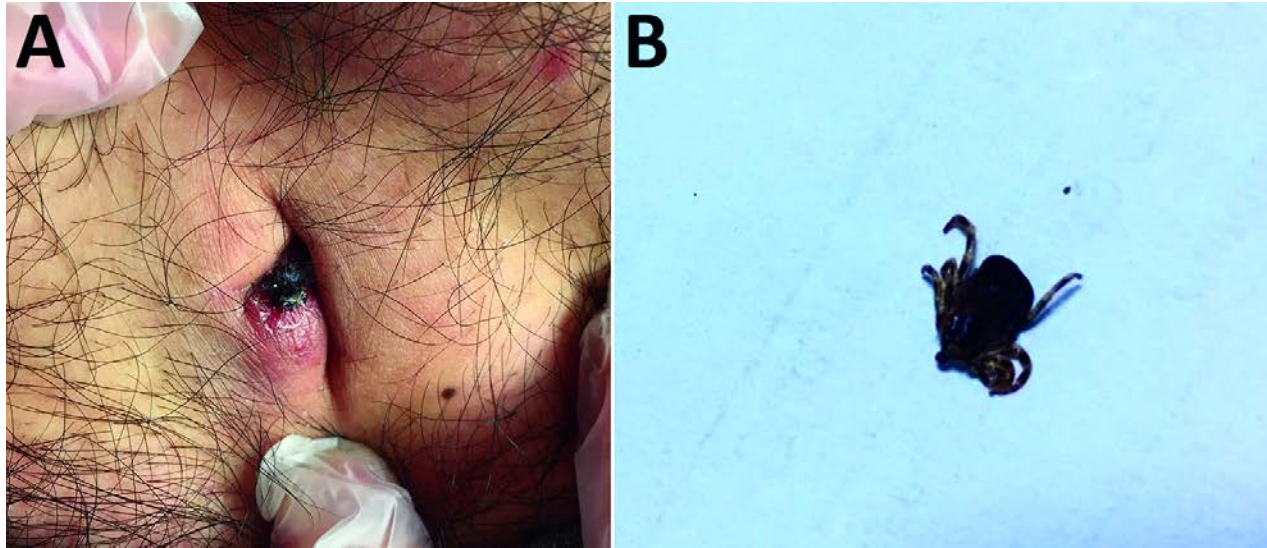


Rickettsia sibirica mongolitimonae Infection, Turkey, 2016

Technical Appendix



Technical Appendix Figure. *Rickettsia sibirica mongolitimonae* infection in man, Turkey, 2016. A) Black necrotic eschar on the umbilicus of the patient. B) *Hyalomma marginatum* female tick removed from the patient.