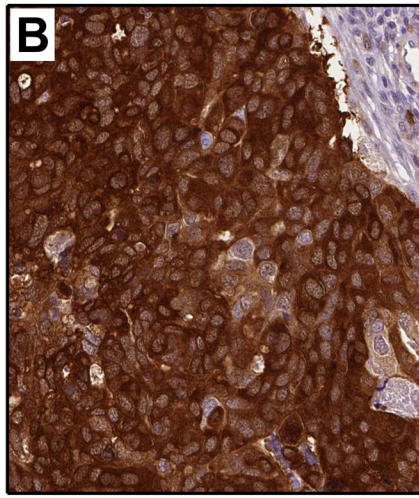
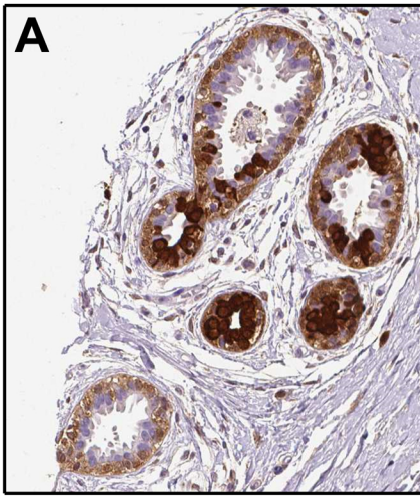
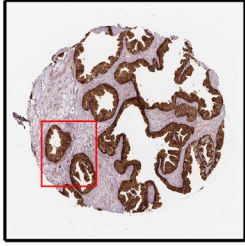

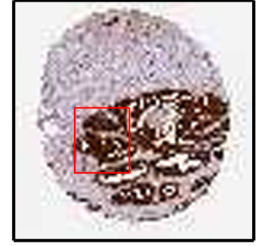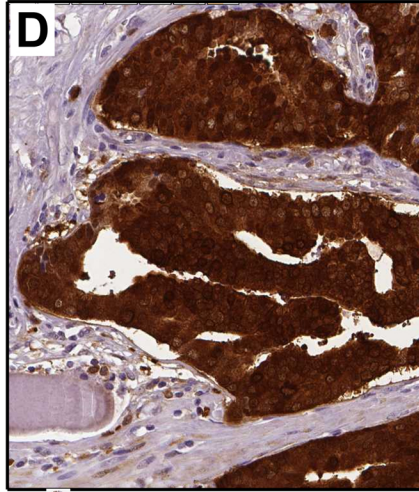
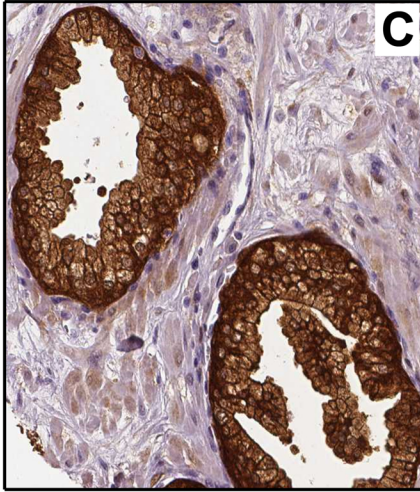Breast
Female, age 49
Normal tissue
Patient id: 4930



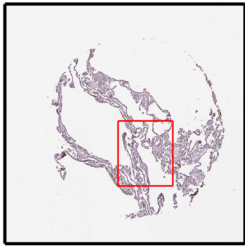
Breast cancer
Female, age 83
Duct carcinoma
Patient id: 2160



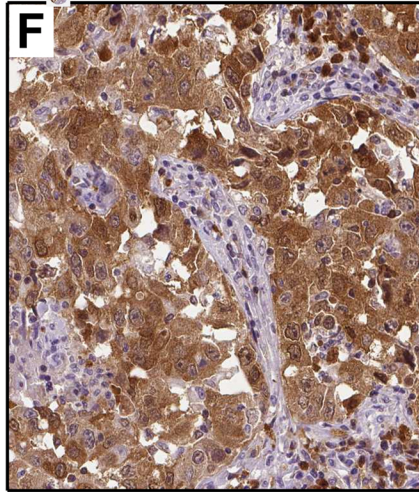
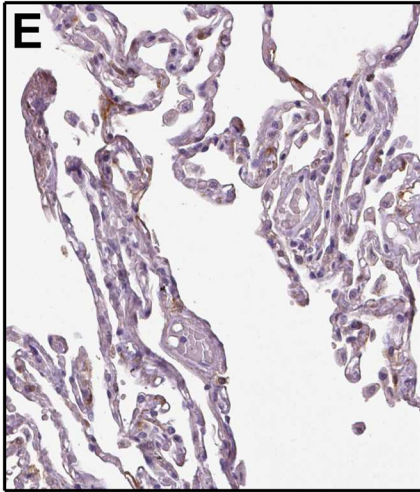
Prostate
Male, age 61
Normal tissue
Patient id: 1984



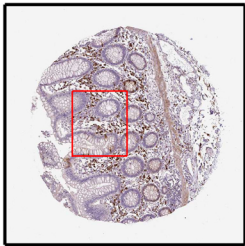
Prostate cancer
Male, age 44
Adenocarcinoma
Patient id: 5415



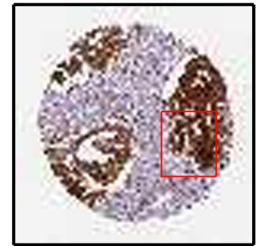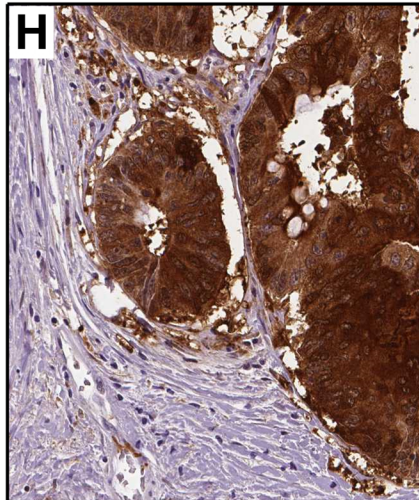
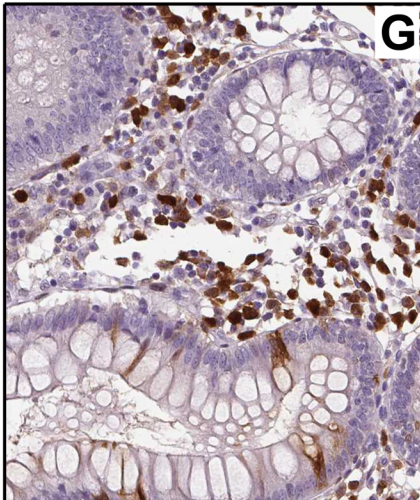
Lung
Female, age 67
Normal tissue
Patient id: 2208



Lung cancer
Male, age 73
Adenocarcinoma
Patient id: 1907



Colon
Male, age 83
Normal tissue
Patient id: 1962



Colorectal cancer
Male, age 59
Adenocarcinoma
Patient id: 795