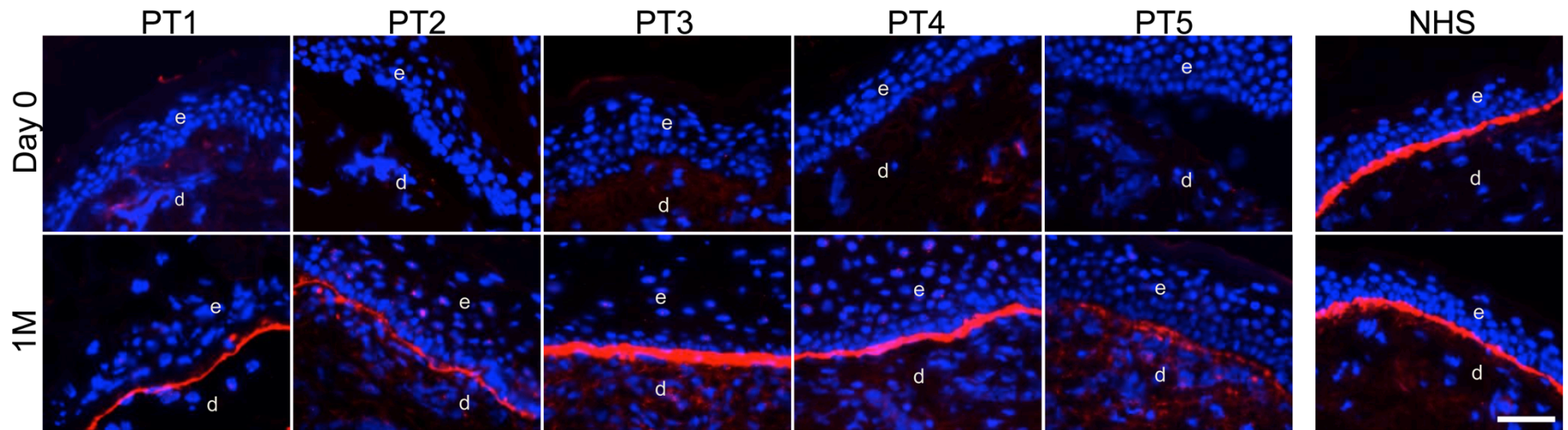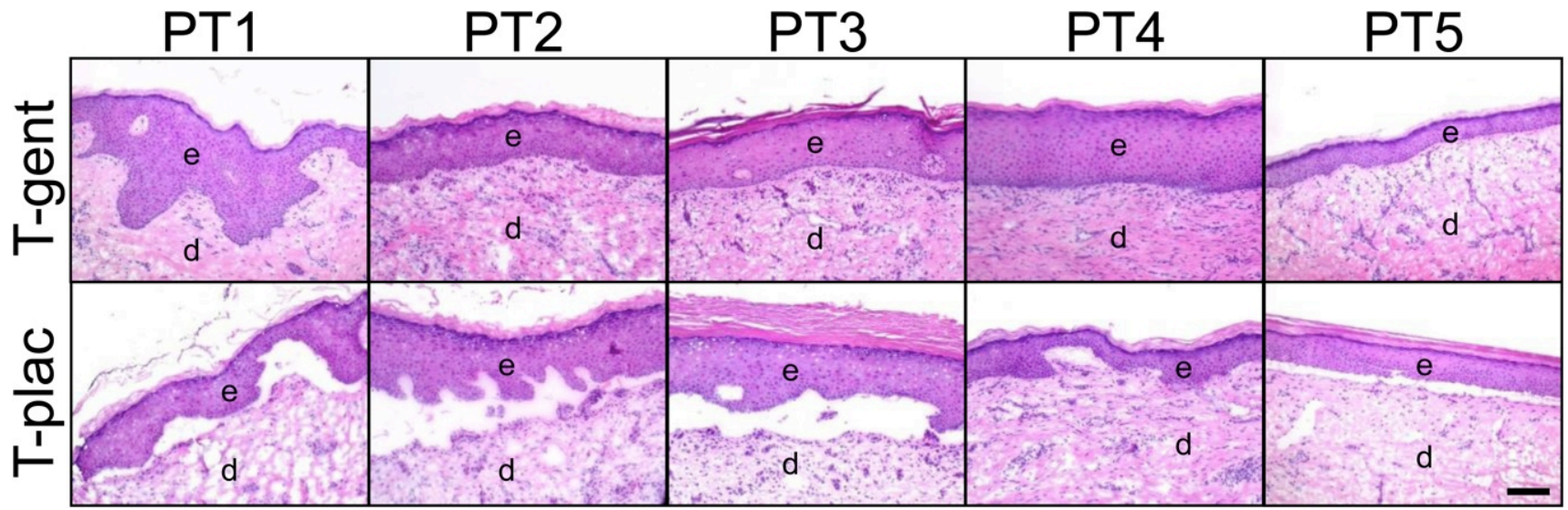


Supplemental Figure 1. Topical gentamicin treatment generated new full-length C7 in RDEB patients.

Immunofluorescence staining with a monoclonal antibody, LH24, to the C-terminal non-collagenous domain (NC2) of C7 on skin biopsy specimens taken at day 0, and at one month (1M) after topical gentamicin treatment. Note that gentamicin induced full-length C7 at the DEJ of all five patients' skin. In contrast, patient skin before treatment did not express any full length C7. PT, patient; RDEB, recessive dystrophic epidermolysis bullosa; C7, type VII collagen ; NHS, normal human skin; DEJ, dermal-epidermal junction; e, epidermis; d, dermis. Scale bar is 50 μ m.



Supplemental Figure 2. Topical gentamicin treatment improved dermal-epidermal adherence. Hematoxylin and Eosin staining of frozen sections from the above one month biopsy samples. Upper panels represent all five patients' Test Sites treated with gentamicin, T-gent, while the bottom panels show the patients' Test Sites treated with topical placebo, T-plac. Note that the gentamicin-treated Test Sites exhibit intact dermal-epidermal adherence while the placebo-treated Test Sites reveal dermal-epidermal separation. PT, patient; e, epidermis; d, dermis. Scale bar is 50 μ m.