Figure S1

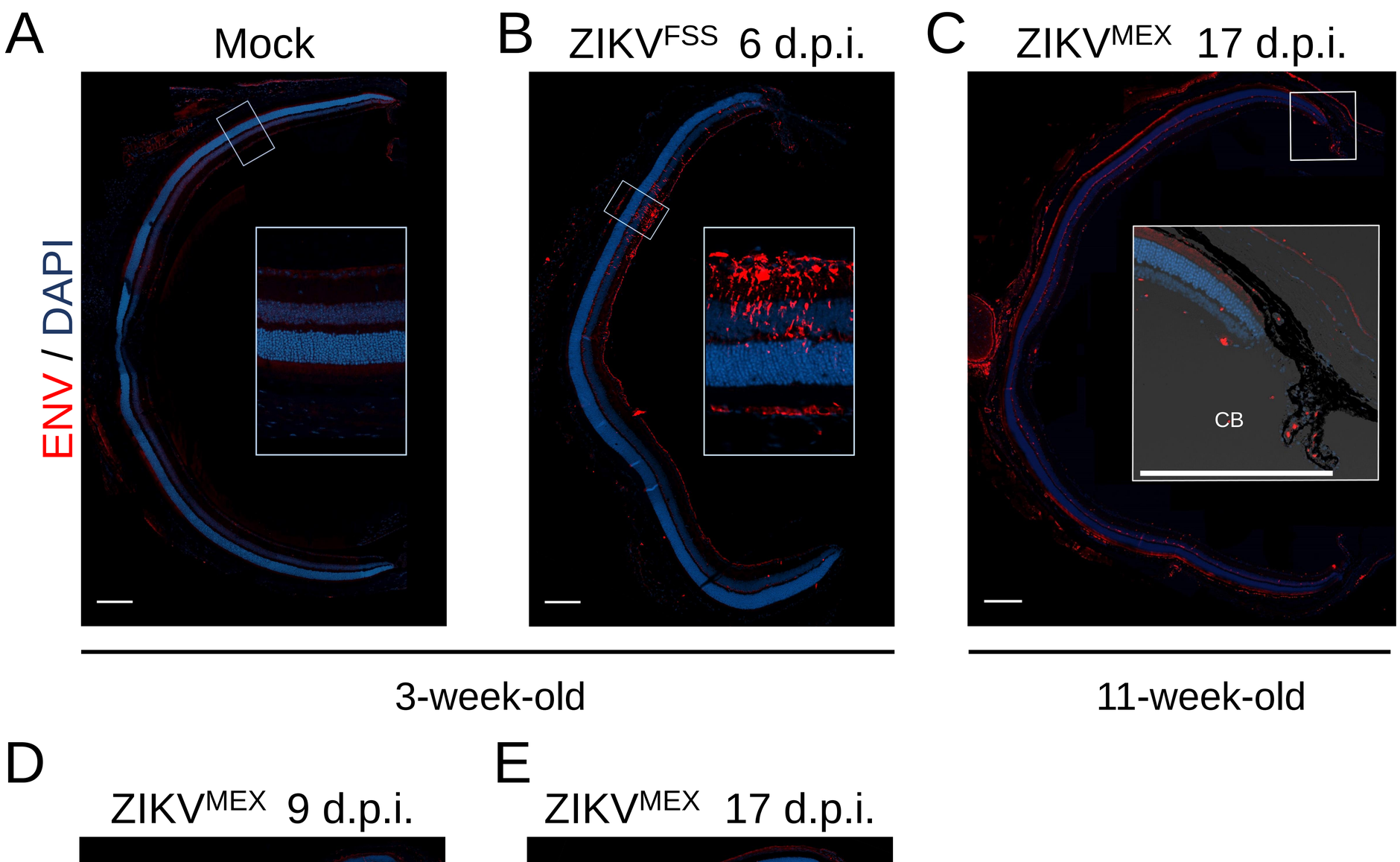

Figure **S1**: **Age- and time-dependent ZIKV infection in the retina.** Panoramic images of whole retinal sagittal sections with ZIKV ENV staining. Samples in **A, B, D and E** were collected from 3-week-old mice inoculated with either ZIKV^{FSS} or ZIKV^{MEX}. Panel **C** is a representative image from an 11-week-old mice infected with ZIKV^{FSS} for 17days. CB, ciliary body. Scale bar = 200 µm.

Figure S2

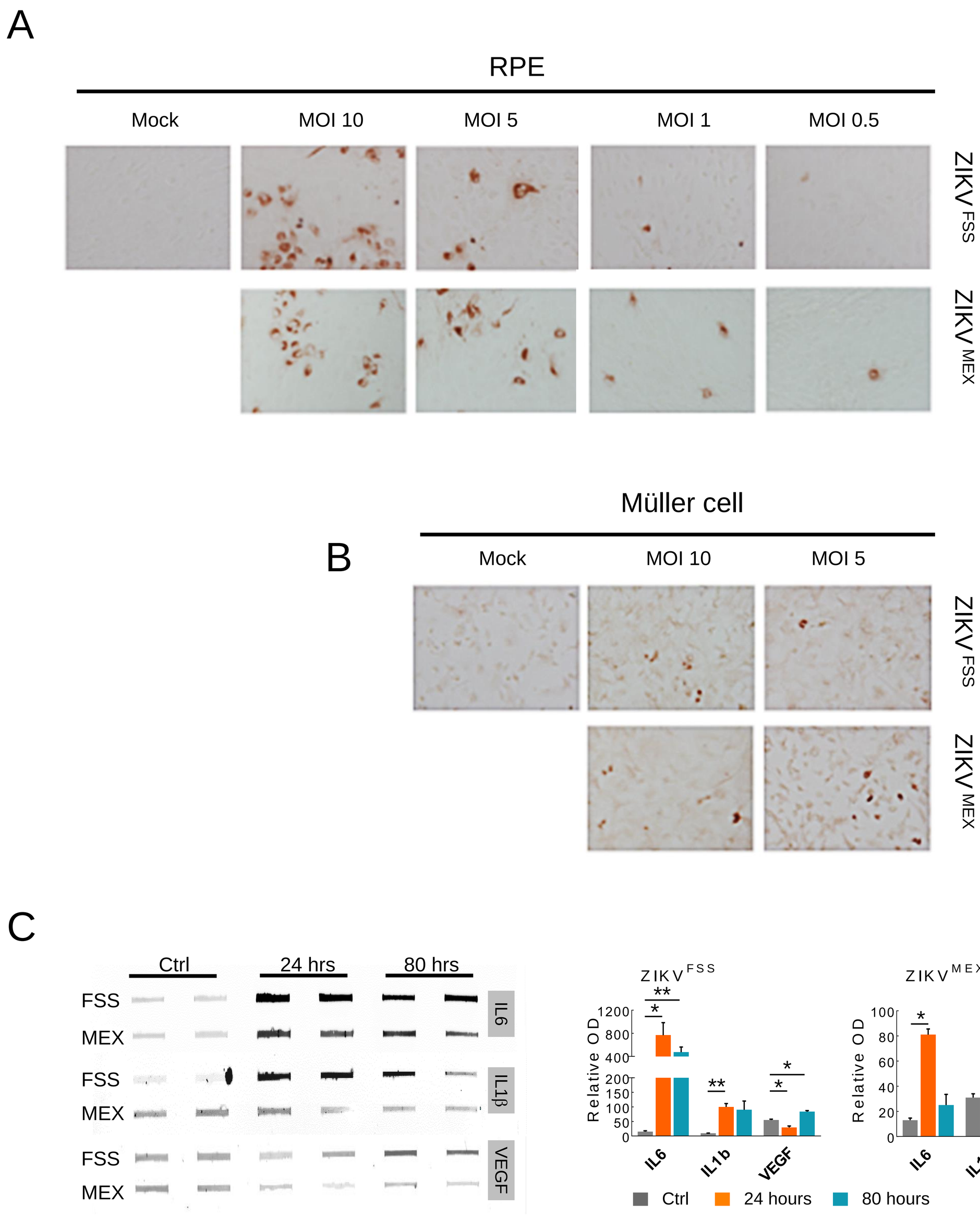

Figure **S2: ZIKV infects primary cultured RPE and Müller cells.** (**A** and **B**) Representative images of virus staining in RPE and Müller cells for plaque-forming assay. (**C**) Cytokine dot-blot of cultured Müller cell supernates collected at 0, 24 and 80 hours after ZIKV infection. Experiments were carried out at MOI=5 and repeated for 3 times. Data were analyzed by One-way ANOVA with *Turkey* test for multiple comparison. *$p<0.05$, **$p<0.01$.

Figure S3

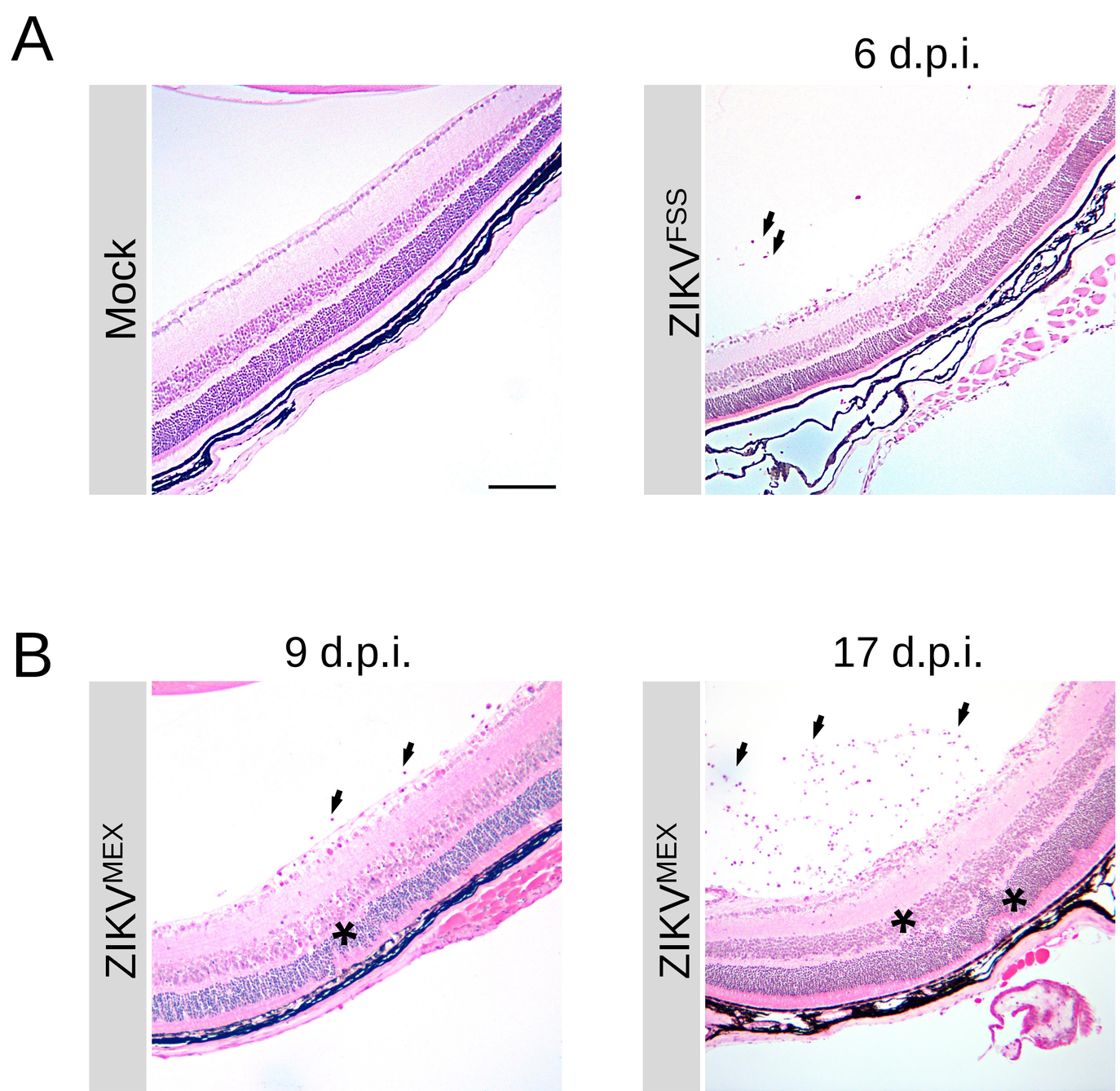

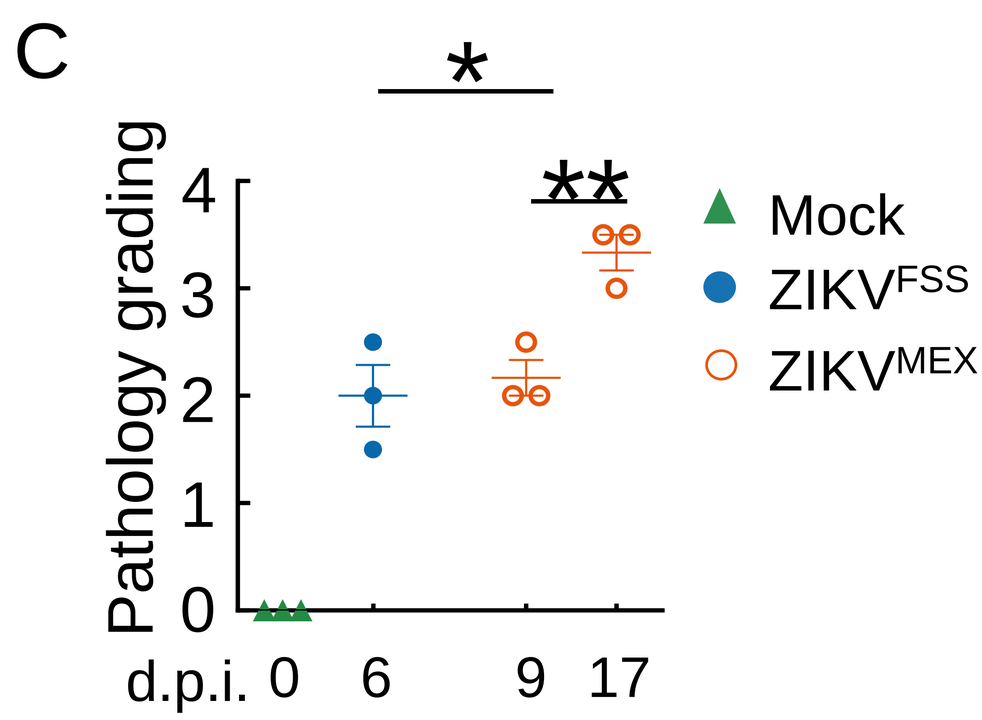

Figure **S3**: **Retinal inflammation and pathology caused by ZIKV infection**. (**A** and **B**) Representative images of H&E stained retinal sections at indicated time points post ZIKV inoculation. Arrows, intravitreal cell infiltration; asterisks, retinal folding with photoreceptor loss. (**C**) Severity of retinal damage was scored as mentioned before. Data were presented as mean ± s.e.m. *P<0.05, **P<0.01. Scale bar = 200 μm,

Figure S4

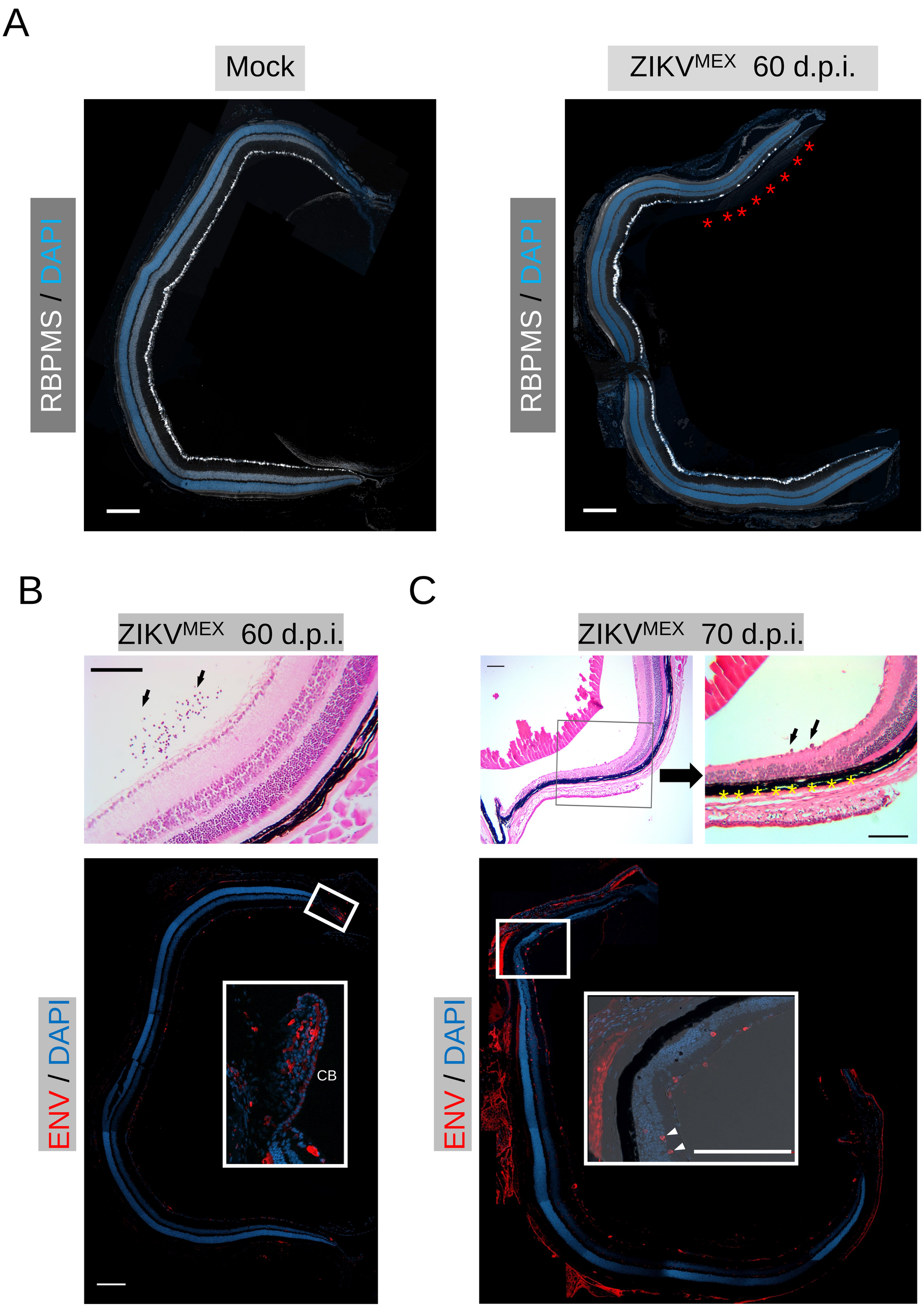

Figure **S4**: **Long-term retinal consequences of ZIKV infection.** (**A**) Retinal sections from both mock and 60 dpi ZIKV^{MEX} infected mouse were stained with retinal ganglion cell marker (RBPMS). Representative areas of RGC loss were indicated by asterisks. (**B** and **C**) Histology and ZIKV ENV staining of retina from two long term infected mice with different tissue damage. Arrows, intravitreal cell infiltrates; asterisks, area of severe retinal degeneration with total loss of photoreceptors; arrowheads, residual retinal viral staining in the inner nuclear layer. Scale bars= 200 µm