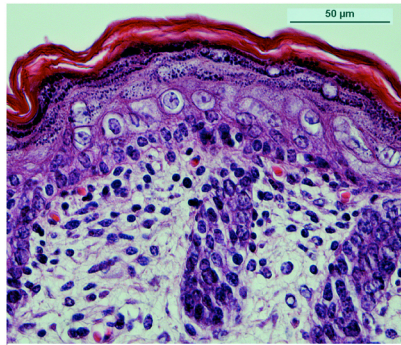
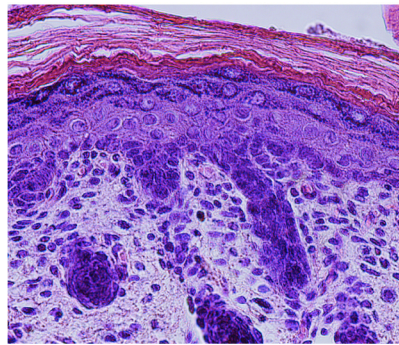


control



-/-



Supplementary figure 1  
Tunggal et al.

**Supplementary figure 1:** Histological appearance of newborn control and K14-Cre/Ecad<sup>F1/-</sup> (-/-) skin. Paraffin sections were stained with haematoxylin and eosin.