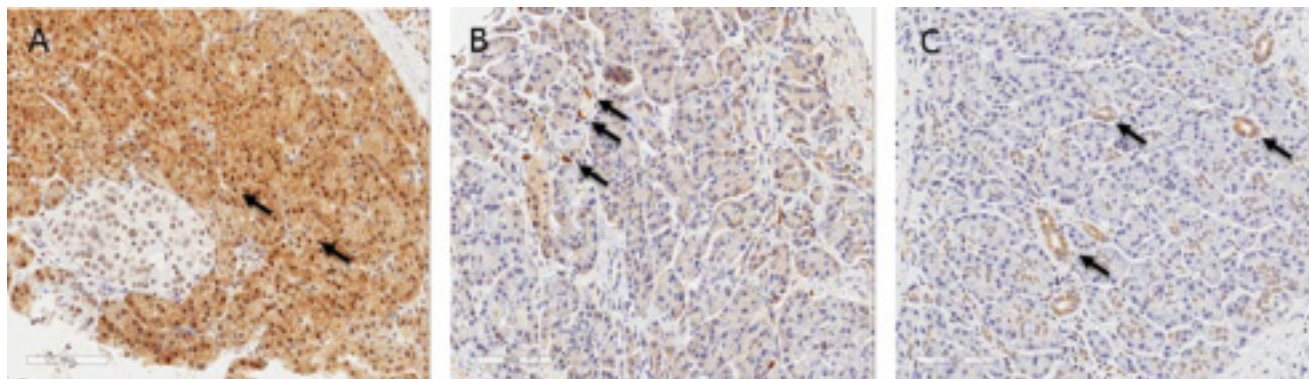


## DAXX/ATRX and MEN1 genes are strong prognostic markers in pancreatic neuroendocrine tumors

### Supplementary Materials



**Supplementary Figure 1: Representative pictures of internal control of immunostaining.** (A) Positive staining of MEN1 in nuclei of non-neoplastic acinar cells MEN1 (arrow), (B) Positive staining of ATRX in macrophages or lymphocytes (arrow), (C) Positive staining of DAXX in cytoplasm of non-neoplastic ductal epithelial cells (all pictures  $\times 200$ ).