

## Supplementary Information

### **Tracheal reconstruction with a free vascularized myofascial flap: preclinical investigation in a porcine model to human clinical application**

Won Shik Kim<sup>a</sup>, Jae Won Chang<sup>b</sup>, Woo Soon Jang<sup>c</sup>, Young Joon Seo<sup>d</sup>, Mi-Lan Kang<sup>e</sup>, Hak-Joon Sung<sup>e,f</sup>, Da Hee Kim<sup>a</sup>, Jung Min Kim<sup>a</sup>, Jae Hong Park<sup>g</sup>, Myung Jin Ban<sup>g</sup>, Gina Na<sup>a</sup>, Seung Ho Shin<sup>a</sup>, Hyung Kwon Byeon<sup>a</sup>, Yoon Woo Koh<sup>a</sup>, Se-Heon Kim<sup>a</sup>, Hong Koo Baik<sup>c</sup>, Eun Chang Choi<sup>a</sup>

<sup>a</sup>Department of Otorhinolaryngology, Yonsei University College of Medicine, Seoul, Korea

<sup>b</sup>Department of Otolaryngology-Head and Neck Surgery, Cancer Research Institute, Research Institute for Medical Sciences, Chungnam National University College of Medicine, Daejeon, Korea

<sup>c</sup>Department of Materials Science & Engineering, Yonsei University, Seoul, Korea

<sup>d</sup>Department of Otorhinolaryngology, Yonsei University Wonju College of Medicine, Wonju, Korea

<sup>e</sup>Severance Biomedical Science Institute, College of Medicine, Yonsei University, Seoul, Korea

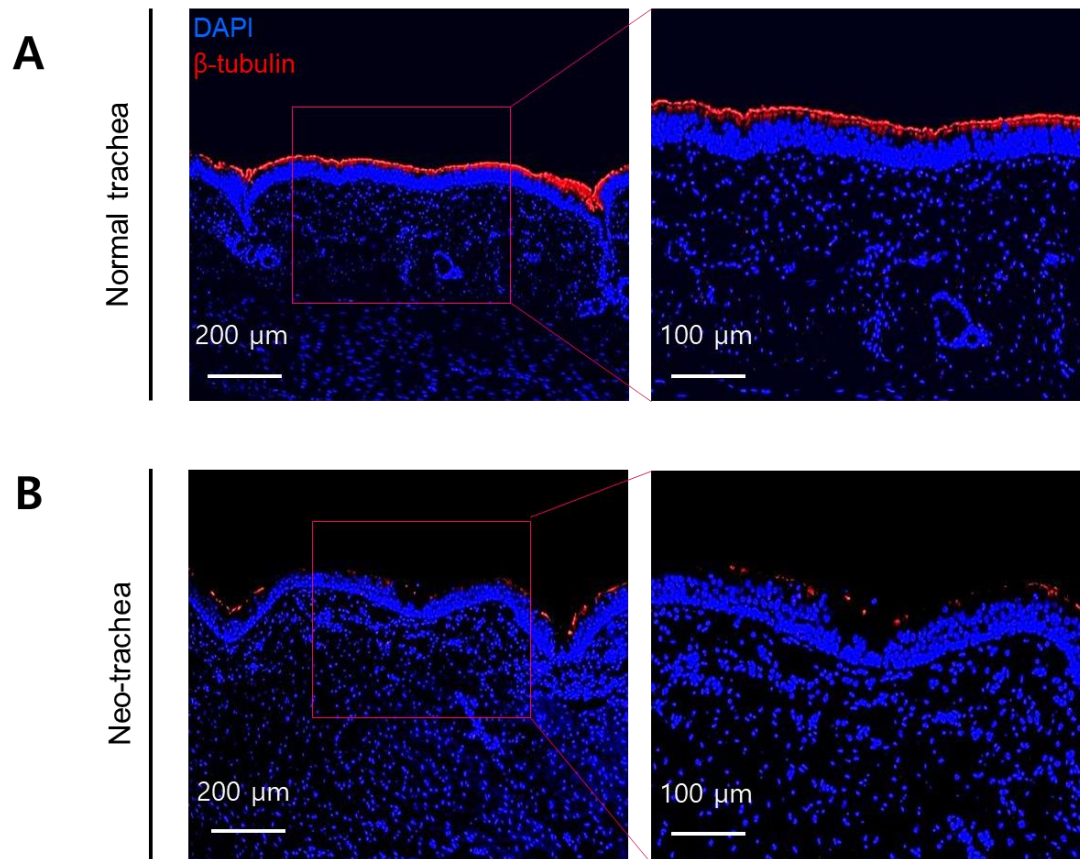
<sup>f</sup>The George W. Woodruff School of Mechanical Engineering, Georgia Institute of Technology, Atlanta, United States

<sup>g</sup>Department of Otorhinolaryngology, Soonchunhyang University College of Medicine, Cheonan, Korea

Correspondence and requests for materials should be addressed to W.S.K. and J.W.C

([wskim78@yuhs.ac](mailto:wskim78@yuhs.ac) & [strive1005@hanmail.net](mailto:strive1005@hanmail.net))

Supplementary Figure S1



**Figure S1. *In vitro* evaluation of fluorescence-labeled cilia in normal trachea and neo-tracheal epithelium at post-operative 12 weeks.** A. The normal trachea revealed fluorescence-labeled cilia. Higher magnification of the normal trachea showed cilia lining whole epithelium. B. The neo-trachea showed scanty fluorescence-labeled cilia. Higher magnification of the neo-trachea indicated scanty but obviously present cilia.