

Supplementary Materials: Recreational Exposure during Algal Bloom in Carrasco Beach, Uruguay: A Liver Failure Case Report

Flavia Vidal, Daniela Sedan, Daniel D'Agostino, María Lorena Cavalieri, Eduardo Mullen, María Macarena Parot Varela, Cintia Flores, Josep Caixach and Dario Andrinolo

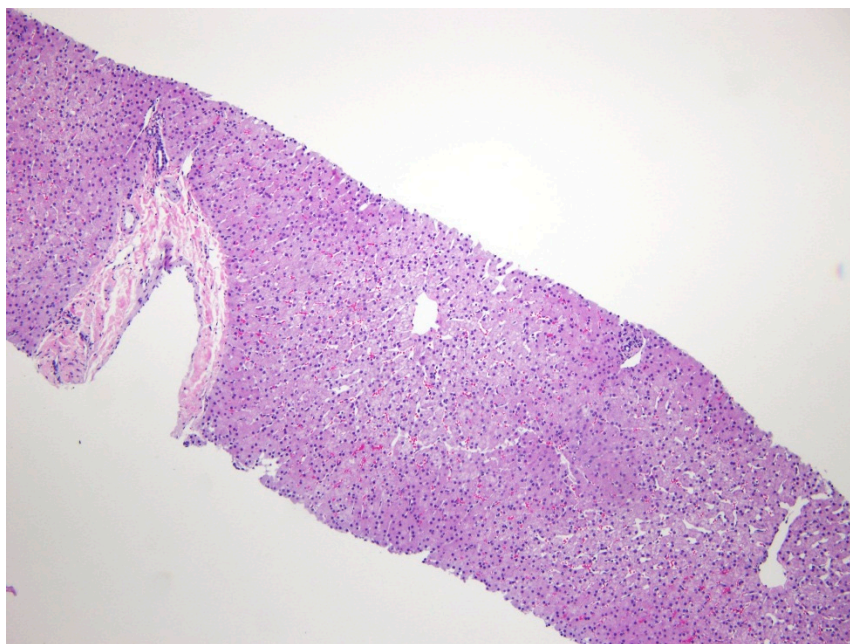


Figure S1. Representative slice H and E stained of normal liver (100X) shown a radial hepatocyte arrangement around the vessels characteristics of normal liver parenchyma. Note there are not hemorrhage around the central vein.

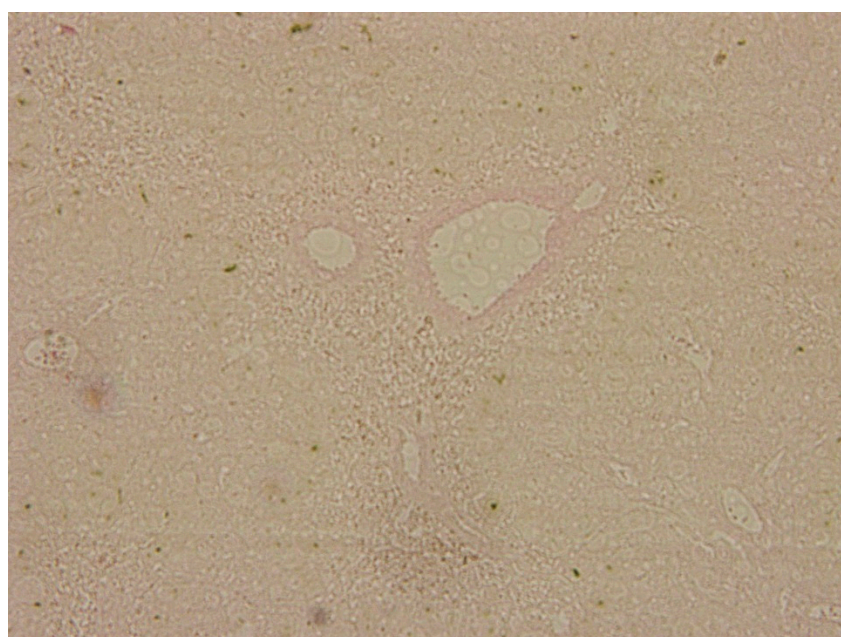


Figure S2. Representative slices of explanted liver stained with Perls technique (100X). Note there is no accumulation of iron in the liver parenchyma.

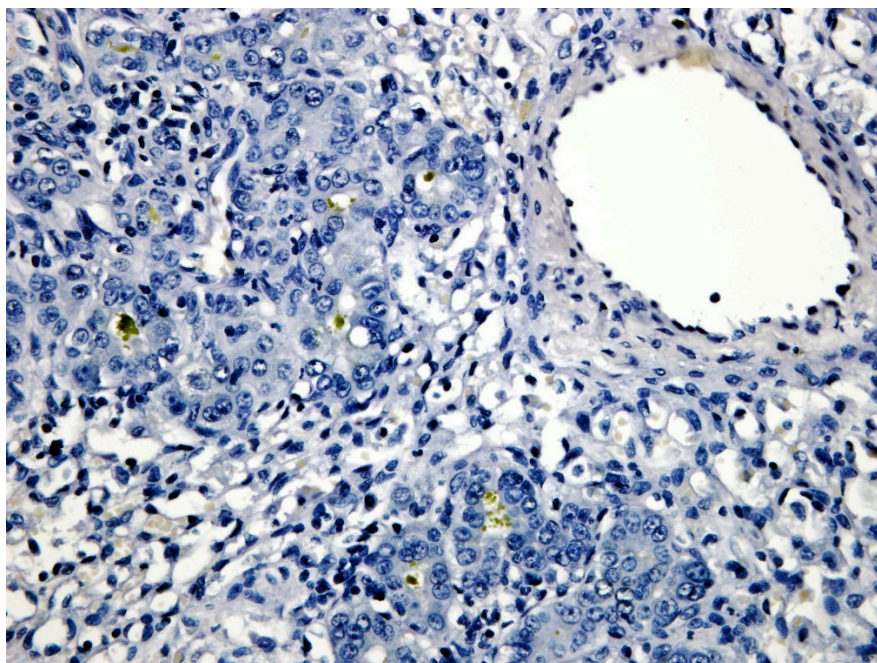


Figure S3. Representative slices of explanted liver stained with Rhodamine techniques (400X). The results were negative for copper accumulation in liver parenchyma.