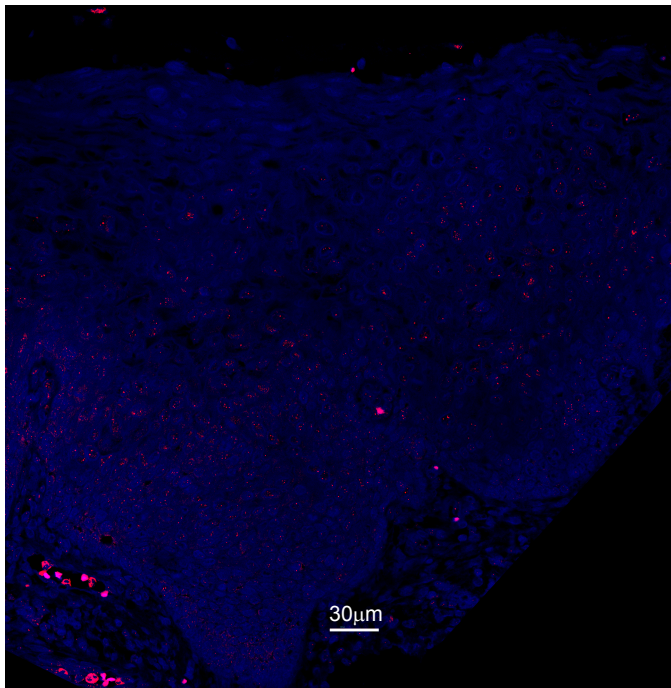
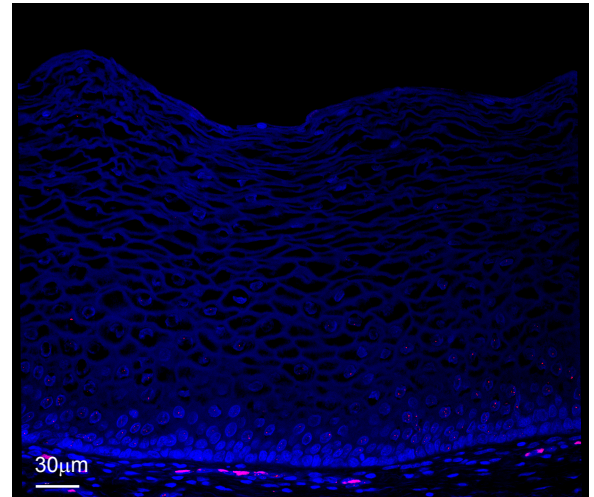


HPV16 + cervix



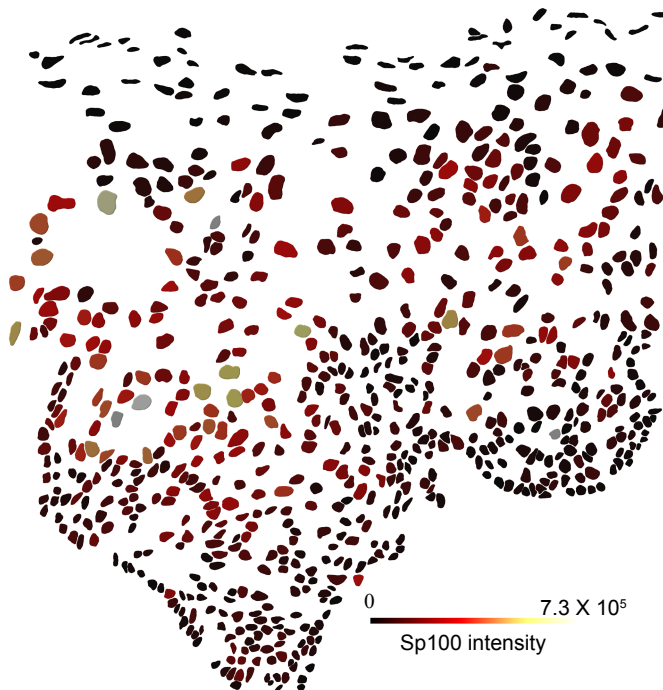
normal cervix



stratum  
granulosum

stratum  
spinosum

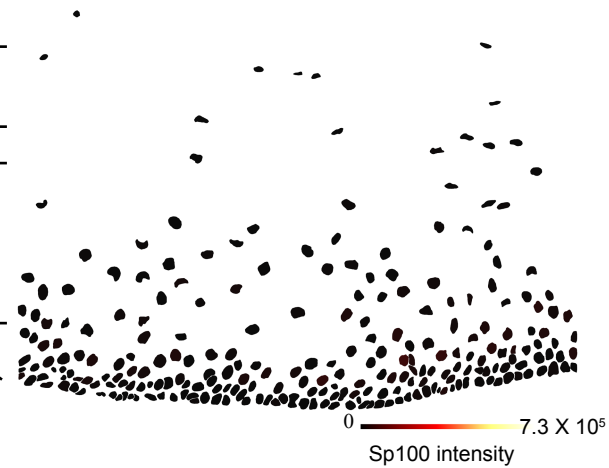
stratum  
basale



stratum  
granulosum

stratum  
spinosum

stratum  
basale



0  $7.3 \times 10^5$   
Sp100 intensity

0  $7.3 \times 10^5$   
Sp100 intensity