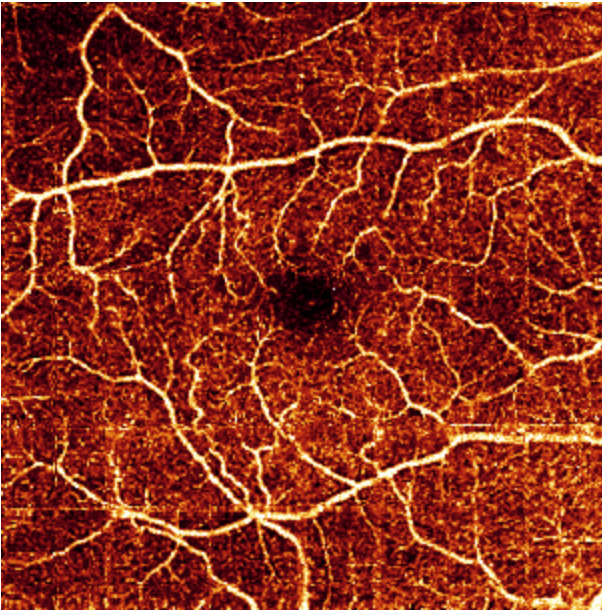


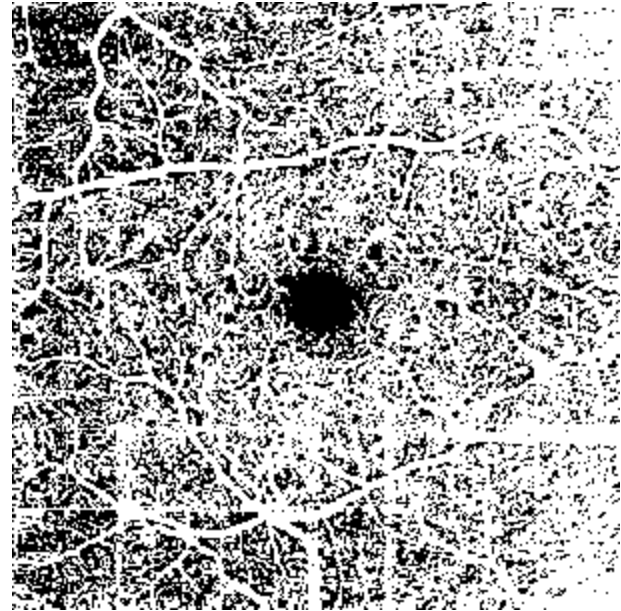
Supplemental File:  
Normal Eyes OCT Angiograms

# Normal SVC Case 1

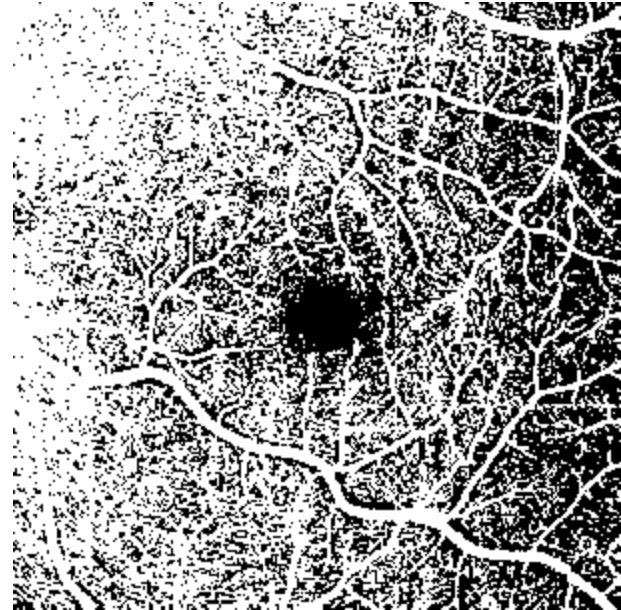
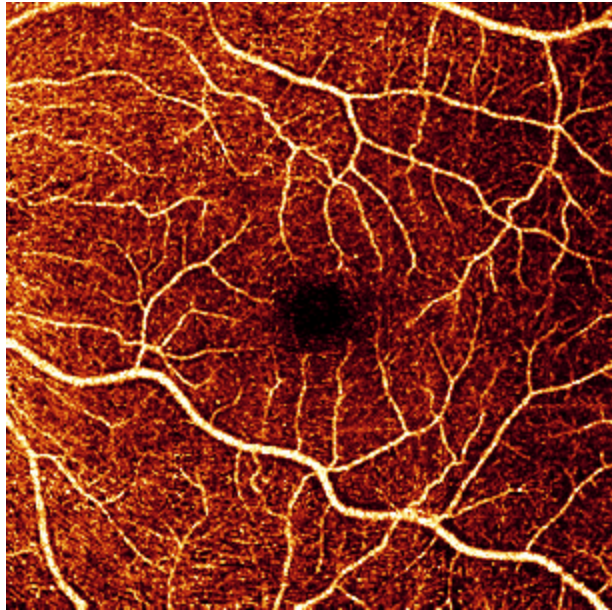
Angiogram



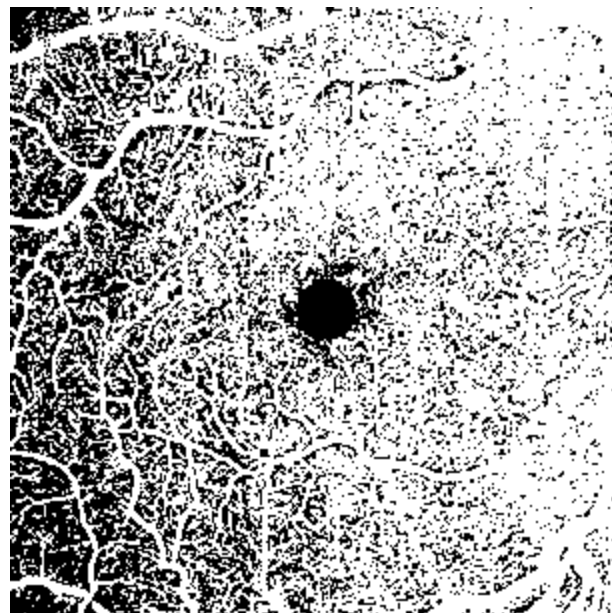
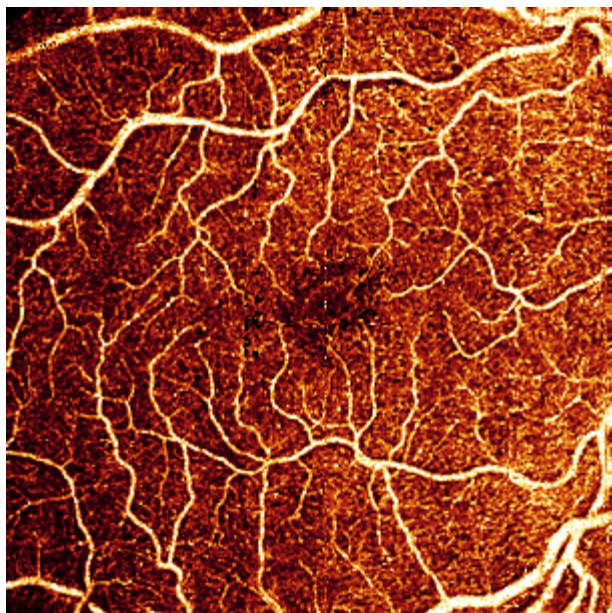
Binarized image used to calculate vessel density



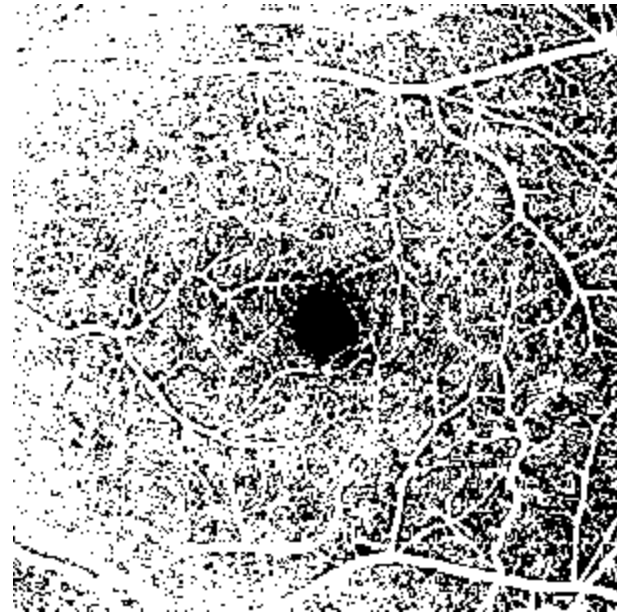
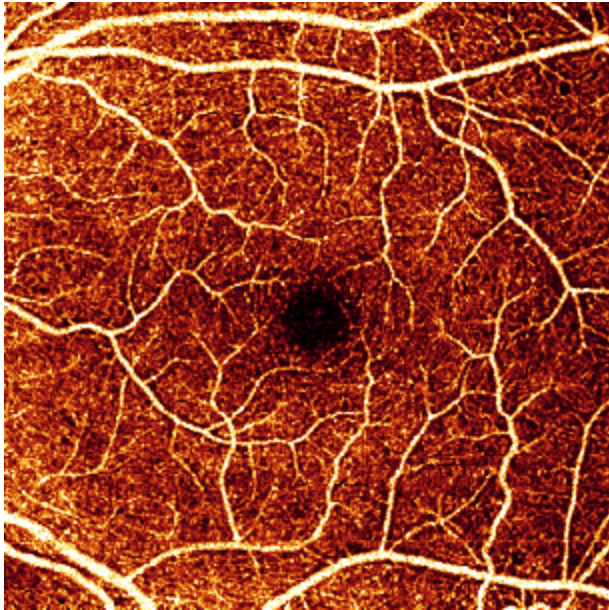
# Normal SVC Case 2



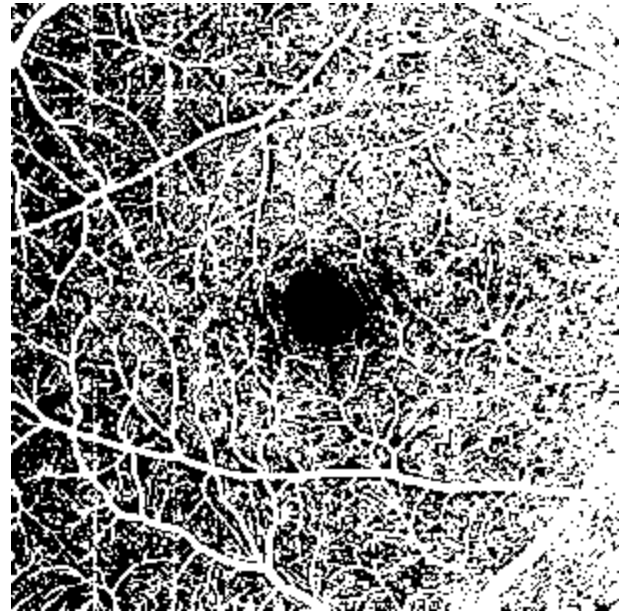
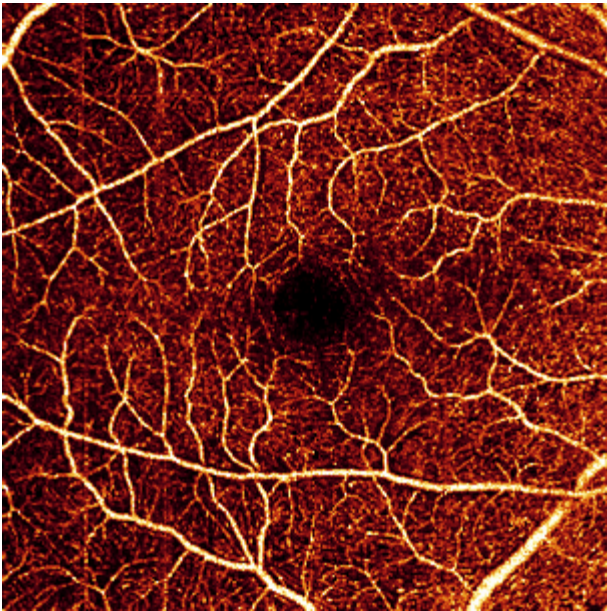
# Normal SVC Case3




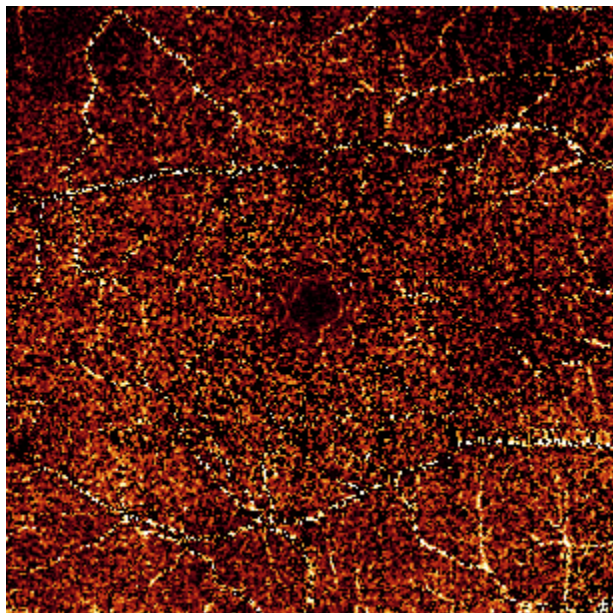
# Normal SVC case 4



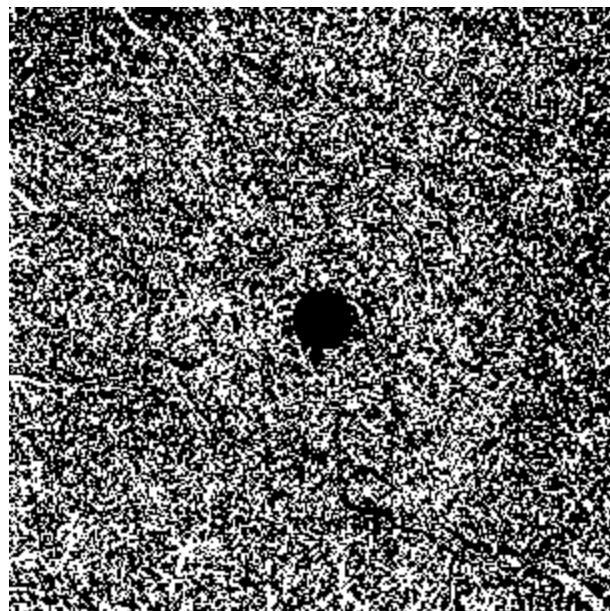
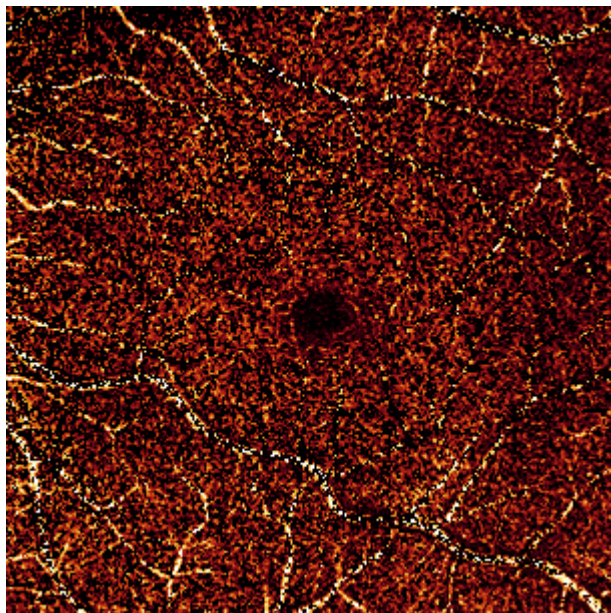
# Normal SVC Case5



# Normal ICP Case 1

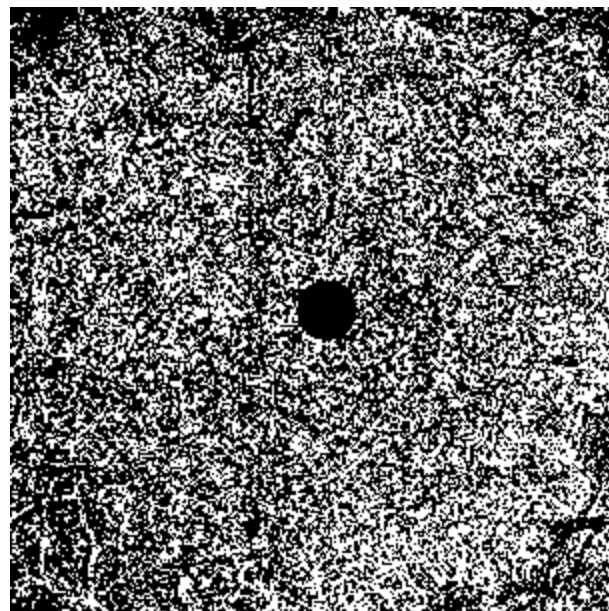
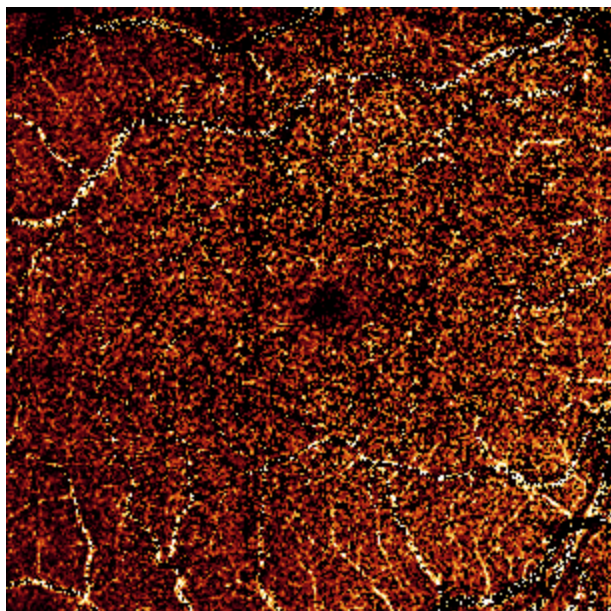


# Normal ICP Case 2


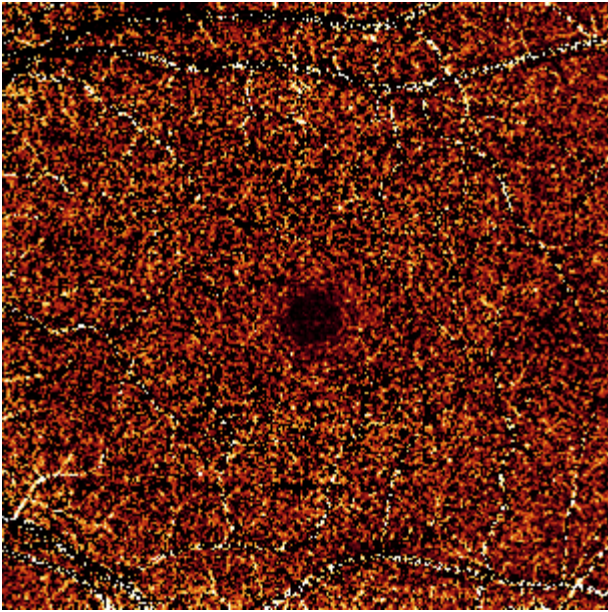





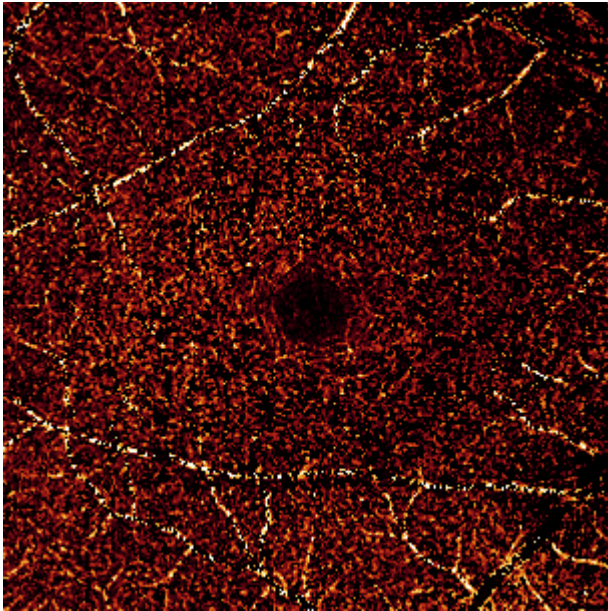
# Normal ICP Case3





# Normal ICP case 4



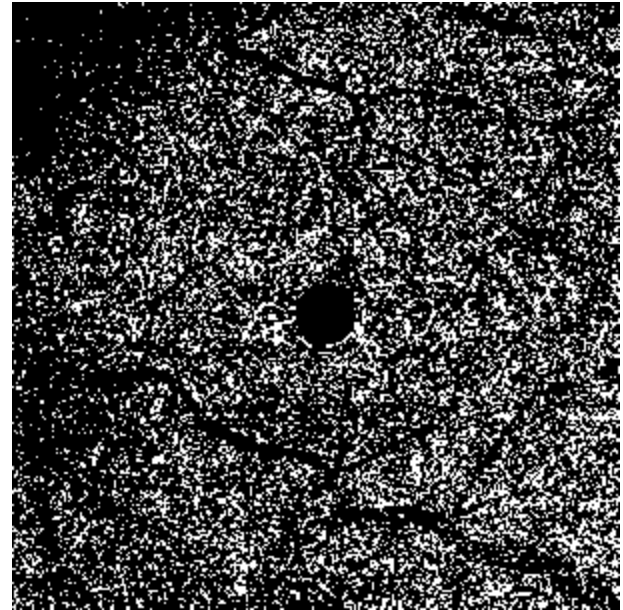
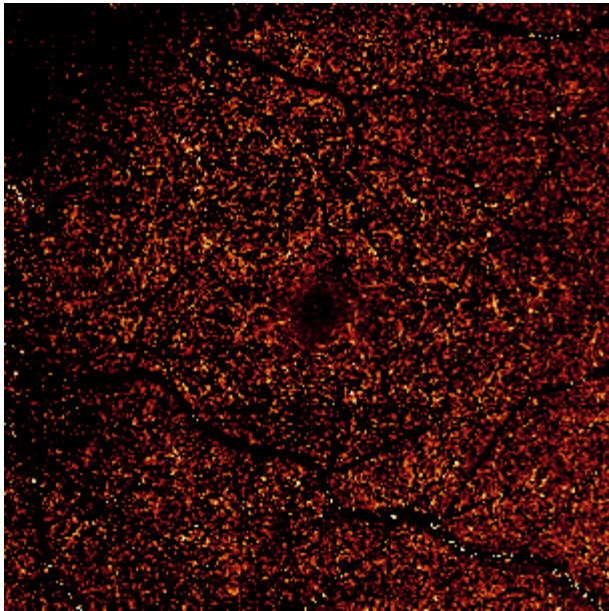
# Normal ICP Case5



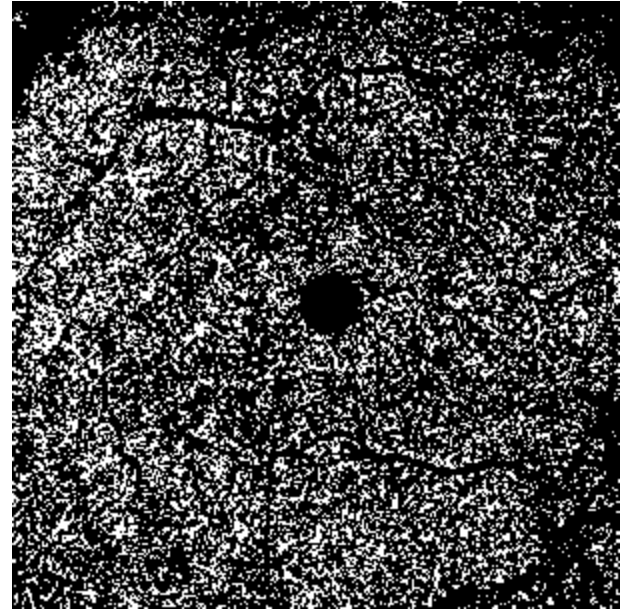
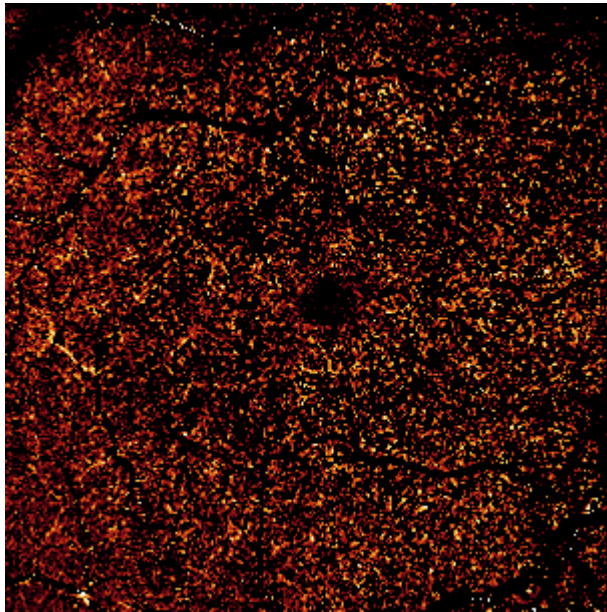
# Normal DCP Case 1



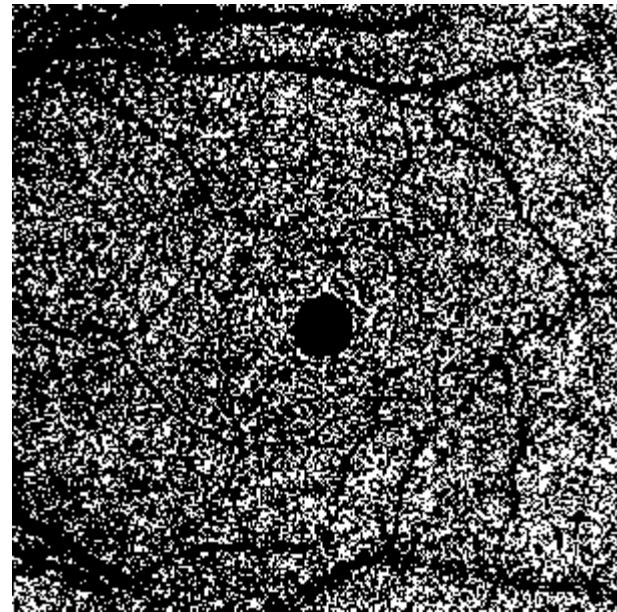
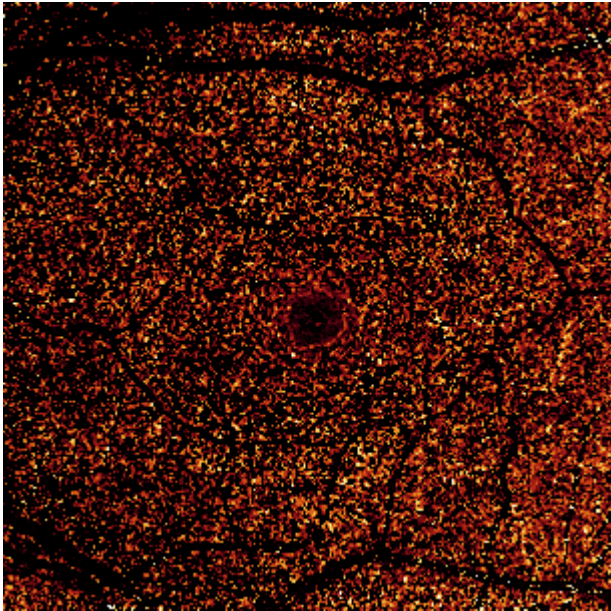
# Normal DCP Case 2



# Normal DCP Case3



# Normal DCP case 4



# Normal DCP Case5

