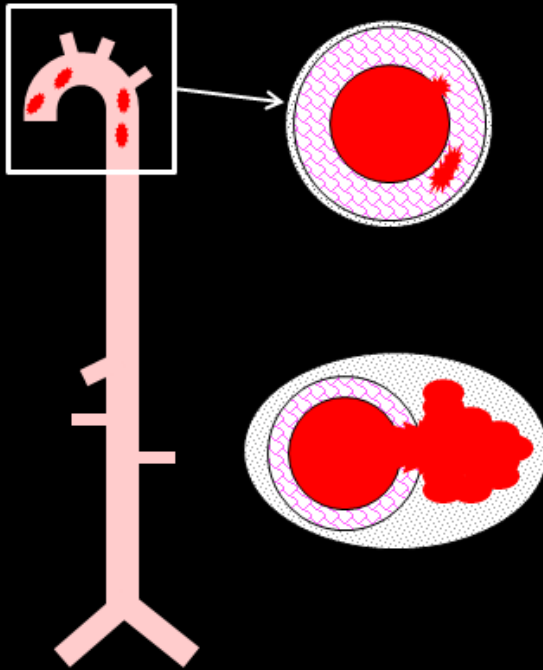


Angiotensin II infusion

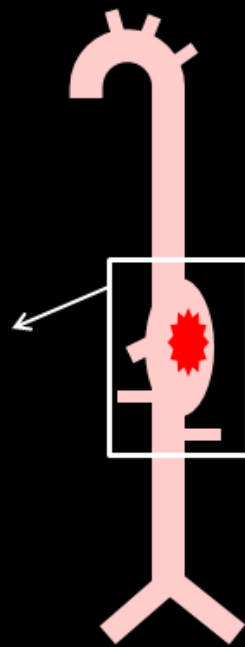
+ SMCTBR11 deletion



Exacerbated Thoracic  
Aortopathy

Unchanged diameter  
Intramural hematoma  
Adventitial thickening

+ Anti-TGF- $\beta$  antibody



Exacerbated Abdominal  
Aortopathy

Enlarged external diameter  
Adventitial thrombus  
Adventitial thickening  
Macrophage accumulation