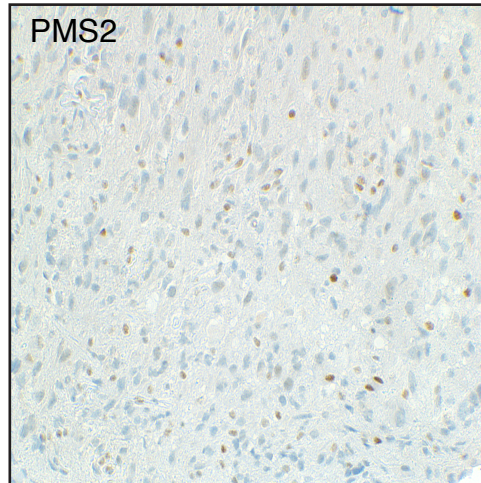
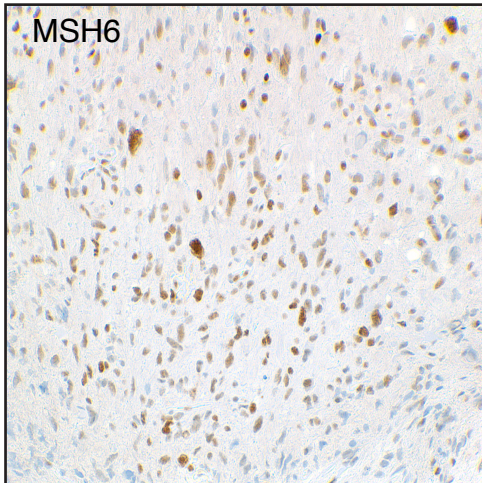
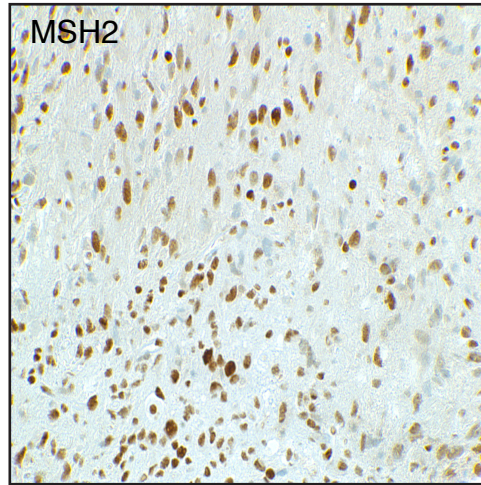
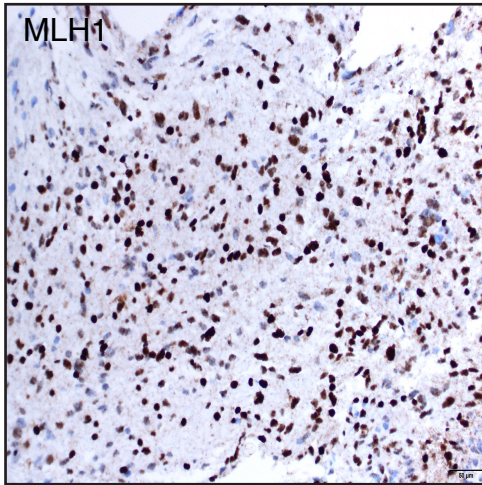


**Supplementary Figure S3.** Immunohistochemical staining for the MMR panel (MLH1, MSH2, MSH6, PMS2) in the HGG11 primary tumor.



200X