

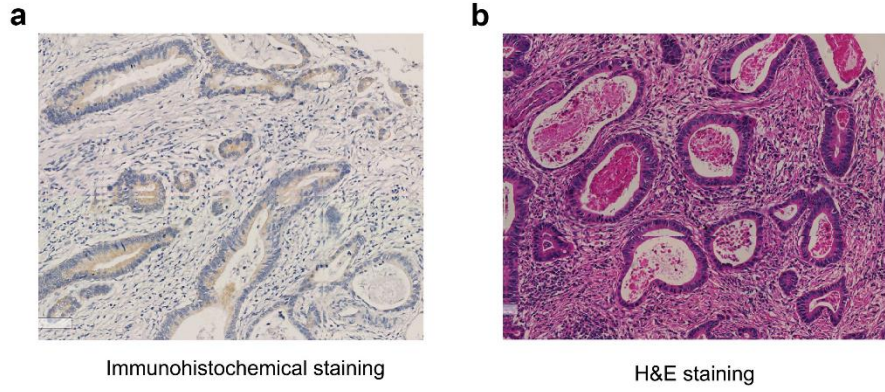Figure S1. Immunohistochemical staining and corresponding H&E staining pictures

(a) Immunohistochemical staining . (b)H&E staining

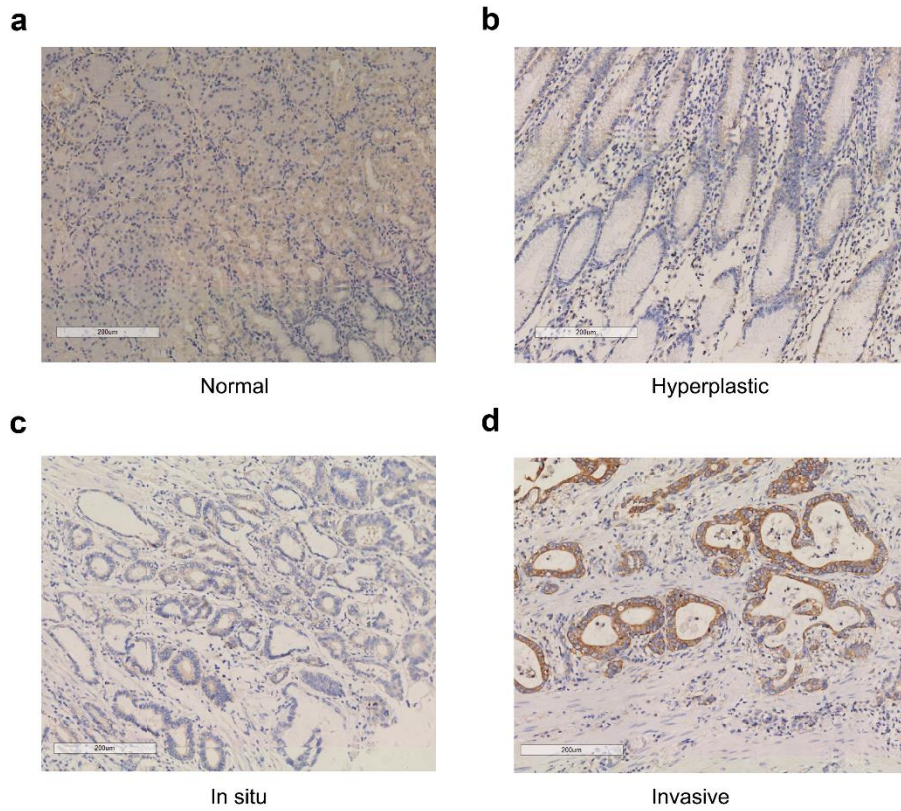


Figure S2. The expression of tetranectin among different tissue components of the same patient. (a) Normal part. (b) Hyperplastic part. (c) In situ part. (d) Invasive part.