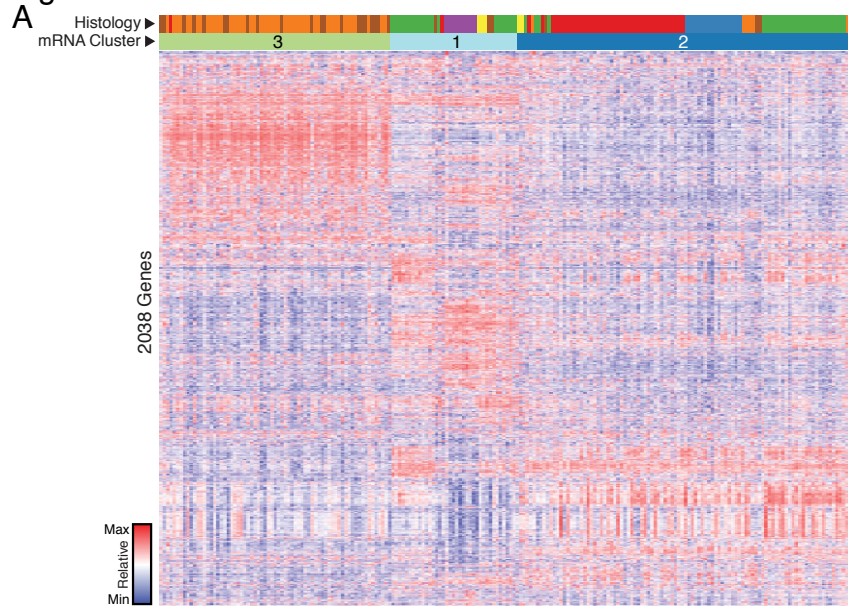


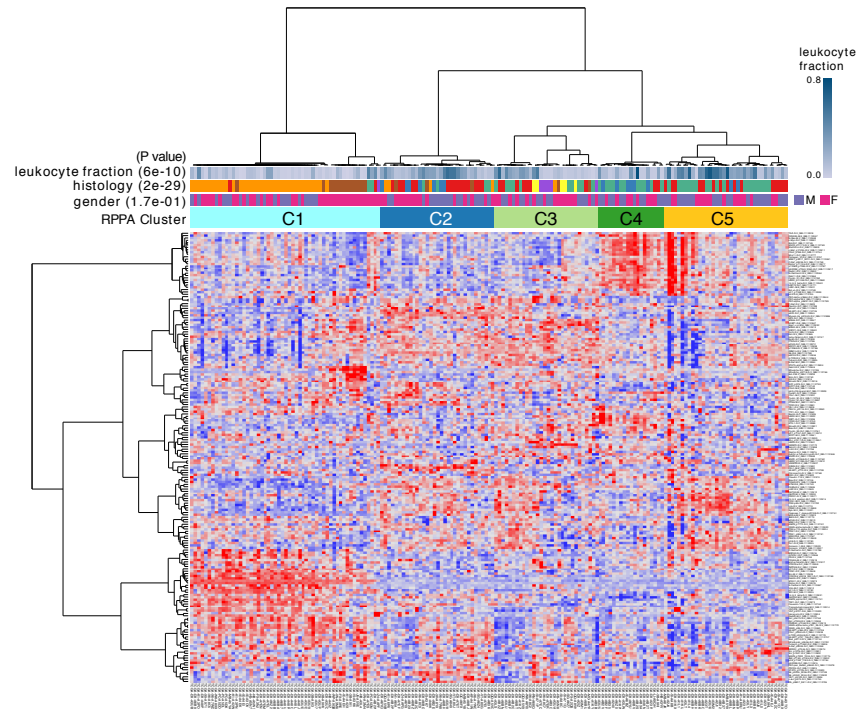
Figure S4



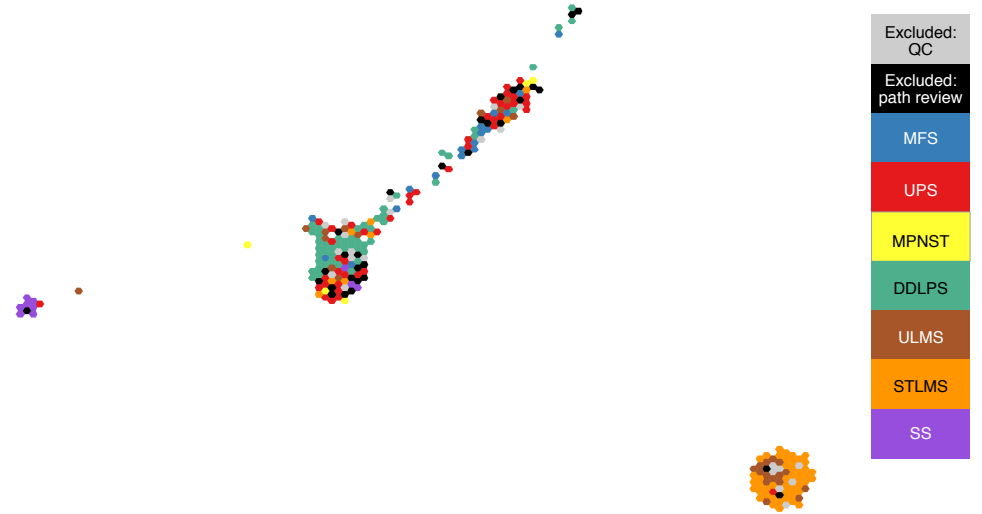
Histology

- Myxofibrosarcoma
- Undifferentiated Pleomorphic Sarcoma
- Malignant Peripheral Nerve Sheath Tumor
- Dedifferentiated Liposarcoma
- Gynecologic Leiomyosarcoma
- Soft Tissue Leiomyosarcoma
- Synovial Sarcoma

C



B



D

