

Supplementary Online Content

Lee SY, Cheng JL, Gehrs KM, et al. Choroidal features of acute macular neuroretinopathy via optical coherence tomography angiography and correlation with serial multimodal imaging. *JAMA Ophthalmol*. Published online September 28, 2017. doi:10.1001/jamaophthalmol.2017.3790

eFigure 1. Automated Quantification of Choroidal Flow Regional Context

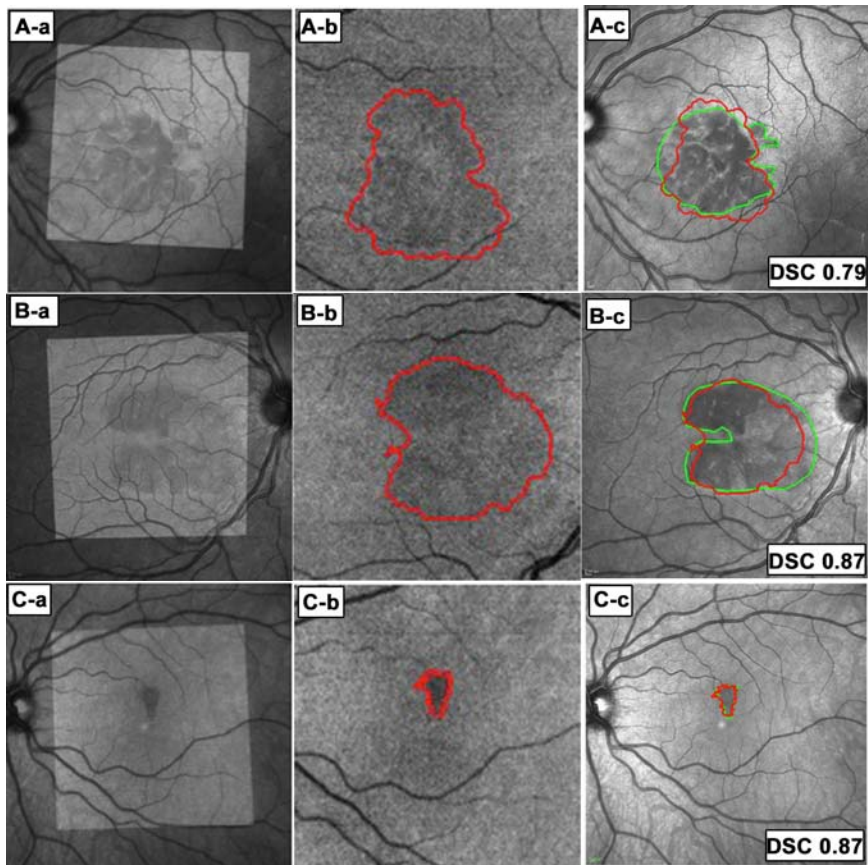
eFigure 2. Patient 1, Left Eye.

eFigure 3. Patient 2, Both Eyes.

eFigure 4. Patient 6, Left Eye.

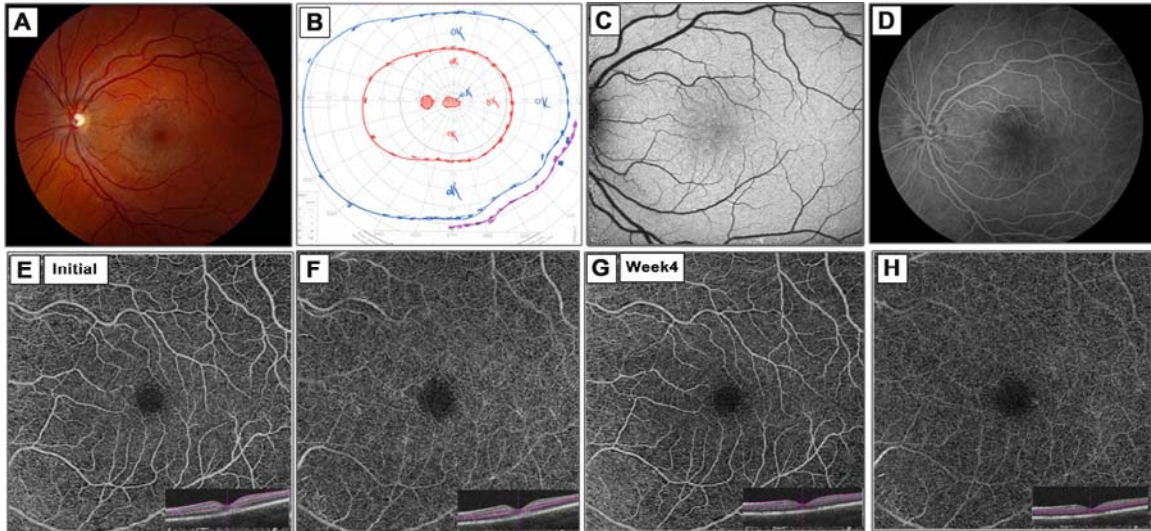
This supplementary material has been provided by the authors to give readers additional information about their work.

eFigure 1. Automated quantification of choroidal flow regional context



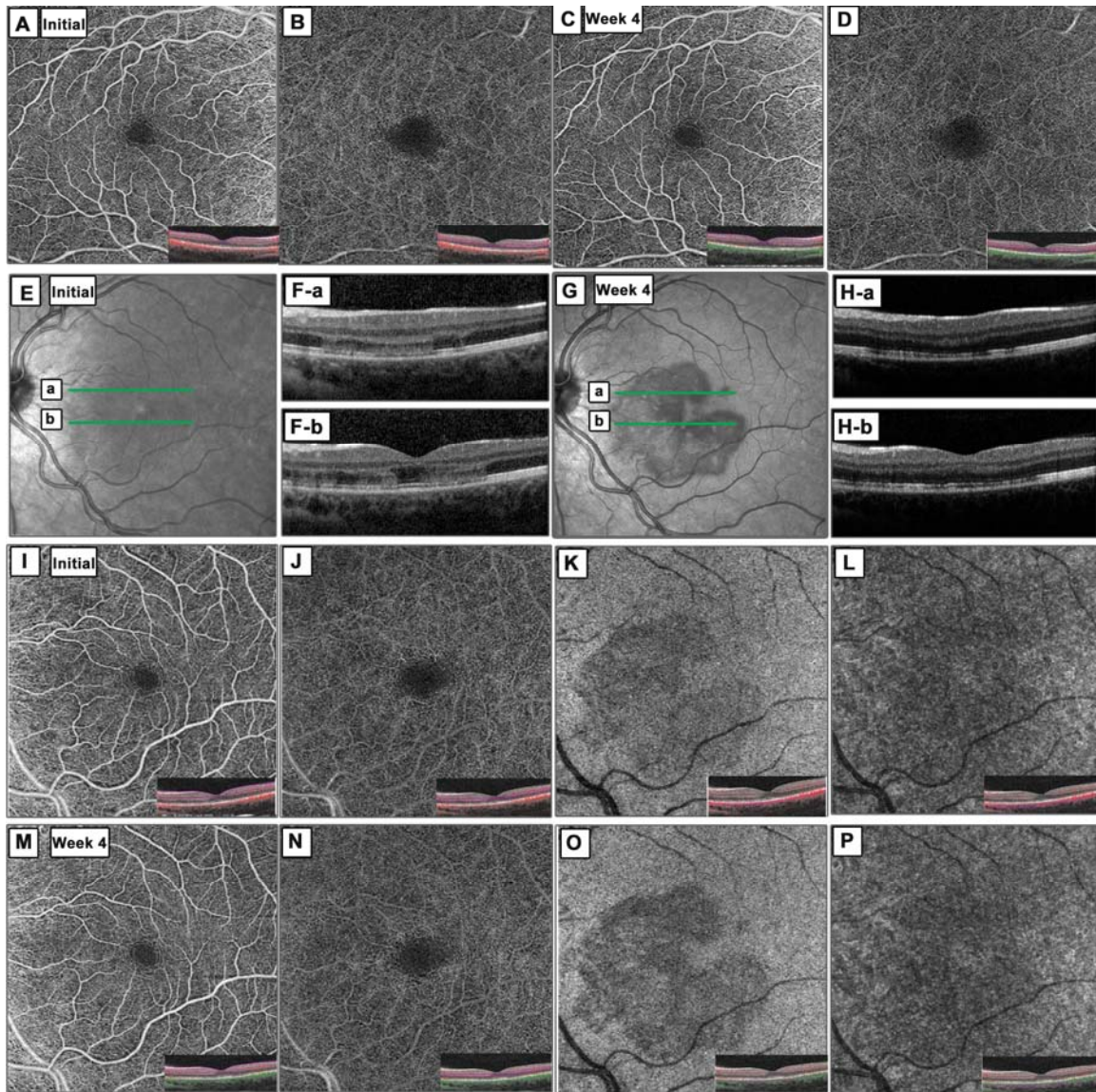
Patients 1 (A), 2 (B), and 6 (C). Registration of optical coherence tomography angiography (OCTA) scans with near-infrared (NIR) images (first column). Areas of OCTA choroidal flow loss, outlined in red (second column). OCTA areas (red) overlaid onto the NIR image, with hypointense NIR areas outlined in green (third column). Correspondence of OCTA-NIR, shown as the Dice Similarity Coefficient (DSC).

eFigure 2. Patient 1, left eye.



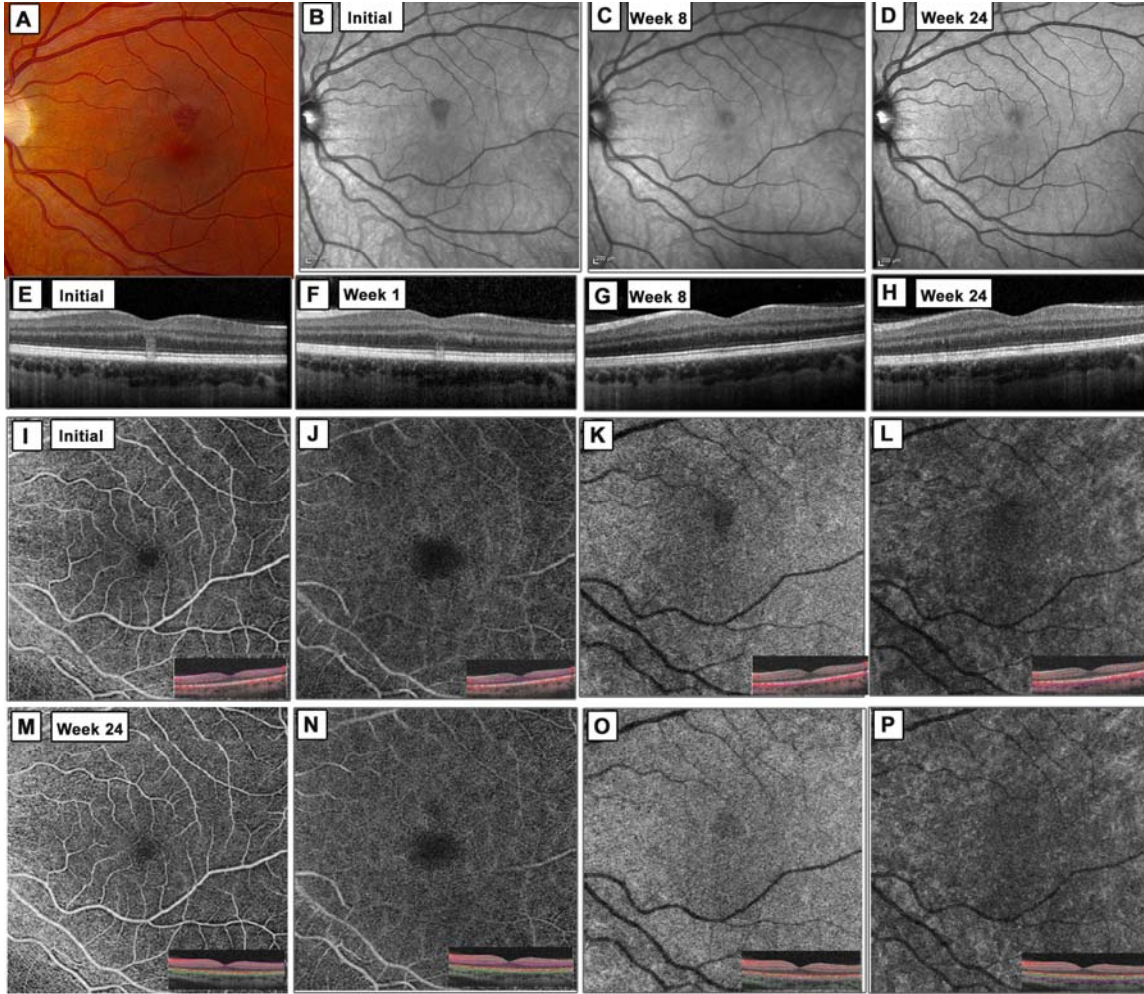
Fundus photo (A). Goldmann visual field (B). Fundus autofluorescence (C). Late frame fluorescein angiography (D). Optical coherence tomography angiography of the superficial (E, G) and deep retinal capillary plexus (F, H).

eFigure 3. Patient 2, both eyes.



Optical coherence tomography angiography of the superficial (A, C; I, M) and deep retinal capillary plexus (B, D; J, N) of both eyes; choriocapillaris (O, S) and outer choroid (P, T) of the left eye. Near infrared image at presentation (E) and 4 weeks (G) of the left eye. Spectral domain optical coherence tomography (OCT) line scans (F-a/b; H-a/b) of the left eye.

eFigure 4. Patient 6, left eye.



Fundus photo (A). Near infrared imaging (B-D). Spectral domain optical coherence tomography on presentation (E) and follow-up (F, G and H). Optical coherence tomography angiography of the superficial (I, M), deep retinal capillary plexus (J, N), choriocapillaris (K, O) and outer choroid (L, P), at presentation and 24 weeks.