

Spinal cord

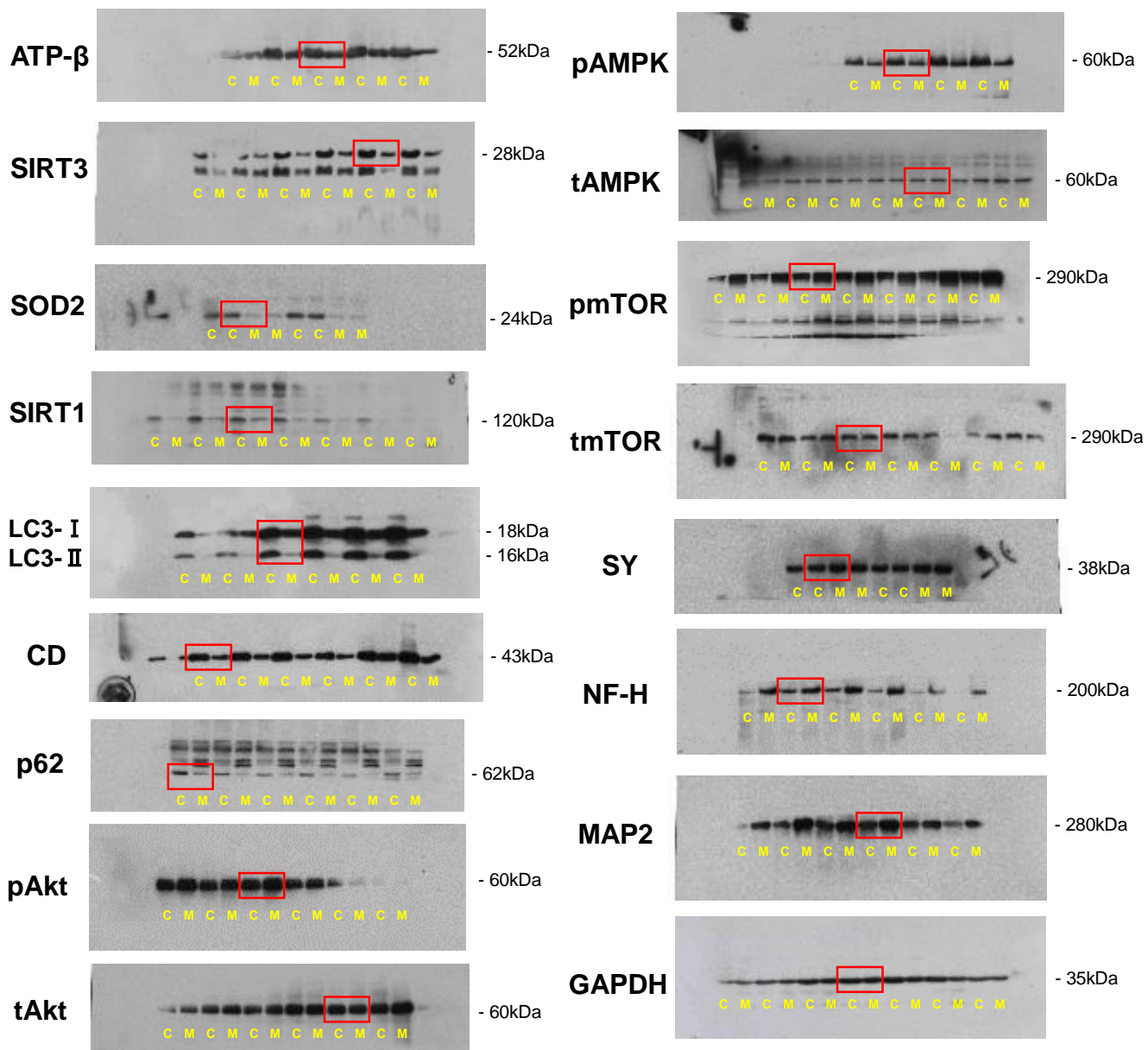


Fig. S8.2