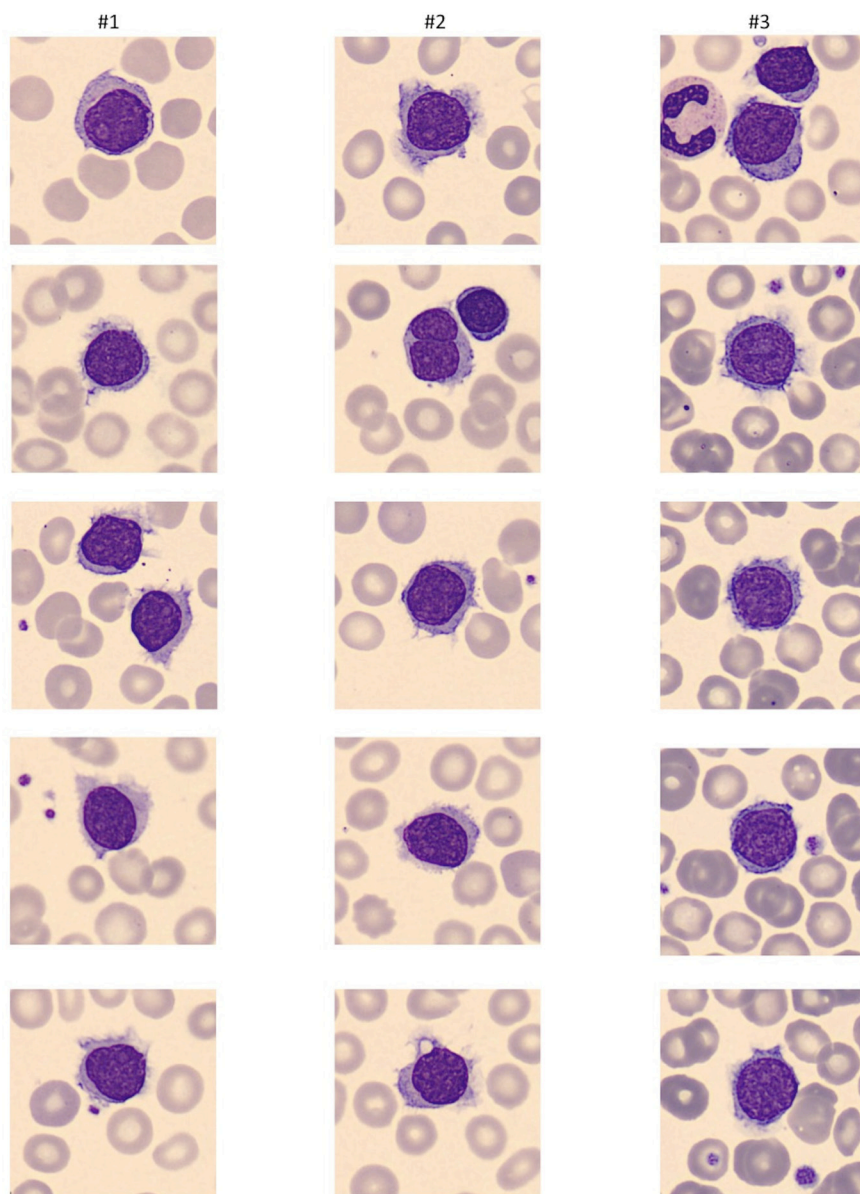
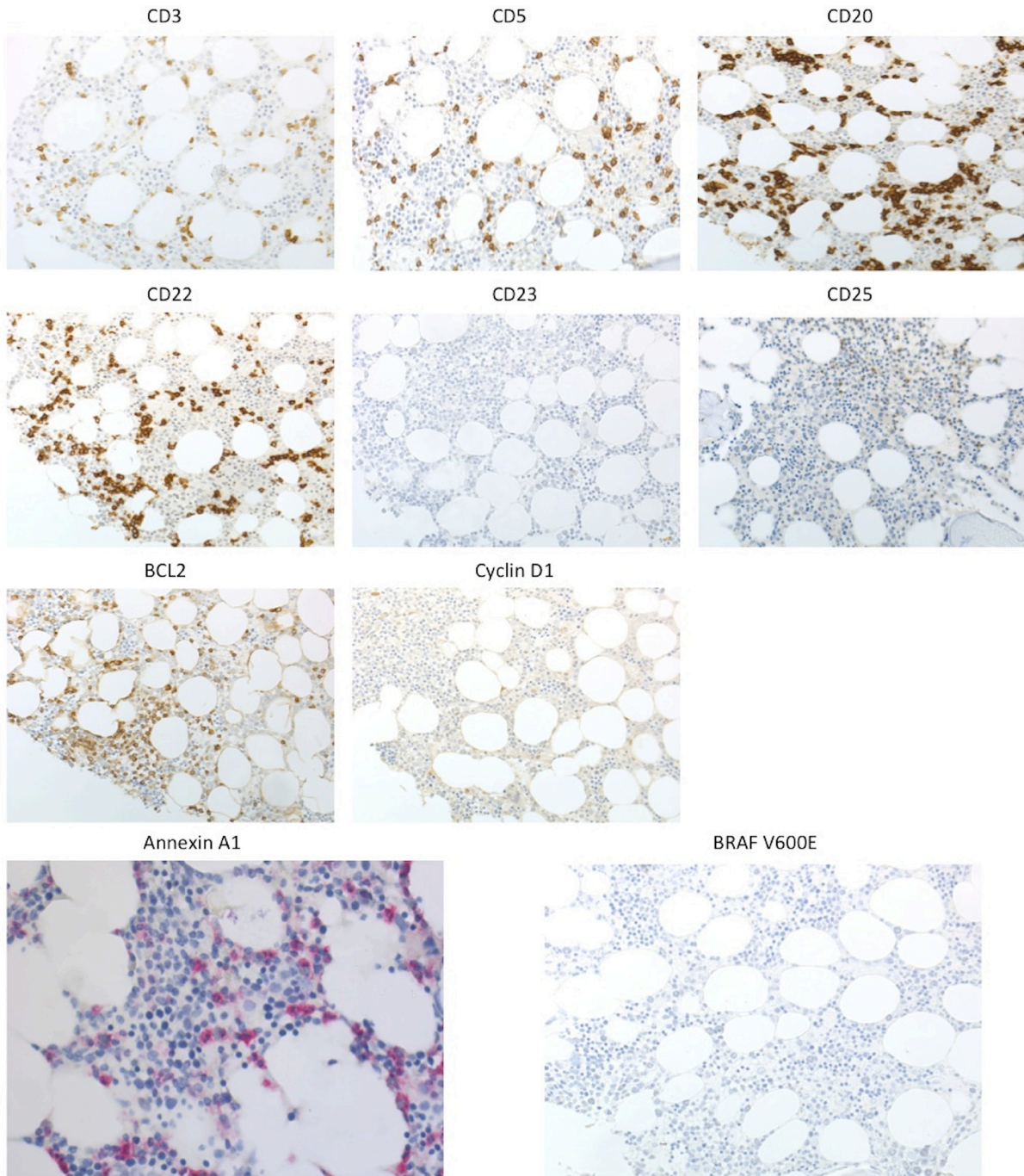


Bendamustine plus rituximab is an effective first-line treatment in hairy cell leukemia variant: a report of three cases

SUPPLEMENTARY MATERIALS



Supplementary Figure 1: Peripheral blood films from HCL-V. Peripheral blood films from the three patients revealed abnormal, medium to large size lymphocytes with abundant and irregular cytoplasm and fine circumferential projections, round eccentric nuclei and a prominent nucleolus. In patient #2 we also observed rare bi-nucleated cells.



Supplementary Figure 2: Extensive immunohistochemistry from representative case. Neoplastic cells displayed strong positivity for pan-B cell markers (CD20, CD22) and Bcl2, with consistent negativity for CD3, CD5, CD23, CD25, Annexin A1, Cyclin D1 and the BRAF V600E-specific antibody.