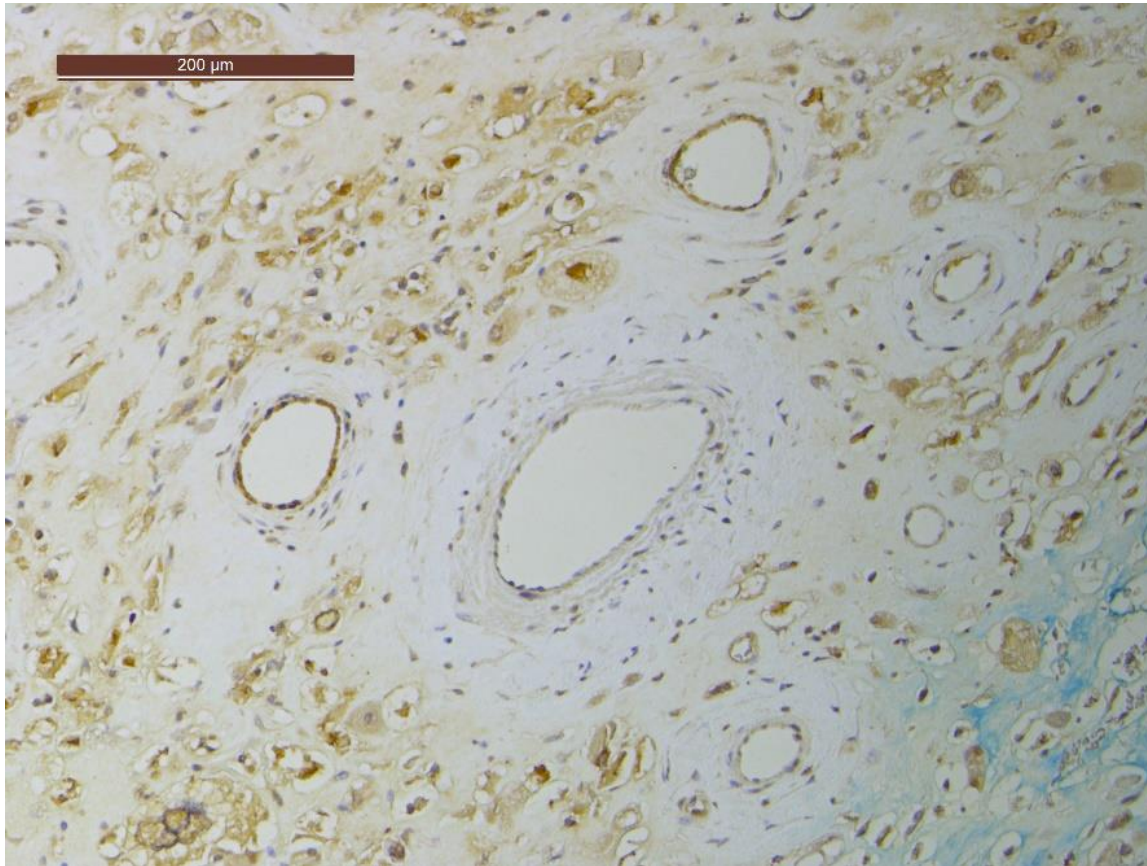
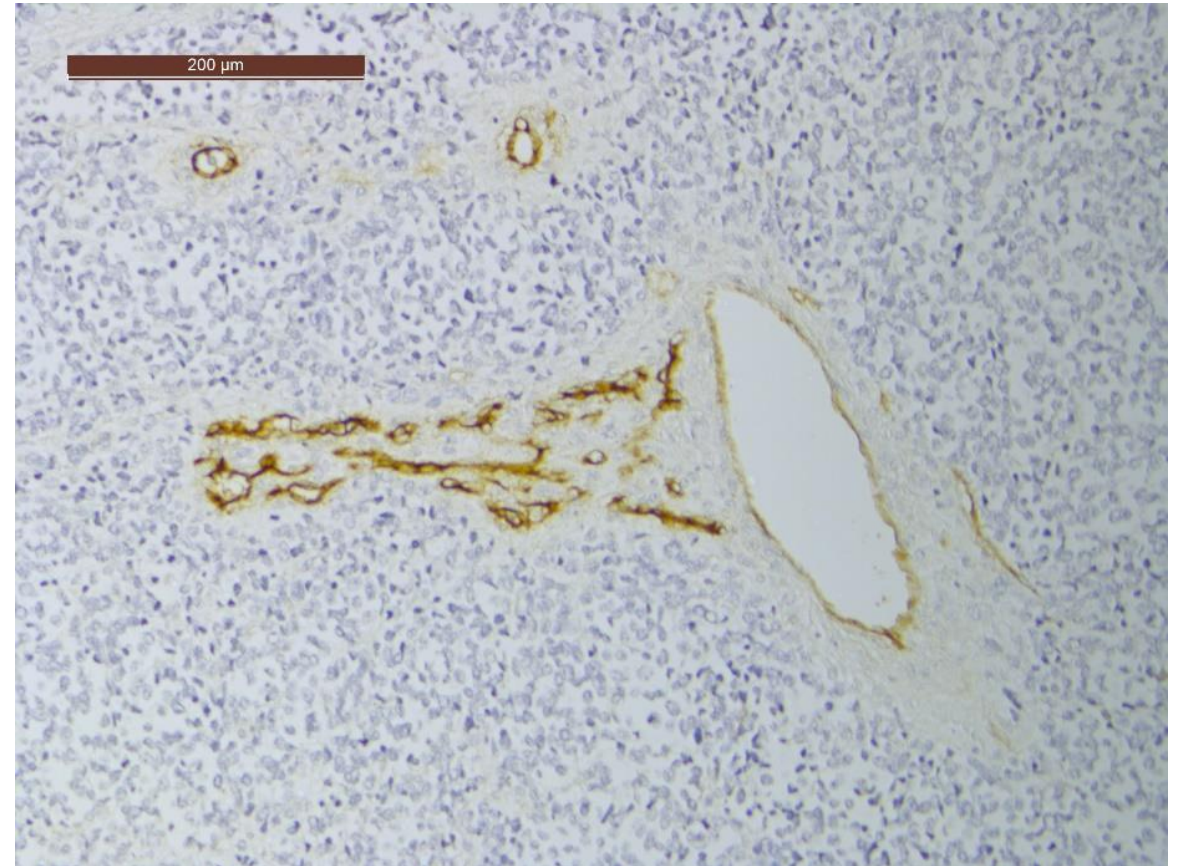


Patient#11 (ERMS)



Patient#12 (ARMS)



Supplemental Fig. 1: Immunostaining of CD105 for ERMS and ARMS. Magnification x 200.

The Pictures show that CD105 is specifically associated with new small developing vessels compared to large vessels in rhabdomyosarcoma.