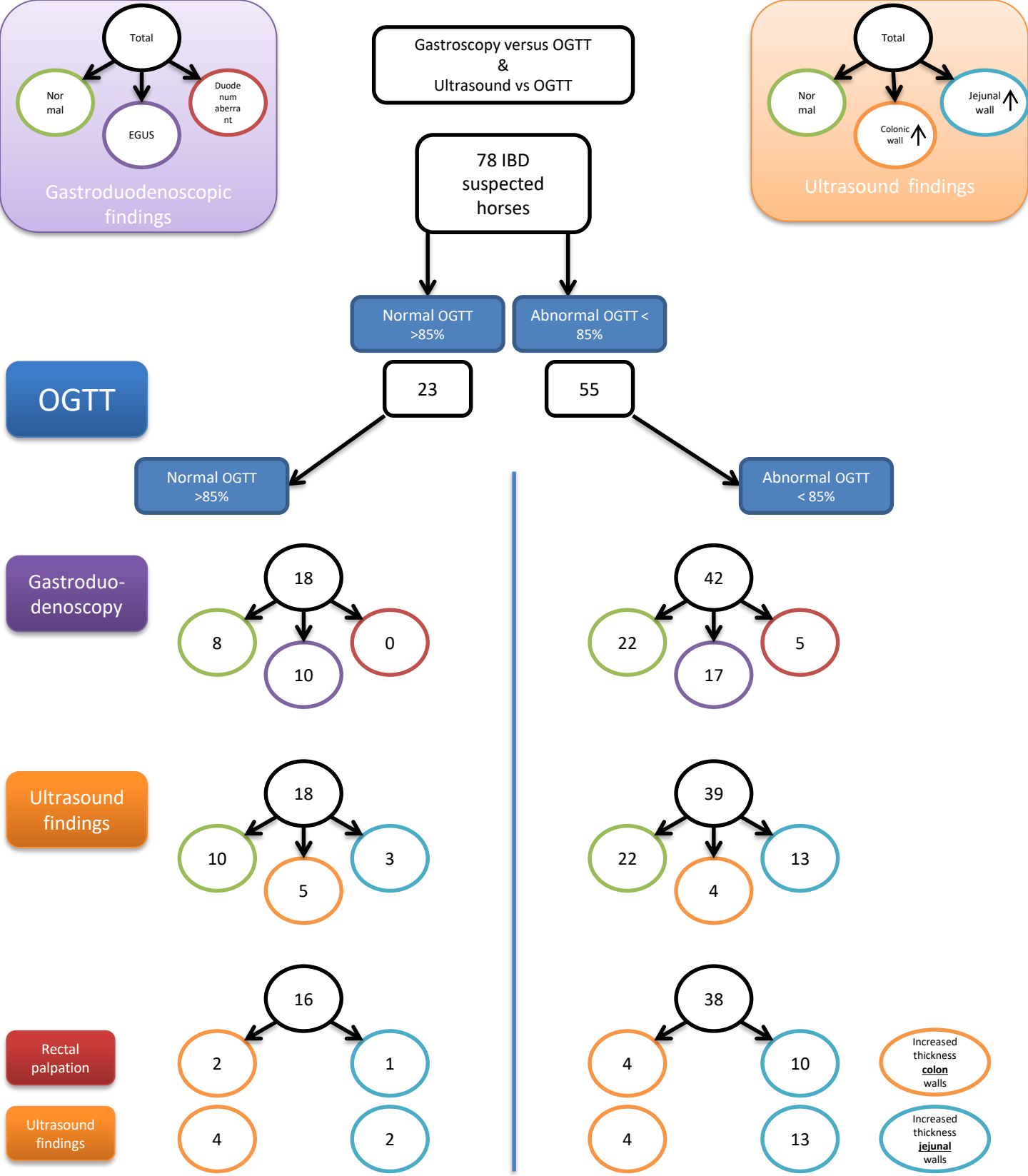


**Additional figure 2:** Overview of gastroduodenoscopic and transabdominal ultrasound findings within the equine IBD suspected study population, classified by OGTT result (either normal: left panel, or abnormal: right panel). In the left and right upper corner the colour codes are depicted for classification of respectively gastroduodenoscopy (left upper corner) and ultrasound findings (right upper corner). Finding increased enteric wall thickness by rectal palpation or using transabdominal ultrasound are both compared in the bottom panel. Colour codes for the different enteric walls are depicted in the right lower corner.