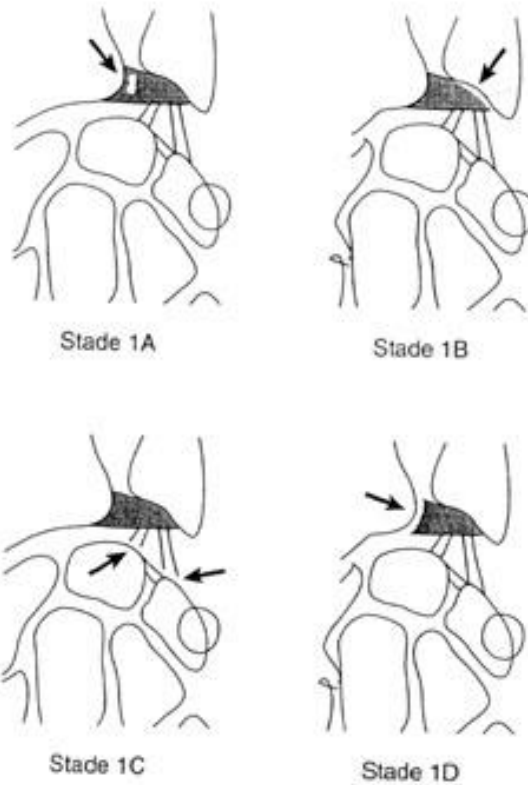


1 Additional file 4. Palmer classification for TFCC acute traumatic tears

- 2 • A: central perforation
- 3 • B: Ulnar avulsion with or without distal ulnar fracture (may involve the proximal
- 4 or distal lamina (foveal and styloid attachment, respectively) or both)
- 5 • C: Distal avulsion
- 6 • D: Radial avulsion with or without sigmoid notch fracture



7