

Treatment of ulcerative colitis using andrographolide

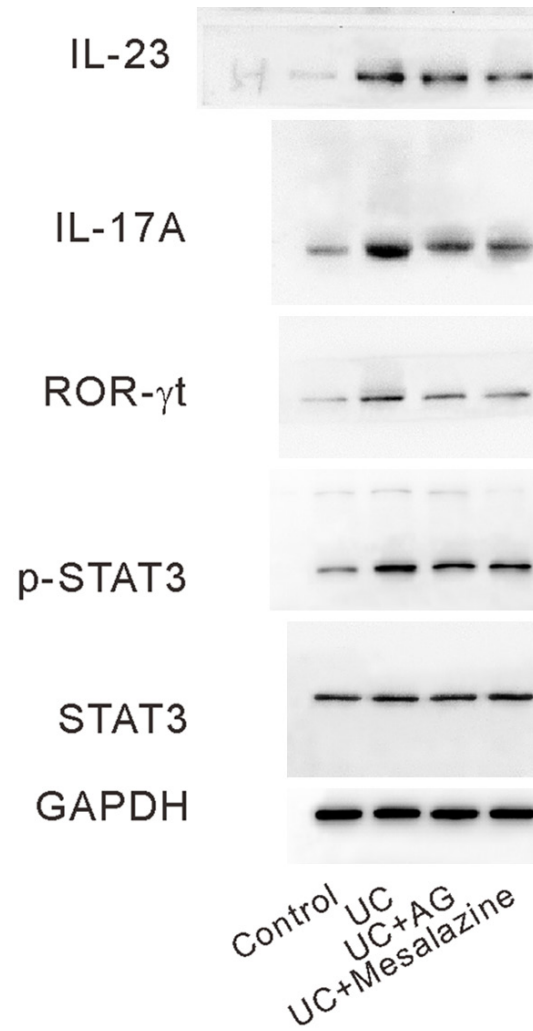


Figure S1. Original western images for Figure 3D.

Treatment of ulcerative colitis using andrographolide

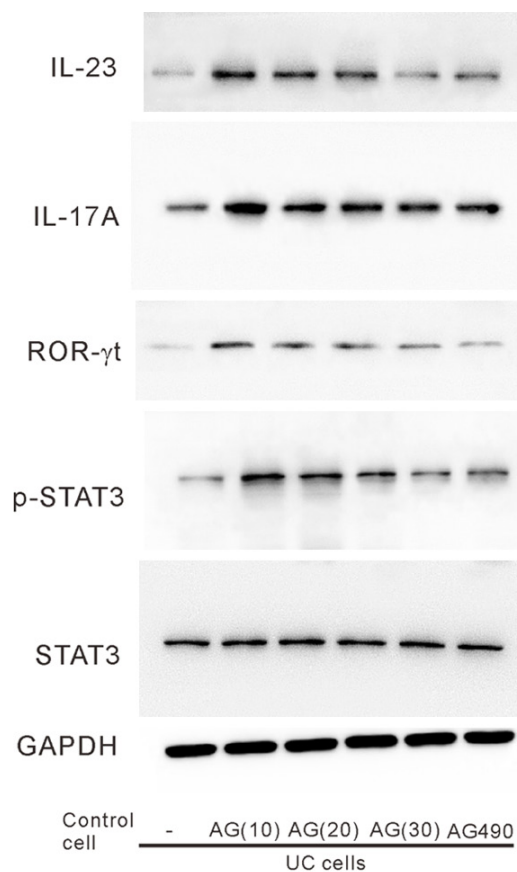


Figure S2. Original western images for Figure 4C.

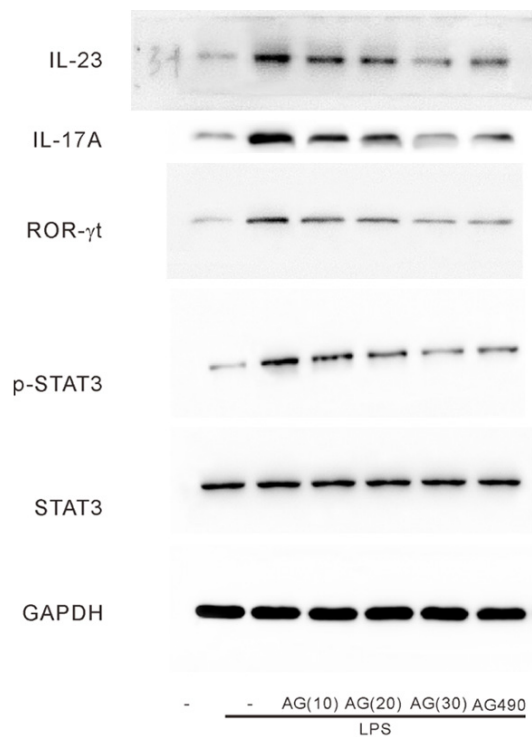


Figure S3. Original western images for Figure 5C.