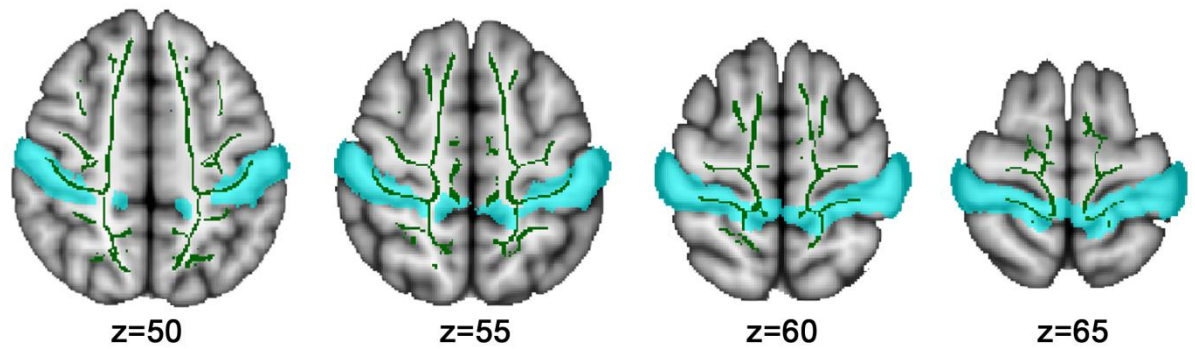
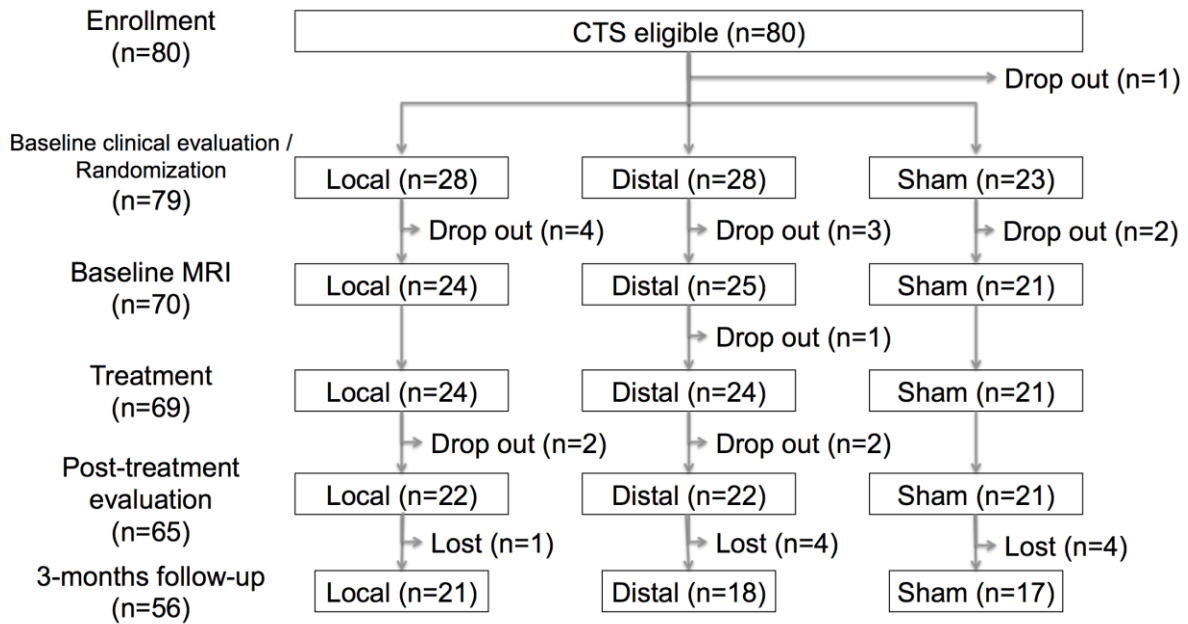


Supplementary Figure 1



Dilated mask of the postcentral gyrus taken from the Harvard-Oxford atlas and intersected with the white matter skeleton was used for DTI analysis of S1-adjacent white matter microstructure.

Supplementary Figure 2



Flowchart of subjects evaluated and dropout/lost at each stage of our randomized neuroimaging longitudinal trial