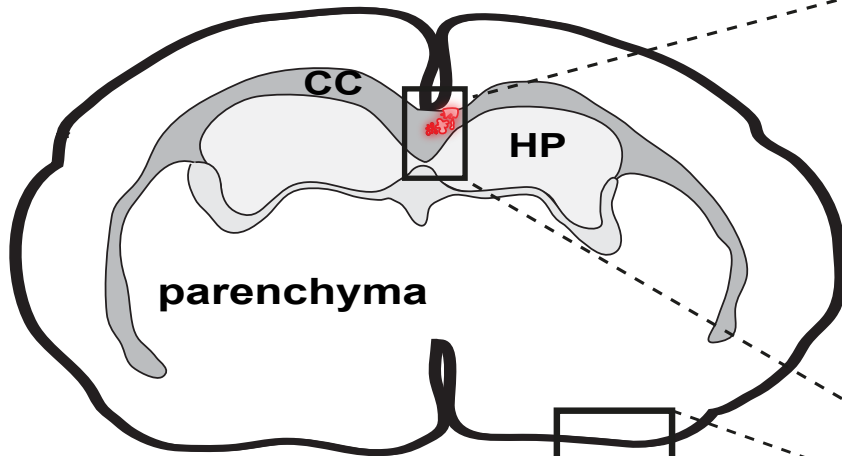


contralateral

ipsilateral

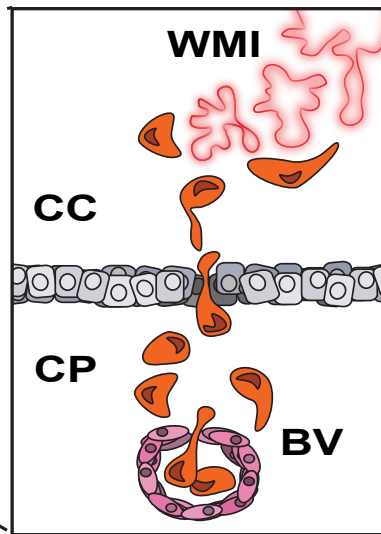


parenchyma

CC

HP

meninges



WMI

CC

CP

BV

