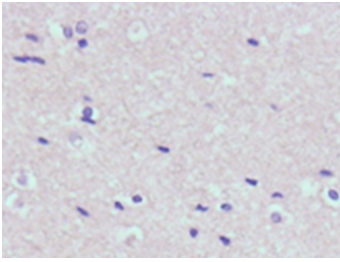
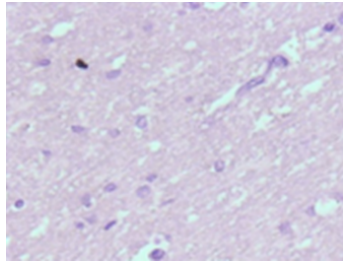


Supplement Figure 1

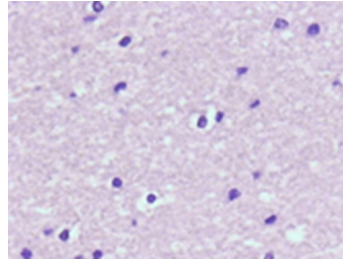
Frontal lobe white matter



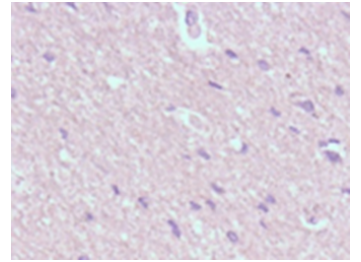
Parietal lobe white matter



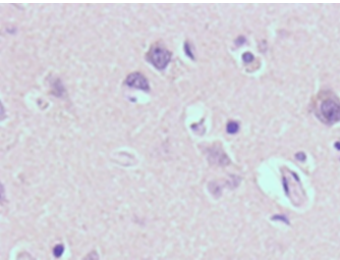
Temporal lobe white matter



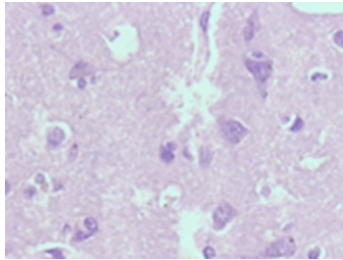
Occipital lobe white matter



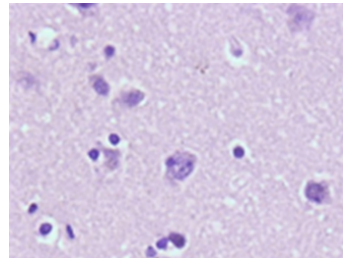
Frontal lobe gray matter



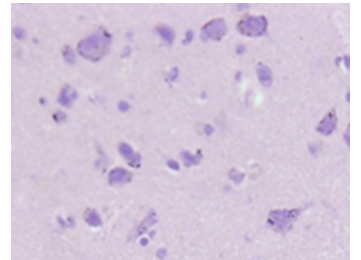
Parietal lobe gray matter



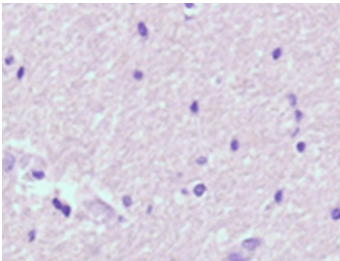
Temporal lobe gray matter



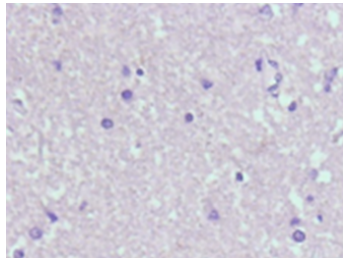
Occipital lobe gray matter



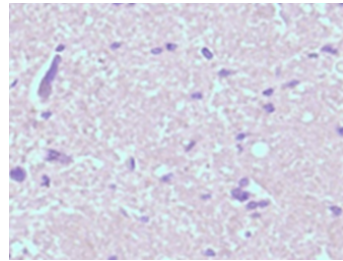
Hippocampus white matter



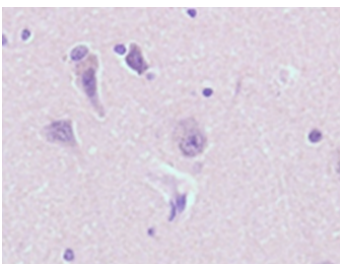
Cerebellum white matter



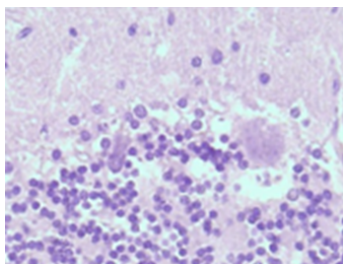
Basal ganglion white matter



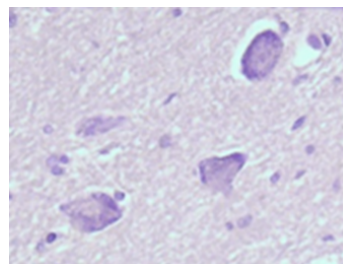
Hippocampus gray matter



Cerebellum gray matter



Basal ganglion gray matter



Hippocampus CA neurons

