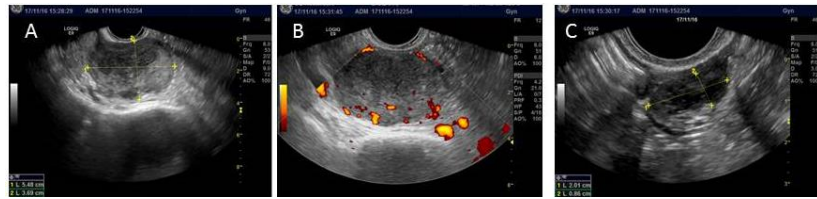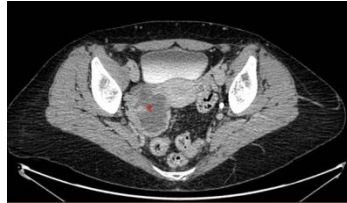


**November 2016**

Uterine prolapse



**TV-US**  
solid hypoechoic pelvic mass



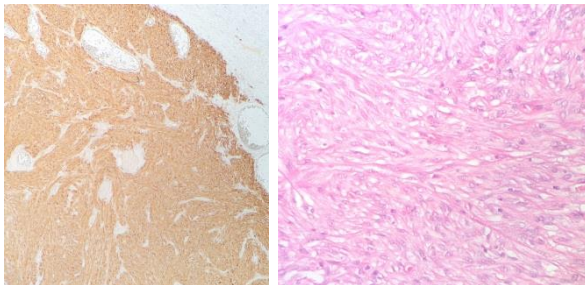
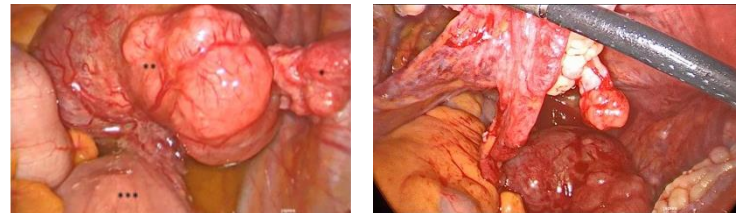
**CT-scan**

expansive right adnexal lesion, with lobulated margins and heterogeneous enhancement

**January 2017**

Surgery

ileal loop resection, hysterectomy,  
bilateral salpingo-oophorectomy,  
pelvic peritonectomy, peritoneal washing



**Diagnosis**

GIST (spindle cell type) of small bowel with  
bilateral ovarian metastases  
KIT exon 11 mutation (p.M552\_W557)

**February 2017**  
Adjuvant imatinib

Alive, no recurrence