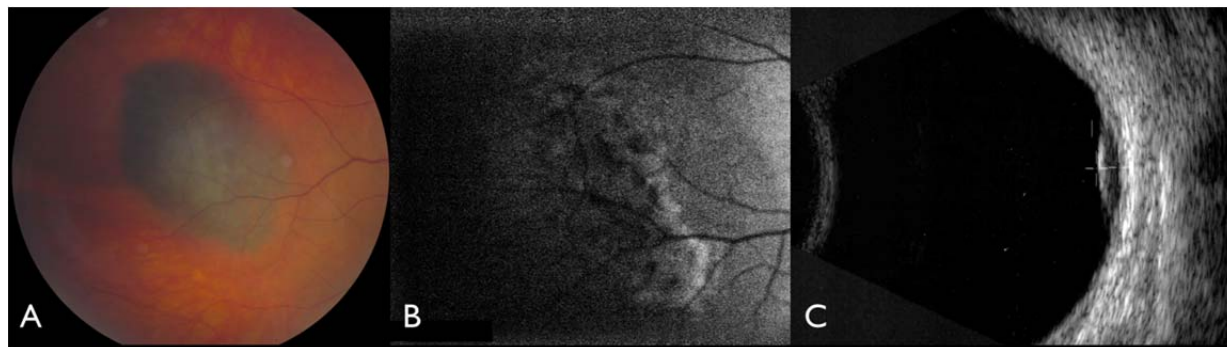


## Supplementary Online Content

Dalvin LA, Shields CL, Pulido JS, Sioufi K, Cohen V, Shields JA. Uveal melanoma in the setting of myotonic dystrophy: a report of 6 cases. *JAMA Ophthalmol*. Published online March 29, 2018. doi:10.1001/jamaophthalmol.2018.0554

### **eFigure.** Case 2.

This supplementary material has been provided by the authors to give readers additional information about their work.

**eFigure 1: Case 2****eFigure 1: Case 2**

(A) A middle-aged man with myotonic dystrophy was found to have a pigmented choroidal melanoma temporal to the macula in the right eye, with subtle overlying orange pigment, (B) confirmed as hyperautofluorescent and (C) mass with acoustic hollowness on ultrasonography.