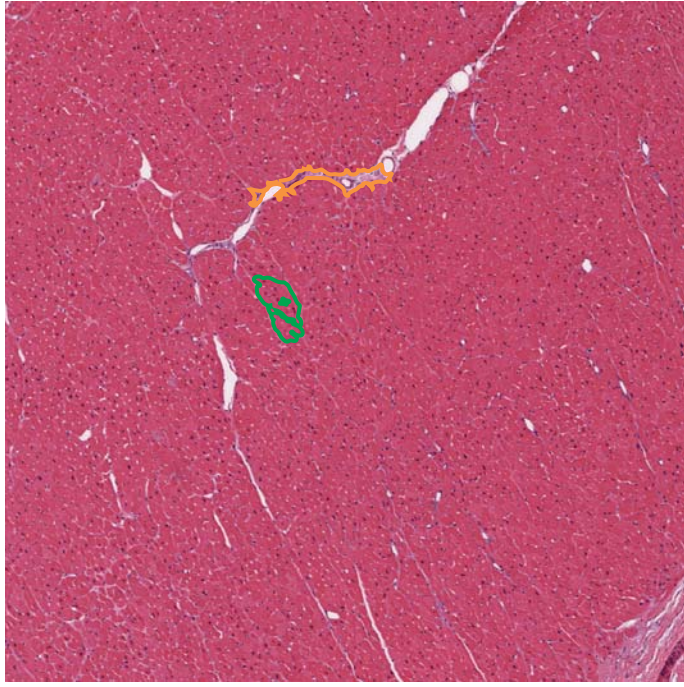


Figure S1

A Non-Failing



B Failing

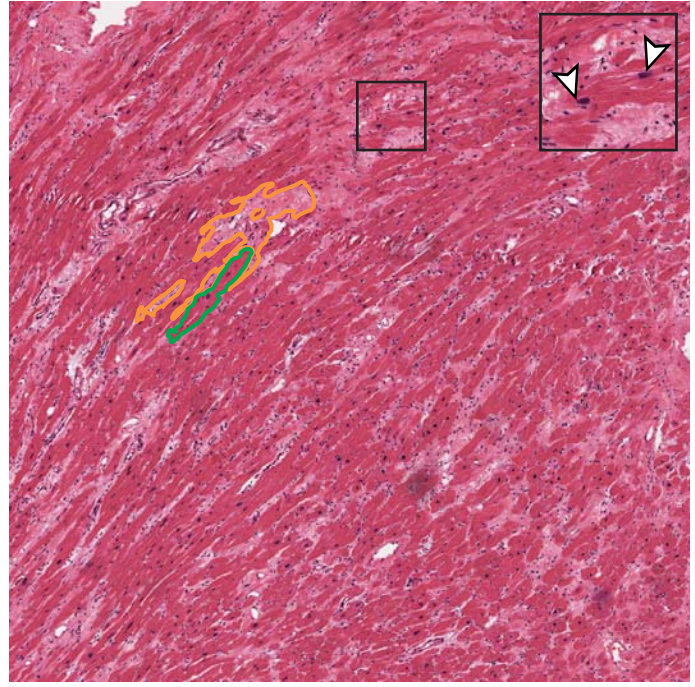


Figure S 1. Example cardiac histopathology.

(a) Normal cardiac tissue shows regular, dense arrays of cardiomyocytes (green) with stroma limited to perivascular regions (orange). (b) Patients with heart failure have an expansion of the cellular and acellular stromal tissue (orange) that disrupts cardiomyocyte arrays (green). Other features seen in heart failure include large myocytes with enlarged, hyperchromatic, “boxcar” nuclei (arrowhead, enlarged 200 μ m region shown in the inset). Images are 5x magnification and the scale bar is 1mm.