

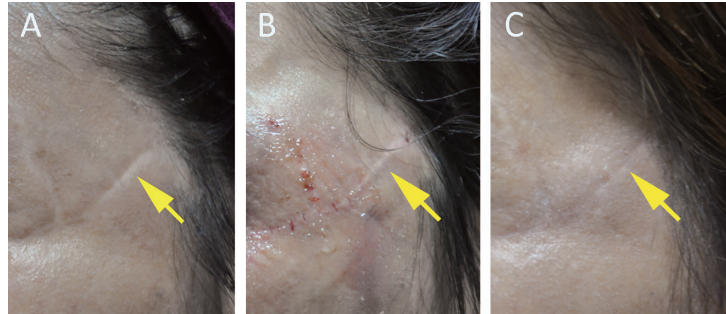
Supplementary Online Content

Gu Z, Li Y, Li H. Use of condensed nanofat combined with fat grafts to treat atrophic scars. *JAMA Facial Plast Surg*. Published online September 21, 2017. doi:10.1001/jamafacial.2017.1329

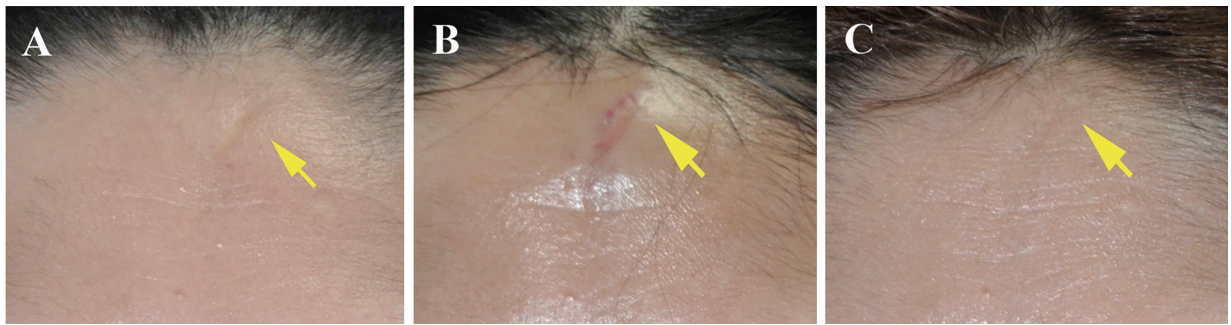eFigure 1. A linear atrophic scar on the left temporal region preoperatively (A), immediately postoperatively (B), and 1 year postoperatively (C)

eFigure 2. A linear atrophic scar on the forehead preoperatively (A), immediately postoperatively (B), and 1 year postoperatively (C)

This supplementary material has been provided by the authors to give readers additional information about their work.



eFigure 1. A linear atrophic scar on the left temporal region preoperatively (A), immediately postoperatively (B), and 1 year postoperatively (C)



eFigure 2. A linear atrophic scar on the forehead preoperatively (A), immediately postoperatively (B), and 1 year postoperatively (C)