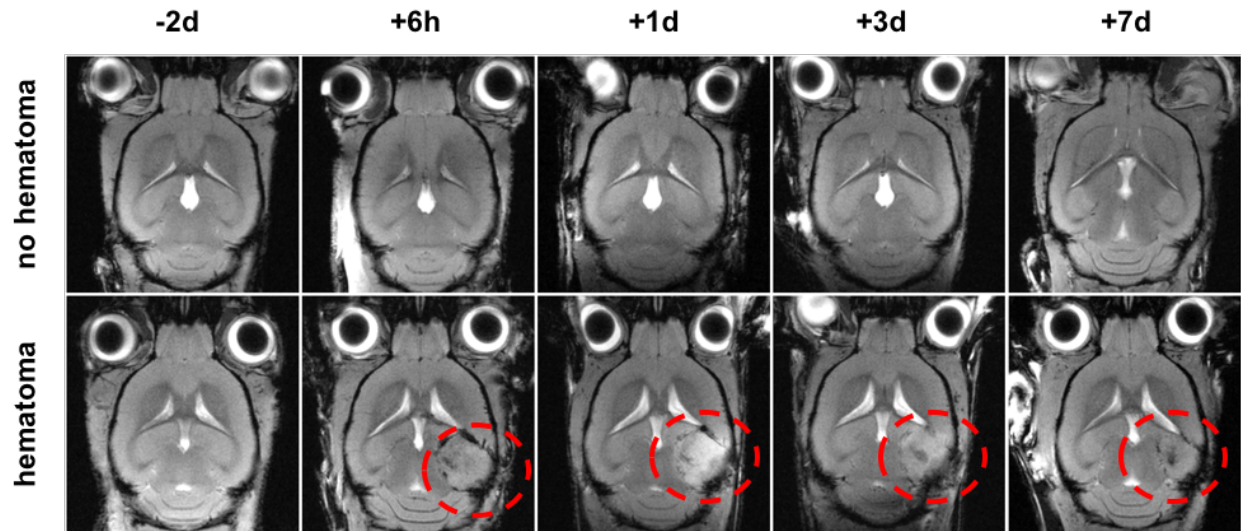


Mettang et al.

Supplementary Figure 3



Longitudinal MRI analysis after TBI.

Hematoma formation shown in representative coronal T1*-weighted MRI images at indicated time points post TBI. The red dashed line indicates the trauma impact region comprising hematoma and edema.