

Effect of Angiostatin on Liver Metastasis of Pancreatic Cancer in Hamsters

Ken Yanagi, Masahiko Onda and Eiji Uchida

First Department of Surgery, Nippon Medical School, 1-1-5 Sendagi, Bunkyo-ku, Tokyo 113-8603

The liver is the most common site of metastasis in pancreatic cancer, and there are no promising strategies to treat it. Angiostatin, a kringle-containing fragment of plasminogen, is a potent inhibitor of angiogenesis. The effect of angiostatin on liver metastasis in pancreatic cancer was investigated by using our established hamster model of liver metastasis. Pancreatic cancer cells (PGHAM-1, 1×10^6) derived from N-nitrosobis(2-oxopropyl)amine (BOP)-induced pancreatic tumor in Syrian golden hamsters were transplanted into the spleen of female hamsters, and the animals were subcutaneously injected with angiostatin and saline. Subsequently, the macroscopic appearance of liver surface metastases was evaluated. In addition, histological sections of the liver metastases were analyzed for neovascularization, proliferation, and apoptosis on the basis of von Willebrand factor, argyrophilic nucleolar organizer region (Ag-NOR), and TdT-mediated dUTP-biotin nick end labeling (TUNEL) staining, respectively. The results showed significant tumor growth retardation and inhibition of angiogenesis in metastatic liver tumors in response to treatment with angiostatin. Moreover, the metastases remained in a nearly dormant state due to a balance between apoptosis and proliferation of the tumor, with no detectable side effects. This is the first experimental trial of angiostatin on pancreatic cancer and liver metastasis. The results suggest that angiostatin therapy could be effective against liver metastases of pancreatic cancer.

Key words: Angiostatin — Pancreatic cancer — Liver metastasis — Angiogenesis — Hamster

Pancreatic cancer is the fifth largest cause of cancer death,^{1,2)} and its incidence in the Western world has been increasing over the last four decades, though the reasons for this are unknown.³⁾ The prognosis after operation remains poor, in spite of the development of imaging diagnosis, surgical techniques, and systemic chemotherapy. Because of liver metastasis, peritoneal dissemination,^{4,5)} and local recurrence in the early stage,⁶⁾ in almost all cases, macroscopically radical operation fails to improve the prognosis of pancreatic cancer. The liver is the most common site of metastasis in pancreatic cancer,⁷⁾ and liver micrometastases may be present in pancreatic cancer patients at operation, despite the absence of macroscopic findings.⁸⁾ Thus, inhibition of liver metastasis is important to improving the prognosis of this disease.

There have been several reports on experimental models of liver metastasis in nude mice.⁹⁾ However, there may be differences in the mechanism of liver metastasis in humans and nude mice, which are not immunocompetent. On the other hand, since Syrian golden hamsters develop ductal adenocarcinoma of the pancreas in response to N-nitrosobis(2-oxopropyl)amine (BOP) that resembles human pancreatic cancer morphologically, biologically, and immunologically,^{10,11)} hamster pancreatic cancer might provide a good animal model of liver metastasis of human pancreatic cancer.

Recently, O'Reilly *et al.* described an internal peptide fragment of plasminogen, called angiostatin, found in the

serum and urine of mice with Lewis lung carcinoma,^{12,13)} that has potent antiangiogenic properties. Angiostatin, comprising kringles 1–4 of human plasminogen, inhibits angiogenesis as judged from chick chorioallantoic membrane (CAM) assay, and it has also been found to be a specific inhibitor of endothelial cell proliferation *in vitro*.¹³⁾ When administered systemically *in vivo*, angiostatin potently inhibits the growth of human and murine primary carcinomas and lung metastasis in mice by specifically inhibiting endothelial proliferation.^{14,15)} Almost complete regression of subcutaneously implanted prostate carcinoma in mice in response to angiostatin has been demonstrated.¹⁴⁾ This led to a new concept of antitumor strategy, called “tumor dormancy therapy.”¹⁴⁾

However, the effect of angiostatin on pancreatic cancer and liver metastasis has never been investigated. Therefore, in this study, we examined the antiangiogenic effect of angiostatin on neovascularization and the tumor growth of liver metastases in experimental pancreatic cancer in the hamster.

MATERIALS AND METHODS

Animals Female 3- to 5-week-old Syrian golden hamsters were obtained from the Shizuoka Experimental Animal Center (Shizuoka). They were kept under standard laboratory conditions (temperature, $22 \pm 3^\circ\text{C}$; relative humidity, $40 \pm 5\%$; light/dark cycle, 12 h/12 h) and given a standard diet (MF-1, Oriental Yeast Co., Ltd., Tokyo) and water *ad libitum*.

E-mail: yanagi/surg1@nms.ac.jp

Hamster pancreatic cancer cell lines BOP was used to induce pancreatic cancer in hamsters by the method we previously reported.^{16,17)} The tumors were minced with scissors and 1 mm cubes were subcutaneously transplanted with a trocar into the interscapular area of untreated 5-week-old hamsters. The recipient hamsters were killed at 6–8 weeks after transplantation, and a portion of the tumor tissue was serially transplanted. After subcutaneous transplantation 8 times, the tumor was extracted under germ-free conditions, minced in 0.05% trypsin and EDTA solution at 37°C for 10 min, and centrifuged (10 min, 4000g). The cells in the pellet were maintained in Dulbecco's modified Eagle's medium (MEM; GIBCO, Grand Island, NY) supplemented with 10% fetal bovine serum (FBS), 100 units/ml penicillin-streptomycin, 100 µg/ml kanamycin, and 100 µg/ml amphotericin B (GIBCO) at 37°C in a 5% CO₂ incubator in plastic culture flasks (Corning, Corning, NY). Cells that had been maintained in culture for 60 passages and had become established as a cell line were named PGHAM-1.

Model of liver metastasis of pancreatic cancer Under adequate anesthesia with diethyl ether, laparotomy was performed on 3-week-old hamsters ($n=25$) and a suspension of PGHAM-1 cells (1×10^6 cells/0.1ml in MEM) was injected into the spleen through a 27G tuberculin needle. Fourteen days after transplantation, the abdominal cavity of all hamsters was opened by upper median incision, and the splenic tumors were removed after ligation of the splenic artery and vein under the same anesthesia. After laparorrhaphy, the treatment group of 10 hamsters was subcutaneously injected with 1.2 mg/kg of affinity-purified human angiostatin (Angiogenesis Research Industries, Inc., Chicago, IL) on the day of the operation and with 0.6 mg/kg/day on the next 6 days. In the control group, 15 hamsters were injected with saline instead of angiostatin. All hamsters were killed 21 days after implantation under anesthesia by the same method. The liver of each hamster was removed, and the number of nodules and the diameter of the largest nodule of liver surface metastases in every animal were measured. To detect the toxicity of angiostatin, liver and kidney function was evaluated by blood biochemistry studies and the body weight of both groups was measured.

Histological and immunohistochemical examination The liver specimens were fixed in 10% formalin and routinely processed, and paraffin-embedded sections were processed for hematoxylin and eosin (H-E) staining and immunohistochemistry. To assess tumor vascularity, paraffin-embedded tissue sections were evaluated with antibody against von Willebrand factor (Factor VIII-related antigen) as follows. Deparaffinized tissue sections (3 µm) were pretreated twice for 5 min in a microwave oven in 10 mM citrate buffer pH 6.0 and incubated with rabbit polyclonal antibody against von Willebrand factor (DAKO, Glostrup,

Denmark) overnight at 4°C. The antibody dilution used to detect the antigen was 1:200. The subsequent steps were carried out with SAB-PO (R) kit (Nichirei, Tokyo) according to the manufacturer's instructions. Sections were counterstained with methyl green, and microvessels were counted under a 200-fold magnification field on areas of metastatic liver tumor with the highest density of vascular staining. A minimum of 3 fields were counted in each animal, and the average microvessel density (MVD) was quantified by converting the number to per 1 mm².

Analysis for tumor cell proliferation and apoptosis To evaluate tumor cell proliferation, the argyrophilic nucleolar organizer region (Ag-NOR) was stained by the method of Ploton *et al.*¹⁸⁾ (modified one-step method) in 3 µm sections of tumor tissue after deparaffinization. The number of black dots in the nucleus was counted in 200 nuclei by the method of Howat *et al.*¹⁹⁾ under 1000-fold magnification, and the mean number per nucleus was quantified as the Ag-NOR score. In the analysis of the Ag-NOR score, we compared the score of the metastatic liver tumors in the treatment group with the score in the control group and evaluated the effect of angiostatin on tumor proliferation.

To detect apoptotic cells, paraffin-embedded sections were pretreated with 5 µg/ml of proteinase K at 37°C for 20 min and processed using an *in situ* apoptosis detection (TdT-mediated dUTP-biotin nick end labeling, TUNEL) kit (Trevigen, Inc., Gaithersburg, MD).²⁰⁾ The subsequent steps were carried out according to the manufacturer's instructions. The apoptotic index was evaluated as the percentage of positive staining cells visualized under a light microscope at 200-fold magnification. A minimum of 5 fields in areas of the liver tumor with the highest density of apoptotic cells were counted in each animal. All microscopic examinations were done independently by three investigators.

Statistical analysis The data were analyzed for significance by using the unpaired *t* test. A *P* value smaller than 5% was considered significant.

RESULTS

Macroscopic appearance of liver metastases All hamsters had liver metastases at the termination. In our previous experiment, the rate of microscopic liver metastasis was 20% on day 14 after splenic transplantation of PGHAM-1 (data not shown), meaning that in this model of liver metastasis, most macroscopic liver metastases were generated between 14 and 21 days after implantation. Based on these findings, hamsters were treated with angiostatin during this period. On day 21 after transplantation, there were several small metastases on the liver surface in the angiostatin group, as opposed to multiple metastases larger than 4 mm in diameter in the saline control group (Fig. 1). The number of liver surface metastases

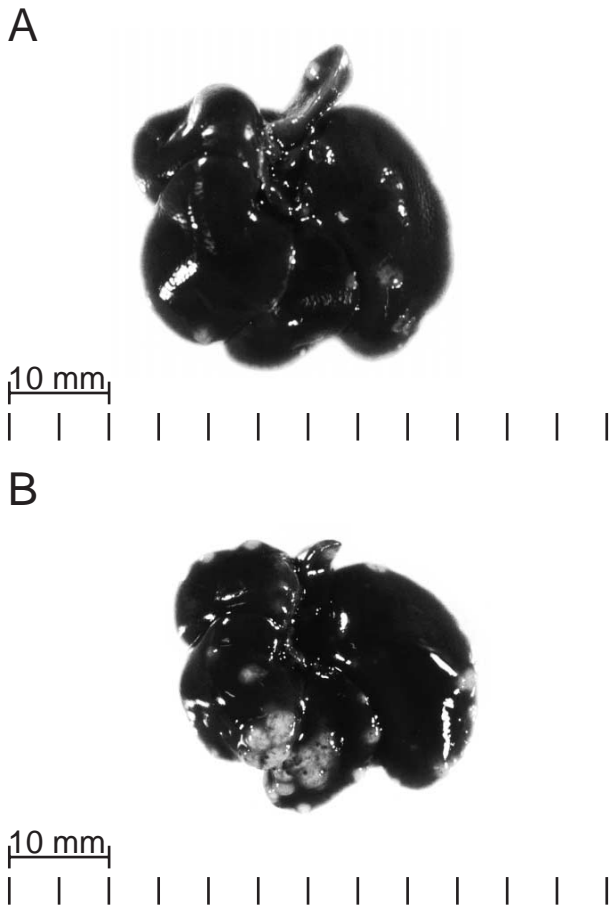


Fig. 1. Macroscopic appearance of liver metastases. A: Liver of a hamster treated with angiostatin, showing several small metastases on the surface. B: Liver of a hamster of the saline control group. Note that the liver surface is covered with multiple metastases larger than 4 mm in diameter.

(mean±SD) in the angiostatin-treated hamsters was 5.00 ± 1.76 , versus 16.40 ± 5.19 in the control hamsters ($P < 0.001$). The diameter of the largest metastatic nodule in every hamster in the treatment group was 1.49 ± 0.61 mm, versus 3.94 ± 1.10 mm in the control group ($P < 0.001$) (Fig. 2).

Histological and immunohistochemical examination

Examination of H-E stained sections revealed that the metastatic liver tumors were moderately to well differentiated adenocarcinomas, and no clear histological differences were observed between the treatment group and the control group (Fig. 3). The liver metastases in the treatment group and the control group were compared for microvessel density as determined by direct microvessel counting of cells that stained for von Willebrand factor receptor antigen. Tumor vascularity was most prominent at the

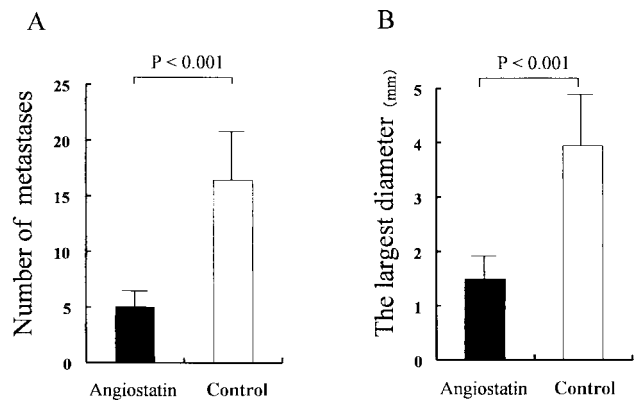


Fig. 2. Systemic treatment with angiostatin inhibited the growth of liver metastases in hamsters. Number of metastases (A) and the diameter of the largest metastatic nodule (B) in the angiostatin treatment group and the saline control group. Columns, mean; bars, SD.

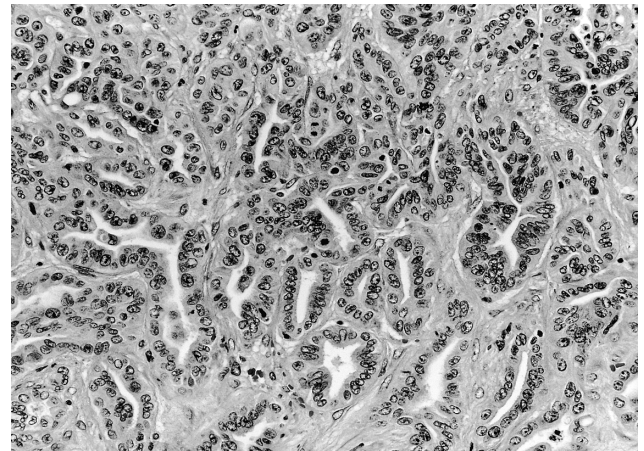


Fig. 3. H-E staining of metastatic liver tumors in pancreatic cancer of hamster. Tumors of the treatment and the control groups were moderately to well differentiated adenocarcinomas which morphologically resemble human pancreatic cancer. $\times 140$.

periphery of the metastatic nodules. In the areas with the highest microvessel density, there were only a few isolated microvessels per 200-fold magnification field in the treatment group. By contrast, abundant, dense microvessels which formed arborescent development in the tumor were observed in the control group, indicating that the tumor tissue was highly vascularized. The mean MVD (mean±SD) in the treatment group and that in the control group were 19.59 ± 7.28 and 39.99 ± 11.00 , respectively. The MVD value in the angiostatin group was significantly lower than in the control group ($P < 0.001$) (Fig. 4).

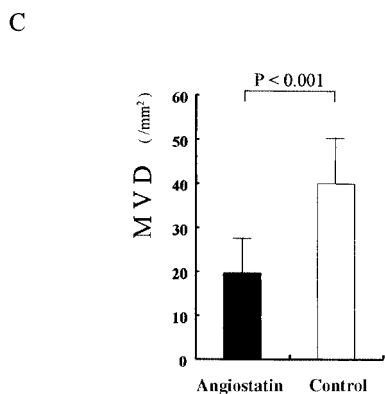
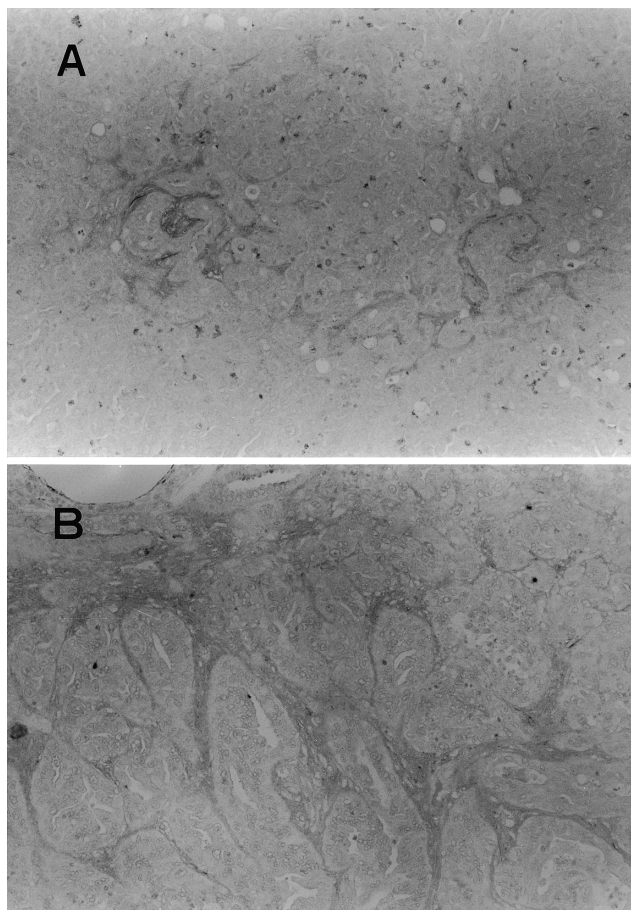


Fig. 4. Immunohistochemical analysis of vascularization of liver metastases was performed by staining with polyclonal antibody against von Willebrand factor. A: Tumor section of the angiostatin treatment group showed only a few positively stained vascular endothelial cells. B: Similar section of the saline control group showed highly vascularized tumor tissue. $\times 140$. C: Microvessel density (MVD) was quantified by direct counting of positively stained endothelial cells. Columns, mean; bars, SD.

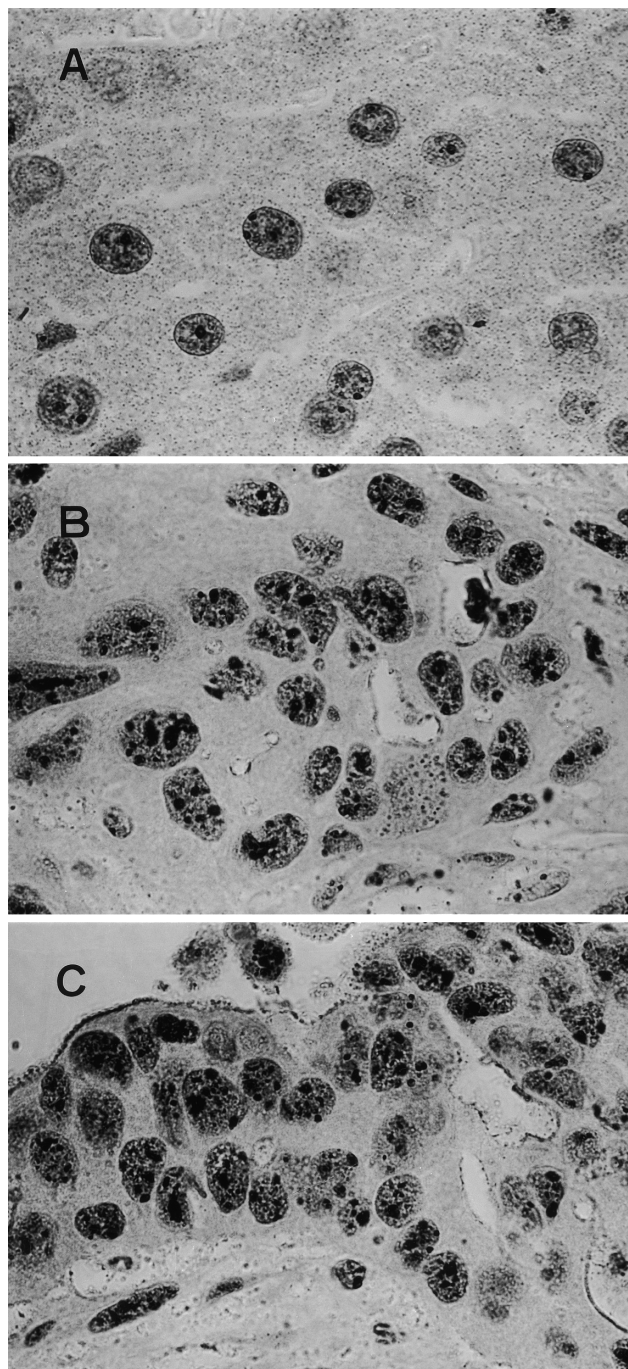


Fig. 5. Proliferation of liver metastatic tumor was analyzed by argyrophilic nucleolar organizer region (Ag-NOR) staining. A: Normal liver cells of hamster showed a few distinct black dots in the nuclei. B: Tumor cells in the angiostatin treatment group and C: in the saline control group showed an evident increase in irregular black dots. $\times 700$.

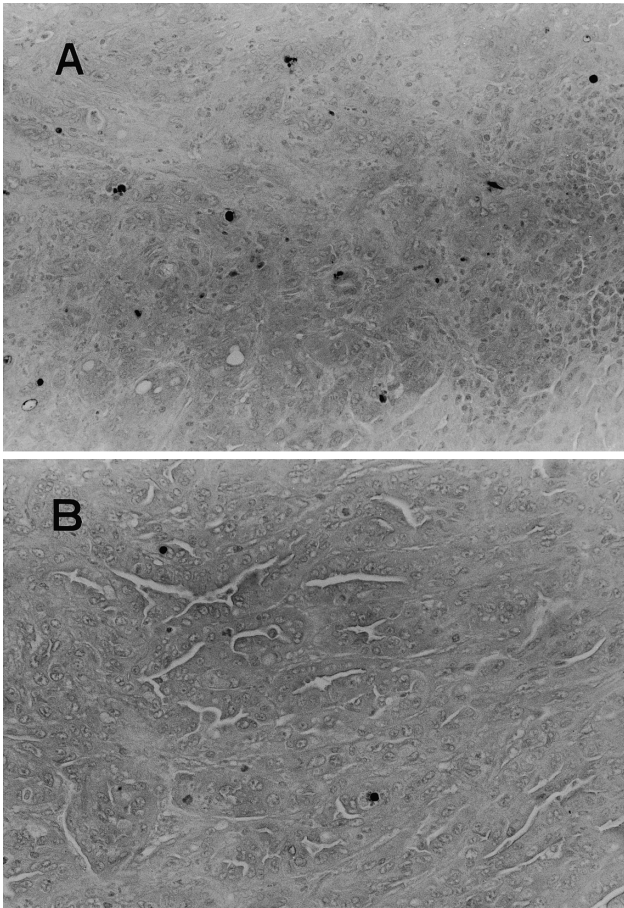


Fig. 6. The presence of apoptotic cells was determined by TUNEL assay in the metastatic liver tumors. A: A high density of positively stained apoptotic cells was observed in the angiostatin treatment group. B: Only a few apoptotic cells were detected in the saline control group. $\times 140$.

Tumor cell proliferation and apoptosis Proliferation of the metastatic liver tumor cells in the treatment group and the control group was estimated by Ag-NOR staining. An increase in irregular black dots was evident in most tumor cell nuclei, whereas only a few distinct small black dots were observed in normal liver cells (Fig. 5). The Ag-NOR scores (mean \pm SD) in the treatment group and the control group were 9.10 ± 1.66 and 9.33 ± 1.72 , respectively (Fig. 7), and the difference between the groups was not significant. Metastatic liver tumors were highly proliferative, irrespective of treatment with angiostatin.

Analysis of the apoptotic index evaluated by TUNEL staining indicated a higher incidence of apoptosis in the treatment group (Fig. 6), with values (mean \pm SD) of $2.04\pm 0.40\%$ in the treatment group and $0.63\pm 0.26\%$ in the control group ($P<0.001$) (Fig. 7). Angiostatin increased the number of apoptotic tumor cells in the liver metastases.

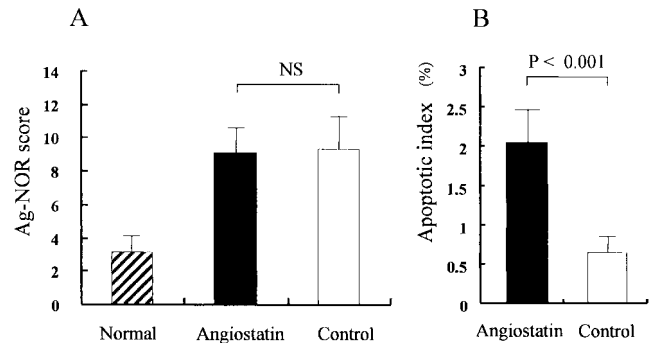


Fig. 7. Quantitative assessment of proliferative and apoptotic indices of liver tumors in the angiostatin treatment group and the saline control group. A: Ag-NOR score showed no significant difference of proliferation between the two groups. B: The apoptotic index showed a three-fold higher incidence of apoptosis in the treatment group than that in the control group. Columns, mean; bars, SD; NS, not significant.

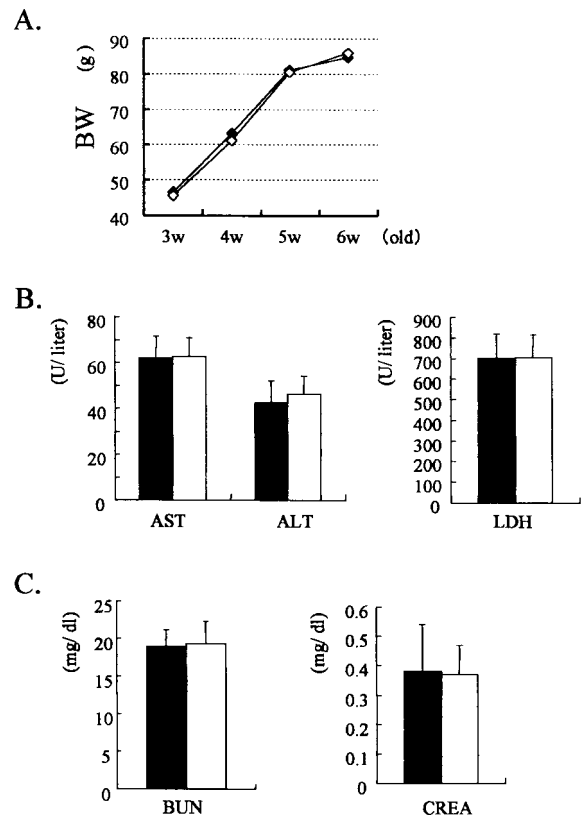


Fig. 8. Angiostatin had no apparent side effects in hamsters. The body weight in both groups (A; \blacklozenge angiostatin, \diamond control) developed equally. The blood biochemistry tests showed no significant differences in liver (B) or kidney (C) function at termination. \blacksquare angiostatin, \square control.

Assessment of angiostatin toxicity There was no body weight loss in either group at the time of sacrifice, and the blood biochemistry tests (AST, ALT, LDH, BUN, Crea) showed no significant differences in liver or kidney function (Fig. 8). Moreover, wound healing in hamsters was not affected by systemic treatment with angiostatin, as judged from macroscopic observation. No other abnormalities were detected in any of the hamsters.

DISCUSSION

The growth of solid tumors is generally dependent on angiogenesis,²¹⁾ and the process of metastasis is also dependent on angiogenesis, because new blood vessels supply not only the nutrients and oxygen needed for tumor growth, but also a pathway to distant organs for metastasis to occur.²²⁾ Pancreatic cancer is generally thought to consist of hypovascular tumors with fibrosis and high invasiveness compared with other digestive organ cancers, but such tumors also require neovascularization to grow, and recent investigations have shown that angiogenesis inhibitors are effective against pancreatic cancer.²³⁾ Inhibition of angiogenesis may also become an effective therapy against liver metastasis of pancreatic cancer, the same as in other solid tumors. Recently, many different angiogenesis inhibitors have been investigated, and some of them have already begun to be tested in humans.²⁴⁾ Angiostatin, a fragment of plasminogen protein, has potent antiangiogenic activity, as reported by O'Reilly and co-workers.^{12, 13, 25)} Angiostatin protein selectively inhibits endothelial cell proliferation *in vitro*,^{12, 13, 15)} and the effects of angiostatin on various solid tumors, both human and murine *in vivo* are reported. However, to our knowledge, our study is the first to describe an antiangiogenic effect of angiostatin on liver metastases in pancreatic cancer. Our study showed that angiostatin can cause liver metastases of pancreatic cancer to remain in a nearly dormant state as a result of a balance between apoptosis and proliferation of the tumor in the presence of blocked angiogenesis, without detectable side effects.

In our experiment, metastatic liver tumors treated with angiostatin never grew larger than 2 mm, whereas in the absence of angiostatin they grew to over 4 mm in the largest diameter. Significant tumor growth retardation and potently inhibited angiogenesis of metastatic liver tumors were observed under treatment with angiostatin. These results corroborate experimental data indicating that tumors are dependent on new blood vessel formation to grow larger than a few millimeters in diameter.^{26, 27)}

However, there was no significant difference between the two groups in tumor proliferation estimated by Ag-NOR staining. Increases in Ag-NOR score per nucleus are known to be attributable to cellular proliferative and transcriptional activity.^{19, 28, 29)} Some reports have shown that

the Ag-NOR score is closely correlated with 5-bromo-2'-deoxyuridine (BrdU) and Ki-67 labeling indices,^{30, 31)} and the Ag-NOR score is an indicator of the biological malignancy of cancer in the pancreatic ducts as well as of patient outcome.³²⁾ The mean Ag-NOR score in pancreatic cancer patients in our previous study was 4.02,³³⁾ and Toyota *et al.* reported a score of 3.82.³²⁾ However, in this study the Ag-NOR score of liver metastases of pancreatic cancer in the hamster was over 9.10 in the treatment group and the control group. This suggested that PGHAM-1, the hamster pancreatic cancer cell line, has greater proliferation ability than human pancreatic cancer. The higher Ag-NOR score in both groups in our experiment indicated that angiostatin had little effect on tumor cell proliferation.

The apoptotic index of the tumor cells in the treatment group in this study increased to three times that of the control group, suggesting that angiostatin controlled metastatic tumor growth by indirectly increasing apoptosis of the tumor cells without affecting tumor cell proliferation. O'Reilly *et al.* noted that about 7% of tumor cells undergo apoptosis in tumors in a completely dormant state.^{14, 34)} The apoptotic index in this liver metastasis model, however, was 2.04%, three times lower than in O'Reilly's report. This means that metastatic liver tumors treated with angiostatin inhibited angiogenesis, but did not induce a completely dormant state in this model. There are several possible reasons for this. The first is the dose of angiostatin used in this experiment. We injected hamsters with 1.2 mg/kg of human angiostatin on the day of operation, followed by 0.6 mg/kg/day. A variety of doses of angiostatin, from 0.6 to 100 mg/kg per day, have been tested in animal models by different investigators. Inhibition of metastatic tumor growth occurred at doses of approximately 1 mg/kg per day,^{12, 13)} and inhibition of primary tumor growth was first observed at 10 mg/kg per day.¹⁴⁾ Larger doses of angiostatin might cause more apoptosis and induce dormancy in this model of liver metastasis. The second reason is the half-life of angiostatin in the circulation. O'Reilly *et al.* found that human angiostatin had a short half-life (4–6 h),¹⁴⁾ and in view of the rapid clearance of human angiostatin, two or three injections per day should be more effective. The third reason is the high proliferation ability of our hamster pancreatic cancer cell line, PGHAM-1. It has been selected over many years for rapid growth and a high rate of metastasis. Our preliminary study confirmed that hamsters inoculated with PGHAM-1 cells always died of generalized carcinomatosis within 30 days, and thus the tumors may have greater proliferation ability and more potent angiogenic factors than human tumors.

The mechanism by which angiostatin causes tumor cell apoptosis is still unknown, but it has been proposed that complete inhibition of angiogenesis may result in the loss of paracrine growth factors produced by capillary endothe-

lial cells and needed by the tumor cells.^{14, 35)} Alon *et al.* reported that the decrease in number of tumor cells may also result in decreased production of survival and growth factors required by the endothelial cells.³⁶⁾ Claesson-Welsh *et al.* recently reported that angiostatin treatment has no effect on growth factor-induced signal transduction, but leads to an RGD-independent induction of the kinase activity of focal adhesion kinase, suggesting that the biological effects of angiostatin relate to subversion of adhesion plaque formation in endothelial cells.³⁷⁾

Reports of several types of angiostatin therapy are currently available. Recombinant murine angiostatin potently inhibits the proliferation of bovine capillary endothelial cells and suppresses the growth of primary Lewis lung carcinoma.³⁸⁾ The inhibitory effects of the individual or combined kringle structures of angiostatin were also investigated,³⁹⁾ and the kringle 5 fragment of human plasminogen was found to be a specific inhibitor for endothelial cell proliferation.⁴⁰⁾ Combined therapy of angiostatin and ionizing radiation has also been reported,⁴¹⁾ and the effects of gene therapy with angiostatin complementary DNA

have been described.^{42, 43)} This is a promising strategy as a new effective antiangiogenic therapy that does not require high-dose angiostatin protein administration. To improve the therapeutic results, the most appropriate angiostatin therapy should be selected according to its effects in these experiments.

In summary, angiostatin therapy may be effective against liver metastases of pancreatic duct cell carcinoma, which is one of the most intractable of the cancers arising in the digestive organs. Further studies are needed to elucidate more clearly the antitumor mechanism of angiostatin for appropriate clinical application.

ACKNOWLEDGMENTS

This study was partly supported by a research grant from "The Promotion and Mutual Aid Corporation for Private Schools of Japan."

(Received March 4, 2000/Revised April 26, 2000/Accepted May 10, 2000)

REFERENCES

- Livingston, E. H., Welton, M. L. and Reber, H. A. Surgical treatment of pancreatic cancer. The United States experience. *Int. J. Pancreatol.*, **9**, 153–157 (1991).
- Tominaga, S. and Oshima, A. Cancer mortality and morbidity statistics Japan and the World—1999. *Gann Monogr. Cancer Res.*, **47** (1999).
- Tsiotos, G. G., Farnell, M. B. and Sarr, M. G. Are the results of pancreatectomy for pancreatic cancer improving? *World J. Surg.*, **23**, 913–919 (1999).
- Fortner, J. G. Regional pancreatectomy for cancer of the pancreas, ampulla, and other related sites. Tumor staging and results. *Ann. Surg.*, **199**, 418–425 (1984).
- Westerdahl, J., Andren-Sandberg, A. and Ihse, I. Recurrence of exocrine pancreatic cancer—local or hepatic? *Hepatogastroenterology*, **40**, 384–387 (1993).
- Pedrazzoli, S., DiCarlo, V., Dionigi, R., Mosca, F., Pederzoli, P., Pasquali, C., Kloppel, G., Dhaene, K. and Michelassi, F. Standard versus extended lymphadenectomy associated with pancreatoduodenectomy in the surgical treatment of adenocarcinoma of the head of the pancreas: a multicenter, prospective, randomized study. Lymphadenectomy Study Group. *Ann. Surg.*, **228**, 508–517 (1998).
- Warshaw, A. L. and Castillo, C. F. Pancreatic carcinoma. *N. Engl. J. Med.*, **326**, 455–465 (1992).
- Inoue, S., Nakao, A., Kasai, Y., Harada, A., Nonami, T. and Takagi, H. Detection of hepatic micrometastasis in pancreatic adenocarcinoma patients by two-stage polymerase chain reaction/restriction fragment length polymorphism analysis. *Jpn. J. Cancer Res.*, **86**, 626–630 (1995).
- Shishido, T., Yasosima, T. and Hirata, K. Establishment and characterization of human pancreatic carcinoma lines with a high metastatic potential in the liver of nude mice. *Surg. Today*, **29**, 519–525 (1999).
- Pour, P. M., Kruger, F. W., Althoff, J., Cardesa, A. and Mohr, U. Cancer of the pancreas in Syrian golden hamster. *Am. J. Pathol.*, **76**, 349–358 (1974).
- Pour, P. M., Runge, R. G., Birt, D., Gingell, R., Lawson, T., Nagel, D., Wallcave, L. and Salmasi, S. Z. Current knowledge of pancreatic carcinogenesis in the hamster and its relevance to the human disease. *Cancer*, **47**, 1573–1589 (1981).
- O'Reilly, M. S., Holmgren, L., Shing, Y., Chen, C., Rosenthal, R. A., Moses, M., Lane, W. S., Cao, Y., Sage, E. H. and Folkman, J. Angiostatin: a novel angiogenesis inhibitor that mediates the suppression of metastases by a Lewis lung carcinoma. *Cell*, **79**, 315–328 (1994).
- O'Reilly, M. S. Angiostatin: an endogenous inhibitor of angiogenesis and of tumor growth. *EXS*, **79**, 273–294 (1997).
- O'Reilly, M. S., Holmgren, L., Chen, C. and Folkman, J. Angiostatin induces and sustains dormancy of human primary tumors in mice. *Nat. Med.*, **2**, 689–692 (1996).
- Sim, B. K. L., O'Reilly, M. S., Liang, H., Fortier, A. H., He, W., Madsen, J. W., Lapcevich, R. and Nacy, C. A. A recombinant human angiostatin protein inhibits experimental primary and metastatic cancer. *Cancer Res.*, **57**, 1329–1334 (1997).
- Yokoyama, T., Onda, M. and Uchida, E. Rapid formation of pancreatic tumors by intrapancreatic transplantation of a newly established hamster carcinoma cell line (PGHAM-1) and its sequential analysis. *J. Jpn. Panc. Soc.*, **11**, 411–420 (1996) (in Japanese with English abstract).
- Inoue, M., Onda, M. and Uchida, E. The significance of blood group-related antigen A in a pancreatic cell line

- (PGHAM-1) in hamsters. With special reference to cell proliferation. *J. Nippon Med. Sch.*, **64**, 30–38 (1997) (in Japanese with English abstract).
- 18) Ploton, D., Menager, M., Jeannesson, P., Himber, G., Pigeon, F. and Adnet, J. J. Improvement in the staining and in the visualization of the argyrophilic proteins of the nucleolar organizer region at the optical level. *Histochem. J.*, **18**, 5–14 (1986).
 - 19) Howat, A. J., Giri, D. D. and Cotton, D. W. Nucleolar organizer regions in Spitz nevi and malignant melanomas. *Cancer*, **63**, 474–478 (1989).
 - 20) Gavrieli, Y., Sherman, Y. and Ben-Sasson, S. A. Identification of programmed cell death *in situ* via specific labeling of nuclear DNA fragmentation. *J. Cell Biol.*, **119**, 493–501 (1992).
 - 21) Folkman, J. Anti-angiogenesis: new concept for therapy of solid tumor. *Ann. Surg.*, **175**, 409–416 (1972).
 - 22) Folkman, J. Clinical applications of research on angiogenesis. *N. Engl. J. Med.*, **333**, 1757–1763 (1995).
 - 23) Shishido, T., Yasoshima, T., Denno, R., Mukaiya, M., Sato, N. and Hirata, K. Inhibition of liver metastasis of human pancreatic carcinoma by angiogenesis inhibitor TNP-470 in combination with cisplatin. *Jpn. J. Cancer Res.*, **89**, 963–969 (1998).
 - 24) Nelson, N. J. Inhibitors of angiogenesis enter phase III testing (news). *J. Natl. Cancer Inst.*, **90**, 960–963 (1998).
 - 25) Lannutti, B. J., Gately, S. T., Quevedo, M. E., Soff, G. A. and Paller, A. S. Human angiostatin inhibits murine hemangi endothelioma tumor growth *in vivo*. *Cancer Res.*, **57**, 5277–5280 (1997).
 - 26) Folkman, J. Tumor angiogenesis: therapeutic implications. *N. Engl. J. Med.*, **285**, 1182–1186 (1971).
 - 27) Folkman, J. What is the evidence that tumors are angiogenesis dependent? *J. Natl. Cancer Inst.*, **82**, 4–6 (1990).
 - 28) Alberts, B., Bray, D. and Lewis, T. “The Nucleus. Molecular Biology of the Cell,” pp. 483–550 (1989). Garland, New York.
 - 29) NOR — a new method for the pathologist (Editorial). *Lancet*, **1**, 1413 (1987).
 - 30) Di Stefano, D., Mingazzini, P. L., Scucchi, L., Donnetti, M. and Marinozzi, V. A comparative study of histopathology, hormone receptors, peanut lectin binding, Ki-67 immunostaining, and nucleolar organizer region-associated proteins in human breast cancer. *Cancer*, **67**, 463–471 (1991).
 - 31) Tanaka, T., Takeuchi, T., Nishikawa, A., Takami, T. and Mori, H. Nucleolar organizer regions in hepatocarcinogenesis induced by N-2-fluorenylacetylacetamide in rats: comparison with bromodeoxyuridine immunohistochemistry. *Jpn. J. Cancer Res.*, **80**, 1047–1051 (1989).
 - 32) Toyota, N., Katano, K., Takahashi, S., Ohtani, S., Mizusawa, K., Hamazoe, R. and Kaibara, N. The argyrophilic nucleolar organizer region (Ag-NOR) score in invasive ductal carcinoma of the pancreas. *Surg. Today*, **27**, 414–419 (1997).
 - 33) Aimoto, T., Onda, M., Uchida, E. and Asano, G. Study on proliferating potential by Ag-NORs staining in human pancreatic carcinoma. *Jpn. J. Surg. Soc.*, **94**, 78–85 (1993) (in Japanese with English abstract).
 - 34) Holmgren, L., O’Reilly, M. S. and Folkman, J. Dormancy of micrometastases: balanced proliferation and apoptosis in the presence of angiogenesis suppression. *Nat. Med.*, **1**, 149–153 (1995).
 - 35) Hamada, J., Cavanaugh, P. G., Lotan, O. and Nicolson, G. L. Separable growth and migration factors for large-cell lymphoma cells secreted by microvascular endothelial cells derived from target organs for metastasis. *Br. J. Cancer*, **66**, 349–354 (1992).
 - 36) Alon, T., Hemo, I., Itin, A., Pe’er, J., Stone, J. and Keshet, E. Vascular endothelial growth factor acts as a survival factor for newly formed retinal vessels and has implications for retinopathy of prematurity. *Nat. Med.*, **1**, 1024–1028 (1995).
 - 37) Claesson-Welsh, L., Welsh, M., Ito, N., Anand-Apte, B., Soker, S., Zetter, B., O’Reilly, M. S. and Folkman, J. Angiostatin induces endothelial cell apoptosis and activation of focal adhesion kinase independently of the integrin-binding motif RGD. *Proc. Natl. Acad. Sci. USA*, **95**, 5579–5583 (1998).
 - 38) Zhanggui, Wu, O’Reilly, M. S., Folkman, J. and Yuen, S. Suppression of tumor growth with recombinant murine angiostatin. *Biochem. Biophys. Res. Commun.*, **236**, 651–654 (1997).
 - 39) Cao, Y., Ji, R. W., Davidson, D., Schaller, J., Marti, D., Sohndel, S., McCance, S. G., O’Reilly, M. S., Llinas, M. and Folkman, J. Kringle domains of human angiostatin. Characterization of the anti-proliferative activity on endothelial cells. *J. Biol. Chem.*, **271**, 29461–29467 (1996).
 - 40) Cao, Y., Chen, A., An, S. S. A., Ji, R. W., Davidson, D. and Llinas, M. Kringle 5 of plasminogen is a novel inhibitor of endothelial cell growth. *J. Biol. Chem.*, **272**, 22924–22928 (1997).
 - 41) Mauceri, H. J., Hanna, N. N., Beckett, M. A., Gorski, D. H., Staba, M. J., Stellato, K. A., Bigelow, K., Heimann, R., Gately, S., Dhanabal, M., Soff, G. A., Sukhatme, V. P., Kufe, D. W. and Weichselbaum, R. R. Combined effects of angiostatin and ionizing radiation in antitumor therapy. *Nature*, **394**, 287–291 (1998).
 - 42) Tanaka, T., Cao, Y., Folkman, J. and Fine, H. A. Viral vector-targeted antiangiogenic gene therapy utilizing an angiostatin complementary DNA. *Cancer Res.*, **58**, 3362–3369 (1998).
 - 43) Griscelli, F., Li, H., Bannaceur-Griscelli, A., Soria, J., Opolon, P., Soria, C., Pericaudet, M., Yeh, P. and Lu, H. Angiostatin gene transfer: inhibition of tumor growth *in vivo* by blockage of endothelial cell proliferation associated with a mitosis arrest. *Proc. Natl. Acad. Sci. USA*, **95**, 6367–6372 (1998).