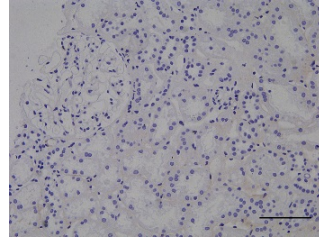
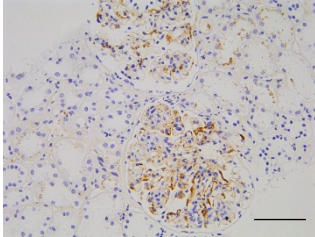


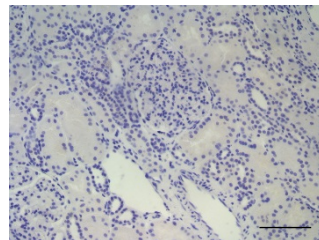
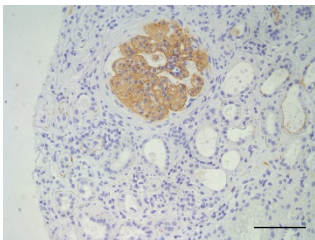
C3 GLOMERULOPATHY

THIN BASEMENT MEMBRANE DISEASE

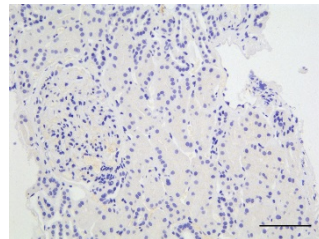
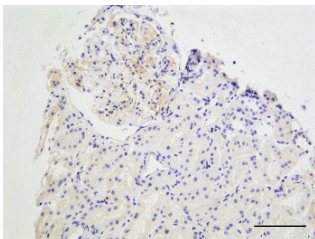
C3c/C3b/iC3b



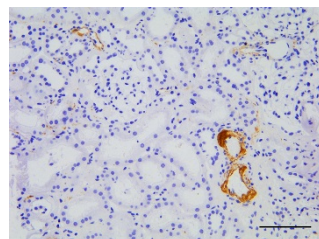
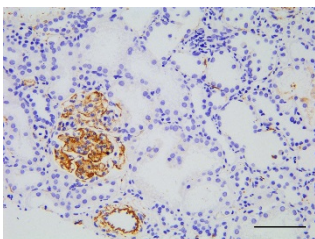
C3d



C4d



C5b9



Supplemental figure 2. Representative images of renal immunohistochemistry staining for complement pathway antigens: C3c/C3b/iC3b, C3d, C4d and C5b-9. To optimise our staining protocols we used renal tissue from patients with either C3 glomerulopathy (positive control) or thin basement membrane disease (negative control). Bar represents 100 μ m.