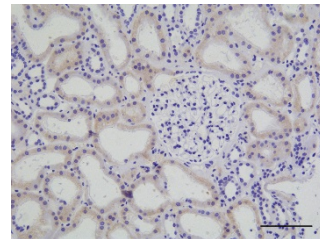
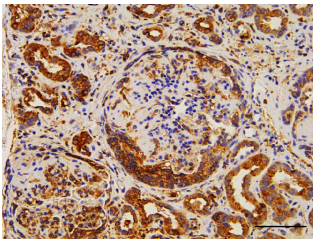


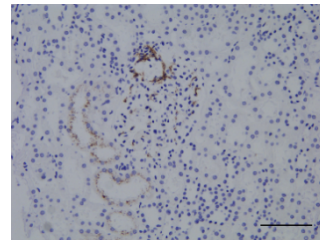
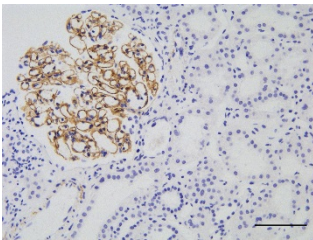
### C3 GLOMERULOPATHY

### THIN BASEMENT MEMBRANE DISEASE

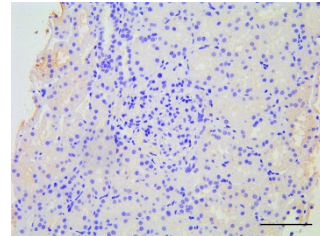
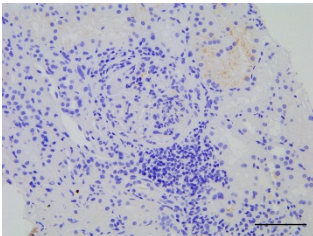
FHR1



FHR5



fH



**Supplemental figure 3.** Representative images of renal immunohistochemistry staining for complement pathway antigens: FHR1, FHR5 and fH. To optimise our staining protocols we used renal tissue from patients with either C3 glomerulopathy (positive control) or thin basement membrane disease (negative control). FHR – factor H-related, fH – factor H. Bar represents 100  $\mu$ m.