

# GLASGOW MEDICAL JOURNAL

VOLUME 28

SEPTEMBER 1947

NUMBER 9

THE JOURNAL OF THE ROYAL MEDICO-CHIRURGICAL SOCIETY OF GLASGOW

## IRON-STAINING ERYTHROCYTIC INCLUSIONS WITH ESPECIAL REFERENCE TO ACQUIRED HAEMOLYTIC ANAEMIA.

A. J. S. MCFADZEAN, M.B., Ch.B., M.R.C.P.(Lond.)

and

I. J. DAVIS, M.D., F.R.C.P.(Lond. & Edin.), F.R.F.P.S.G., F.R.S.E.

*from the Muirhead Department of Medicine, the Royal Infirmary and  
the University, Glasgow.*

### CONTENTS.

Introduction.

Material and Methods.

Morphology and Staining Reactions of the Inclusions.

- (a) Peripheral Blood.
- (b) Sternal Marrow.
- (c) Spleen.

The Frequency of the Inclusion Bodies in Various Pathological States.

- (a) Acquired haemolytic anaemia.
- (b) Congenital acholuric jaundice.
- (c) Other cases of haemolytic anaemia.
- (d) Miscellaneous haematological conditions.

Discussion.

The relationship of the inclusion bodies to other erythrocytic inclusions.

The nature of the inclusion bodies.

The significance of the inclusion bodies.

- (a) In acquired haemolytic anaemia.
- (b) In congenital acholuric jaundice.
- (c) In other haematological conditions.

Summary.

References.

Appendix: Histories of seven cases of acquired haemolytic anaemia.

Plates 1-7.

### INTRODUCTION.

Erythrocytic inclusion bodies were described by Pappenheimer, Thompson, Parker and Smith (1945) in three cases of anaemia, two of which were haemolytic anaemias of the so-called acquired type, both occurring in women. The third case, in a young man, was one of anaemia of undetermined type associated with splenomegaly. Splenectomy was performed in all three cases and it was only after this operation that the inclusions were seen. The bodies were mostly coccoid in form and of

varying size ; a less common bacillary form was also described. The number in any one affected cell varied from one to twenty or more. They stained a reddish purple or purplish blue with Giemsa and gave a positive iron reaction with potassium ferrocyanide and hydrochloric acid. They failed to stain with Mallory's phosphotungstic acid haematoxylin, gave negative Feulgen reaction and did not take Gram's stain. Similar inclusions were demonstrated within the endothelial cells of the splenic sinuses in the spleens removed at operations. The two cases of haemolytic anaemia proved fatal, and, at autopsy, bodies similar to the erythrocytic inclusions were seen in the reticulo-endothelial cells of the bone marrow, liver, and lymph nodes. After extensive morphological and cultural studies, the writers concluded that 'although morphological characteristics suggest a relationship to intra-erythrocytic parasites, no conclusive proof of their parasitic nature has been obtained.' They discussed an alternative interpretation that the inclusions were identical with the siderotic material of siderocytes described by Grüneberg (1941, 1942). In the course of a subsequent review of material from a wide range of cases, these observers found apparently identical inclusions in the peripheral blood in two of eleven cases of thrombocytopenic purpura, in four of sixteen cases of haemolytic jaundice, and in two of ten cases of sickle-cell anaemia. In the three cases which showed them most abundantly splenectomy had been performed ; one of these was a case of thrombocytopenic purpura. Similar inclusions were demonstrated in the endothelial cells of the spleen in twenty-four of thirty-two cases of purpura haemorrhagica, in eight of nineteen cases of haemolytic jaundice, in seven of eleven fatal cases of rheumatic fever, and in four of a group of twenty-two cases consisting of Banti's disease, cirrhosis of the liver and congestive splenomegaly.

The present investigation was instigated by the observation of inclusions displaying similar morphology and staining reactions in a case of haemolytic anaemia after splenectomy. Preparations of the peripheral blood of this case were sent to Dr. Pappenheimer, who, in a personal communication, confirmed their apparent identity with those studied by him. While we have no desire to add yet another eponym to medical literature, in order to avoid confusion we shall in this paper refer to these inclusion bodies as Pappenheimer's bodies.

#### MATERIAL AND METHODS.

The earlier part of this investigation was concerned with the study of inclusion bodies in seven cases of haemolytic anaemia. Case histories of the patients are given in the appendix. It may be noted here that all the cases are regarded as examples of acquired haemolytic anaemia of unknown aetiology, and that splenectomy was performed in all of them with the exception of Case 4 in which spontaneous recovery occurred. No. 7 was a middle aged man, but all the others were women ranging from 21 to 58 years of age. Nos. 1 to 4 were patients under our care,

Nos. 5 and 6 were patients of Professor L. S. P. Davidson and No. 7 a patient of Dr. J. N. M. Chalmers, both of whom kindly provided us with case histories and haematological preparations.

The blood and sternal marrow films were fixed or stained within 24 hours of their preparation. For the demonstration of iron the films were treated with equal parts of 2% potassium ferrocyanide and 2% hydrochloric acid in distilled water, and counter-stained with dilute carbol fuchsin. With this stain the most satisfactory preparations were obtained after formalin vapour fixation. The  $\alpha\alpha$  dipyriddy and potassium thiocyanate technique described by Case (1944) was employed in some instances. Potassium thiocyanate and  $\alpha\alpha$  dipyriddy were also used separately as indicators of ferric and ferrous iron respectively, and sodium diethyl dithiocarbamate was occasionally employed as a specific indicator for iron. Other stains employed were Leishman's stain, methylene blue, haematoxylin, methyl green, Pappenheim's pyronin methyl green, Gram's stain, cresyl blue, Nile blue sulphate, and an aqueous solution of hydrogen sulphide. All the inclusion counts recorded were made on Leishman preparations and were repeatedly checked by correlation with the iron stain. As a further precaution to obviate error in confusing nuclear particles with inclusions in Leishman stained films, preparations were, from time to time, stained with methyl green.

#### MORPHOLOGY AND STAINING REACTIONS OF THE INCLUSIONS.

##### *Peripheral Blood.*

In peripheral blood films, the inclusions were seen in erythrocytes, and in normoblasts when these were present. They were never found in members of the white cell series even after prolonged search of preparations made from the 'buffy coat,' and they were never seen lying free in the plasma.

In unstained dried blood films the inclusions were readily seen as refractile and colourless structures. In fresh wet preparations the individual inclusions showed no active motility and they occurred mainly towards the periphery of the cells. In Leishman stained preparations considerable variation in shape and size was evident. Examples are illustrated in the accompanying plates. The commonest form was a rounded body varying in size from a granule which was just visible to one 2 microns in diameter, but most commonly of the order of 0.5 microns. Where there was more than one inclusion in a cell, inequality of size was the rule. Not infrequently diplococcal and trefoil figures were seen giving an impression of fusion or of incomplete division. Rod forms, while less common than the coccoid forms, were not infrequent and have been seen in all cases. Such forms occurred alone or, more commonly, together with other forms within the same cell. They varied from 1 to 6 microns in length and from 0.1 to 0.5 microns in breadth. Individual rods showed variation in thickness and some were club-shaped. 'Tadpole-shaped' inclusions were frequent in three cases, in one of which they accounted for 80 per cent of inclusions seen. Meteor shapes, large irregular masses and amoeboid forms were also occasionally seen.

The number of inclusions within an individual red cell was variable.

In our cases of haemolytic anaemia before splenectomy the majority of affected cells contained only a single inclusion and rarely more than three. After splenectomy, however, multiple inclusions were common. These were frequently large, but when the inclusions within an individual erythrocyte were very numerous they tended to be small. Red cells containing numerous small inclusions when stained with Leishman resembled the stippling of punctate basophilia.

Stained with Leishman, the inclusions displayed a blue colour ranging from a purplish blue, so dark as to appear almost black, to blue. The majority of coccoid forms stained a uniform purplish blue. Other forms showed variation in staining reaction even within the same inclusion, notably the rod, tadpole, and amoeboid forms. In the rod forms rounded areas of purplish blue alternated with intervening bridges of lighter blue. In the tadpole forms the body stained either purplish blue or, less commonly, a lighter blue, but the tail usually stained blue, and was never sharply defined from the cytoplasm of the erythrocyte. The irregular or amoeboid inclusions had a foamy blue or, less commonly, purplish blue appearance and contained scattered purplish blue granules. Such forms were not sharply defined.

The inclusions staining purplish blue or showing a purplish blue component invariably gave a positive iron reaction. This was established by defining accurately such inclusions within a selected group of cells, destaining with acid alcohol and applying the iron stain. Inclusions, or components thereof, that stained blue with Leishman, usually, but not invariably, gave a positive iron reaction, but this was in the main less intense than in the case of the purplish blue inclusions, and was occasionally masked by the counterstain. Thus, in some of our preparations, amoeboid forms, when stained for iron and counter-stained, appeared as a small group of discrete iron positive granules in some instances inset in a poorly defined reddish body displaying a vague bluish tint. Stained for iron without the counterstain, however, these inclusions appeared as intensely staining granules surrounded by amorphous material giving a weaker, but a definitely positive, reaction for iron. In the tadpole type of inclusion the tail frequently failed to give an iron reaction. A small proportion of coccoid inclusions giving a blue reaction with Leishman failed to stain for iron even when subjected to preliminary treatment with ammonium sulphide. It may be noted that the differentiation of these bodies from nuclear particles was established by their failure to take the nuclear stains mentioned below.

After splenectomy in Cases 2 and 5 and, to a lesser degree, in Case 3 numerous small inclusions were a prominent feature in normoblasts and erythrocytes. In the majority of these cells the individual inclusions were rather coarse and sharply defined, whereas in the minority they were very fine and mostly ill-defined. Stained with Leishman many

of these cells resembled basophilic stippling. In the majority of such cells counts of the granules revealed that only a variable proportion of the bodies staining with Leishman gave an iron reaction (Plate 1, Figs. 6a and b), but in some cases the number and pattern of the iron positive granules were identical with the Leishman staining granules. It may be stated that the coarser the granules the greater was the number giving an iron reaction. Investigation of the cells in which the granules were small and ill-defined was technically difficult, since, in a substantial number of such cells, a few well-defined granules coexisted; but it may be stated that, in general, ill-defined inclusions did not give a positive iron reaction.

Very deeply staining polychrome erythrocytes were not infrequently seen in Cases 2 and 6. Within the majority of these a fine mesh of iron-positive material, partly or wholly filling the cell, was demonstrated (Plate 2, Fig. 7 and Plate 4).

In order to determine whether variation in the iron content would modify the staining reaction with Leishman, a piece of flannel, after thorough preliminary washing, was soaked in a dilute solution of ferric chloride and cut into four pieces which were washed with water for 15 minutes, 30 minutes, 1 hour and 2 hours respectively. A fragment from each piece was then subjected to the prussian blue reaction. The remainder of each piece was stained with dilute Leishman. All four pieces gave a positive iron reaction but of diminishing intensity proportional to the duration of washing. The piece washed for 15 minutes stained purplish blue with Leishman, that washed for 2 hours stained blue, and the pieces washed for the intervening periods showed gradation from purplish blue to blue. Untreated flannel stained blue. From this experiment it seems reasonable to assume that variation in the iron content of the inclusions may influence their staining reaction with Leishman.

The other staining reactions were as follows. The potassium thiocyanate and  $\alpha\alpha$  dipyridyl technique described by Case (1944) was tried, but failed to stain the inclusions, a point which will be discussed later. The inclusions stained readily with methylene blue. With Pappenheimer's pyronin methyl green the morphology of the inclusions was identical with that seen in Leishman preparations. In mature erythrocytes they stained uniformly red against the background of the fully haemoglobinated cell, but in polychrome cells this contrast was not so distinct since the cytoplasm of such cells also stained with pyronin. The inclusions did not stain with methyl green alone. In preparations treated supravivally with cresyl blue the inclusions stained deeply and, in reticulocytes, they appeared enmeshed in the reticulum. With Nile blue sulphate they stained blue. In confirmation of the observations of Pappenheimer *et al.* (1945) it was found that the inclusions failed to stain with haematoxylin and with Gram's stain.

Washed red cells from Case 1 were lysed with distilled water and centrifuged. Films of the deposit contained enormous numbers of bodies having similar morphology and staining reactions to the inclusions in the intact cell (Plate 4). These bodies stained with the potassium thiocyanate and  $\alpha\alpha$  dipyridyl technique of Case (1944), although, as previously noted, when present in the intact erythrocyte they did not do so. They became black on treatment with sodium diethyl dithiocarbamate, and brownish in colour with an aqueous solution of hydrogen sulphide, thus confirming their iron content. They gave a characteristic brownish red reaction with potassium thiocyanate alone, but did not give a colour reaction with  $\alpha\alpha$  dipyridyl unless exposed for prolonged periods. In confirmation of the observations of Pappenheimer *et al.* (1945) it was found that the bodies failed to give the Feulgen reaction, and that the morphology and staining reactions were not affected by exposure to N/20 hydrochloric acid, but that on exposure to NaOH buffered to a pH of 10.5, the iron staining was lost although with Leishman the morphology and staining were unaffected.

*Changes in the red cells containing the inclusions.* Although no measuring technique was employed we feel confident in stating that erythrocytes containing numbers of very large inclusions tend to be smaller in size than normal. Nevertheless, cells showing the marked secondary changes in haemoglobin content described below were frequently larger than normal and were distorted in shape in stained preparations. Otherwise, no constant change in size of affected cells was seen. Inclusions were found within microspherocytes when these were present, but the incidence within such cells was not different from the average. Where the inclusions were small there was little change in the staining quality of the cell content, but where they were large the haemoglobin was apparently reduced, as noted by Pappenheimer *et al.* (1945). With multiple large inclusions this was markedly so, and the haemoglobin was often represented by a faint thin rim. Not infrequently the residual haemoglobin was formed into irregular trabeculae crossing the cell, giving rise to an appearance of coarse vacuolation. Inclusions were frequently present within these trabeculae (see Plates 1 to 4). Rarely the inclusions were surrounded by a well-defined clear zone.

#### *Sternal Marrow.*

Sternal marrow films were available from all seven cases of acquired haemolytic anaemia, in four of which sternal puncture had been performed before and after splenectomy. The films were prepared according to the method described by Davidson, Davis and Innes (1942).

Inclusion bodies identical in staining reaction with those seen in the peripheral blood were present in members of the red cell series, but only in those showing evidence of haemoglobinisation. They were not

seen in the early basophil normoblasts or in early erythroblasts. They were found in monocytes and reticulum cells but in no other type of white cells.

As stated above they were demonstrated in later normoblasts, reticulocytes and mature erythrocytes. In the more fully haemoglobinated cells the inclusions differed in no way from those seen in the peripheral blood. Cells containing multiple large inclusions showed the secondary changes in haemoglobin content already described. In those cells in which the indication of haemoglobination was minimal, inclusions appeared in close proximity to the nucleus but separated from it by a narrow clear zone. They varied in morphology from single or multiple small rounded bodies to crescent-shaped masses occupying a varying proportion of the cell cytoplasm. In Case 6, in which the majority of affected cells in the peripheral blood contained multiple inclusions, the number within any one normoblast in the sternal marrow showed an increase commensurate with the degree of haemoglobination, but this increase was seen only within the stage of polychrome normoblasts, no further increase being seen in the later stages of development. As haemoglobination progressed the inclusions became more defined; in normoblasts in the earlier stages of haemoglobination, when stained with Leishman, they were ill-defined, although with the iron stain definition was sharp, while in the more mature normoblasts stained with Leishman the granules were sharply defined. With maturation of the cell the inclusions came to occupy the position seen in mature erythrocytes, namely towards the periphery of the cell. The trabecular arrangement of the residual haemoglobin and the appearance of vacuolation coincided with the condensation of the nucleus. Not infrequently the cytoplasm of a normoblast seemed to consist entirely of inclusion material and, were it not for the maturity of the nucleus, such a cell, in Leishman preparations, might well have been regarded as a somewhat unusual basophil normoblast (Plate 2, Figs. 5a & b). With the iron stain such a cell appeared as a nucleus surrounded by a blue ring.

In certain of the cases non-nucleated erythrocyte-like bodies with a foamy blue cytoplasm were occasionally seen. With the iron stain these appeared uniformly blue. Red cells containing a fine mesh of iron positive material were also not infrequently seen, similar to those already described in the peripheral blood.

When seen within monocytes and reticulum cells, the inclusions most frequently appeared as discrete granules, but a considerable proportion of them occurred as globulare masses varying from 2 to 6 microns in diameter, staining a purplish blue or blue colour with Leishman and giving a positive iron reaction. Pappenheimer *et al.* (1945) interpreted these masses as a probable result of fusion of the inclusions which had been phagocytosed.

Material giving similar staining reactions was also seen lying free in the marrow as discrete granules and as globulare masses. Presumably

this was due to rupture of affected cells. A striking feature in marrow preparations was the occurrence of small granules of this material in intimate contact with the periphery of a haemoglobinated cell and forming a complete girdle around it (Plate 2, Fig. 6). Commonly, groups of red cells in varying stages of haemoglobinisation occurred in intimate association with the larger masses either lying free or occurring within monocytes. The majority of such cells contained inclusions.

#### *Spleen.*

In the three cases where the spleen was available for examination, bodies, conforming in shape and size with the commonest form occurring in erythrocytes, and giving identical staining reactions, were demonstrable within the endothelial cells lining the sinusoids. They were relatively uniform in size, but large forms were also seen similar to the globulare masses described as occurring within the monocytes of the marrow.

#### THE FREQUENCY OF THE INCLUSION BODIES IN VARIOUS PATHOLOGICAL STATES.

##### *Acquired Haemolytic Anaemia.*

The frequency of erythrocytes showing Pappenheimer's bodies in the peripheral blood of our cases is indicated in Tables 1 to 7 and also in Graphs 1 and 2. Before splenectomy, affected cells were relatively scanty although their frequency appeared to be increased during exacerbations of haemolysis. In Case 1 they were 11 per cent; unfortunately in this case only one blood film taken before splenectomy was available. After splenectomy, a considerable increase in the number of affected cells occurred in all cases, the lowest figure being 16 per cent in Case 3 and the highest 88 per cent in Case 6. As already noted, this increase in the frequency was accompanied by an increase in the size and numbers of inclusions within individual erythrocytes.

In contrast to the peripheral blood, the sternal marrow showed inclusions in a high proportion of normoblasts and erythrocytes before splenectomy. Comparison of marrow preparations with peripheral blood films made on the same day showed that before splenectomy the incidence of erythrocytes containing inclusions was considerably higher in the marrow than in the peripheral blood. In order to obviate the error due to dilution of the marrow preparations with peripheral blood quantitative assessment was restricted to haemoglobinated normoblasts. In those cases in which sternal puncture was performed after splenectomy, namely Cases 1, 3, 5 and 6, the incidence of inclusion-containing haemoglobinated normoblasts was approximately the same as before splenectomy. There was, however, a further increase in the number of mature erythrocytes containing inclusions; this was presumably occasioned by the increase in the number of affected cells in the peripheral blood which was present in the preparation incidentally.



The incidence of inclusions in the sternal marrow appeared to be related to the activity of the haemolytic process. Thus in Case 4 during a haemolytic crisis 60 per cent of fully haemoglobinated normoblasts in the marrow contained inclusions, while in preparations made nine days later, when the patient was in a phase of spontaneous remission, only 3 per cent of such normoblasts were affected. In Case 3 on the first admission, during a phase of spontaneous remission, only 2 per cent of the fully haemoglobinated normoblasts in marrow films contained inclusions, but six weeks later, during a relapse, 25 per cent were affected.

TABLE 1.

## Case 1.

The total erythrocyte counts and the incidence inclusion-containing red cells in the peripheral blood and sternal marrow.

Date	Peripheral Blood		Sternal Marrow	Remarks
	Total R.B.C. Millions/cu.mm.	% Affected Cells	% Affected Normoblasts	
1945				
Oct. 19	1.7			} Jaundiced Reticulocytes 27%
Oct. 21	1.7	11	75	
Oct. 25	1.69			
Oct. 28	1.51			
Nov. 3	1.59			Blood transfusion 2½ pints
Nov. 5	2.33			
Nov. 12	2.27			
Nov. 15	1.19			} Jaundice increased Blood transfusion 3 pints Blood transfusion 5 pints Jaundice decreasing Reticulocytes 9%
Nov. 18		SPLENECTOMY		
Nov. 22	2.86			} Urobilinogen normal Reticulocytes 2%
Nov. 27	2.47			
Dec. 18	2.60			
Dec. 24	2.70	48	80	
1946				
Jan. 1	3.12			
Jan. 7	3.79	66		
Jan. 15	3.86	64		
Jan. 18	4.38	72		Reticulocytes <1% Symptomatically well henceforth
Feb. 20	4.71	64		
Mar. 27	4.3	67		
April 25	4.4	61		
May 17	4.6	72		} Urobilinogen increased Reticulocytes 4%
July 24	4.8	69		
Sept. 14	4.4	70		
Oct. 30	4.45	75		
Nov. 25	4.4	70		
Dec. 20	4.35	74		Reticulocytes 5%
1947				
Mar. 12	4.6	71		
May 4	4.55	73		Reticulocytes 3%
July 30	4.33	82		Reticulocytes 4%

TABLE 2.

Case 2.

The total erythrocyte counts and the incidence of inclusion-containing red cells in the peripheral blood and sternal marrow.

Date	Peripheral Blood		Sternal Marrow	Remarks
	Total R.B.C. Millions/cu.mm.	% Affected Cells	% Affected Normoblasts	
1945				
Dec. 15	1.1	9	70	{ Jaundiced. Reticulocytes 62% Blood transfusion 2 pints
Dec. 18	2.01			
Dec. 24	1.64			{ Jaundice diminishing Reticulocytes 12%
1946				
Jan. 8	2.22			
Jan. 14	2.08	5		
Jan. 22	2.46			{ Reticulocytes 16% Blood transfusion 1 pint
Feb. 2	3.0			
Feb. 9	2.8	6		Blood transfusion 2 pints
Feb. 12	3.3			{ Jaundice increasing Reticulocytes 10%
Feb. 26	2.47			
Mar. 1	2.40	<1		
Mar. 20	2.76	9		{ Icterus free. Reticulocytes 10.5% Urobilinogen increased
April 4	1.22	8		Jaundiced. Reticulocytes 52%
April 7	1.17	4	70	Blood transfusion 3 pints
April 10	2.45	<1		
April 12		SPLENECTOMY		Blood transfusion 2 pints
April 15	2.5	4		
April 18	2.98	17		Icterus free
April 22	3.01	17		{ Urobilinogen normal Reticulocytes 3%
April 27	3.31	42		
May 5	3.4	53		Clinically well
May 12	3.86	66		Reticulocytes <1%
May 16	4.11	61		Urobilinogen increased
May 30	4.0	62		
June 12	3.8	55		
June 22	3.5	60		Reticulocytes 7%
July 5	2.5	60		Symptoms of anaemia
July 24	2.5	44		
Aug. 6	2.3	43		{ Reticulocytes 14% Mildly jaundiced
Sept. 12	4.1	2		{ Well. Urobilinogen normal Reticulocytes <1%
Oct. 20	4.67	3		
Nov. 20	4.6	2		Reticulocytes 1%
Dec. 14	4.7	1		Reticulocytes <1%
1947				
Mar. 9	5.1	1		

TABLE 3.

## Case 3.

The total erythrocyte counts and the incidence of inclusion-containing red cells in the peripheral blood and sternal marrow.

Date	Peripheral Blood		Sternal Marrow	Remarks
	Total R.B.C. Millions/cu.mm.	% Affected Cells	% Affected Normoblasts	
1946				
April 30	2.9			Jaundiced
May 8	3.4			
May 15	2.8			Icterus index 23-17
May 27	2.7			
May 30	3.4	0		Reticulocytes 10-5%
June 3	3.6	0	2	Icterus free. Reticulocytes <1%
June 7	3.5	0		Urobilinogen normal
June 13	3.8	<1		Urobilinogen increased
July 10	4.3	<1		Jaundiced. Reticulocytes 11%
July 18	3.8	<1	25	Reticulocytes 8%
Aug. 2		SPLENECTOMY		
Aug. 4	2.9	<1		
Aug. 8	3.1	3		
Aug. 10	3.0	<1		Urobilinogen normal
Aug. 13	3.3	6		
Aug. 17	3.5	11		
Aug. 19	3.4	12		
Aug. 23	3.8	13	16	
Aug. 26	4.1	10		Reticulocytes <1%
Sept. 11	4.6	2		
Sept. 23	4.5	<1		
Oct. 22	4.9	2		
Nov. 14	4.8	<1		
Dec. 15	4.7	16		
1947				
Feb. 4	4.9	8		
May 3	4.8	2		Reticulocytes <1%

TABLE 4.

## Case 4.

The total erythrocyte counts and the incidence of inclusion-containing red cells in the peripheral blood and sternal marrow.

Date	Peripheral Blood		Sternal Marrow	Remarks
	Total R.B.C. Millions/cu.mm.	% Affected Cells	% Affected Normoblasts	
1946				
Nov. 14	1.06	9	60	{ Jaundiced. Reticulocytes 15% Blood transfusion 2 pints Progressive clinical improvement henceforth
Nov. 17	1.6	0		
Nov. 19	2.3	0		
Nov. 20	2.6	0		
Nov. 21	2.5	0		
Nov. 23	2.7	0	3	Icterus free. Reticulocytes 15%
Nov. 24	2.75	0		
Nov. 29	3.3	0		
Dec. 3	3.5	0		Reticulocytes 6%
Dec. 7	3.7	0		Urobilinogen normal
Dec. 14	4.0	0		Reticulocytes <1%
Jan. 7	4.6	0		
1947				
Mar. 12	4.8	0		

TABLE 5.

## Case 5.

The total erythrocyte counts and the incidence of inclusion-containing red cells in the peripheral blood and sternal marrow.

Date	Peripheral Blood		Sternal Marrow	Remarks
	Total R.B.C. Millions/cu.mm.	% Affected Cells	% Affected Normoblasts	
1946				
Aug. 3	1.67	7	65	{ Jaundiced Reticulocytes 10% Blood transfusions Icterus free Reticulocytes <1%
Aug. 20		SPLENECTOMY		
Sept. 11	3.0			
Sept. 25	2.69	38		
Oct. 21	2.48	24		
Nov. 18			75	{ Clinical picture complicated by development of sub-phrenic abscess.
1947				
Feb. 18	1.2	4*		
Mar. 19	1.22	5*		

\*Normoblasts were a prominent feature in these films and 98% of them contained one or more inclusions.

TABLE 6.

## Case 6.

The total erythrocyte counts and the incidence of inclusion-containing red cells in the peripheral blood and sternal marrow.

Date	Peripheral Blood		Sternal Marrow	Remarks
	Total R.B.C. Millions/cu.mm.	% Affected Cells	% Affected Normoblasts	
1946 Feb. 22	2.18	<1		{ Icterus index elevated Reticulocytes 2%
Mar. 5 Mar. 6 Mar. 22	2.2 2.9	3	85	
April 29		SPLENECTOMY		
May 6 May 17	3.0 3.2			{ Reticulocytes <1% Icterus index normal
		37	80	
May 24 June 4 June 11 July 21	3.13 2.73 2.66 2.3			Reticulocytes 4%
		52		
		88		

TABLE 7.

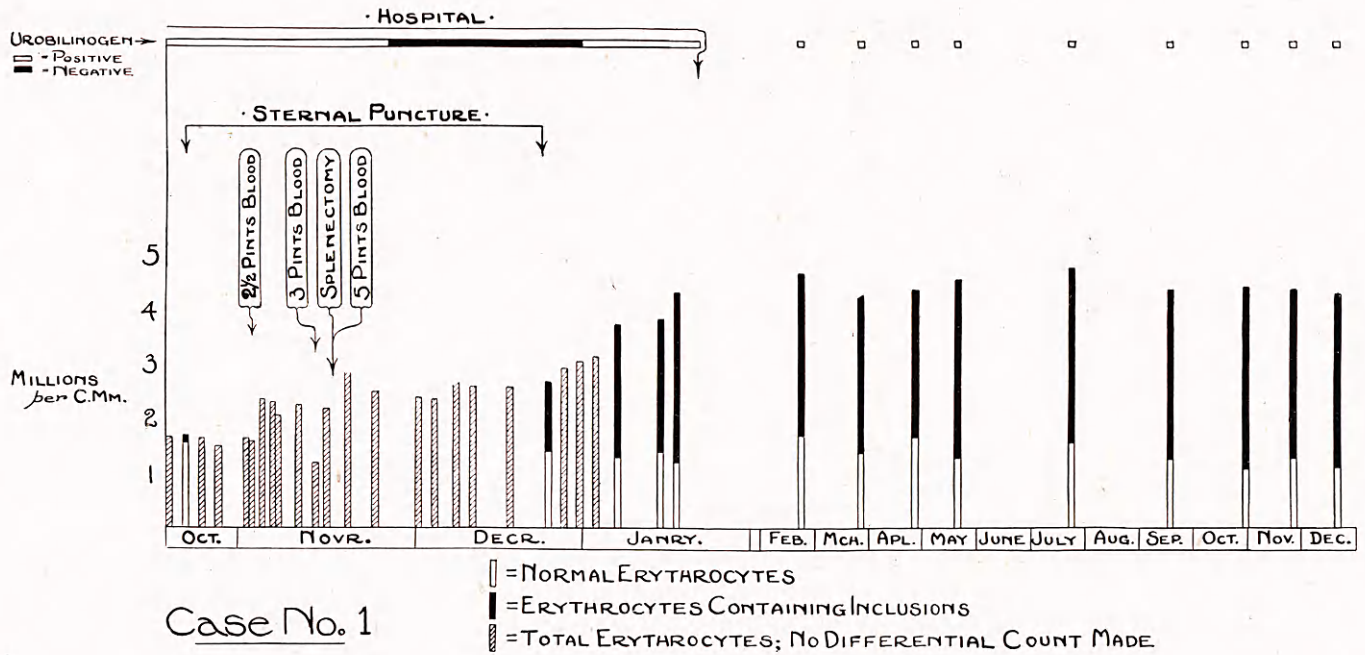
## Case 7.

The total erythrocyte counts and the incidence of inclusion-containing red cells in the peripheral blood and sternal marrow.

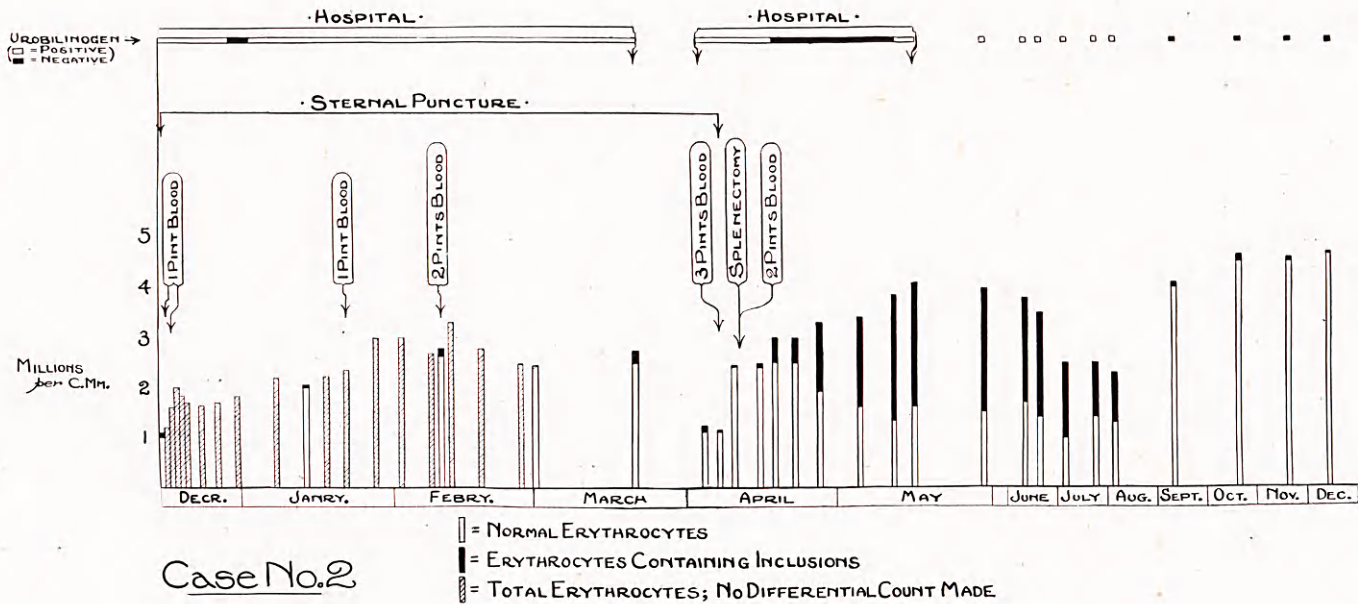
Date	Peripheral Blood		Sternal Marrow	Remarks
	Total R.B.C. Millions/cu.mm.	% Affected Cells	% Affected Normoblasts	
1940 March	2.8	<1	*Present	{ Reticulocytes 2% Icterus index elevated
April		SPLENECTOMY		
May June July	3.7 3.8 4.55	29 21 26		Reticulocytes <1% Icterus index normal

\*Quantitative assessment was not feasible in the preparations available.

Graph 1. The total erythrocyte counts and the incidence of inclusion-containing red cells in the peripheral blood of Case 1.



Graph 2. The total erythrocyte counts and the incidence of inclusion-containing red cells in the peripheral blood of Case 2.



*Congenital Acholuric Jaundice.*

Unfortunately no cases of classical congenital acholuric jaundice came under our care during the course of this investigation. We have, however, obtained, through the courtesy of Drs. H. W. Fullerton and J. V. Dacie, peripheral blood films of two cases both before and after splenectomy. The red cell counts and the incidence of inclusion-containing red cells, with their relationship to splenectomy are set out in Table 8.

TABLE 8.

Case No.	Date	Red cell count	Incidence of inclusions %
1	1945		
	June 8	1,370,000	7
	June 30	2,270,000	3
	July 19	----- SPLENECTOMY -----	
	Sept. 5	4,420,000	1
2	1936		
	Dec. 29	3,400,000	—
	1937		
	Feb. 9	----- SPLENECTOMY -----	
	Mar. 17	4,400,000	2

We have examined marrow preparations from three other cases of congenital acholuric jaundice before splenectomy and found the incidence of inclusion-containing normoblasts to vary from 2 to 7 per cent. <sup>1</sup>

*Other cases of Haemolytic Anaemia.*

Sternal marrow films from five cases of acquired haemolytic anaemia of various types in our files were reviewed. Four of these, reported by Davis (1944), were cases of symptomatic haemolytic anaemia associated respectively with carcinoma of the tail of the pancreas, reticulo-endotheliosis (2 cases), and myeloblastic leukaemia. The remaining case was one of nocturnal haemoglobinuria. The incidence of inclusion-containing normoblasts varied from 0.5 per cent to 6 per cent.

*Miscellaneous Haematological Conditions.*

The results of this investigation are set out in Table 9. It should be noted that all counts were made on films stained for iron.

When present, the inclusions were found in the same cell types as in haemolytic anaemia. They were seen in cells of the megaloblastic as well as the normoblastic series, provided that haemoglobination was evident. In general they did not differ morphologically from those described in haemolytic anaemia, but large, and especially multiple large, forms were rare. Single coccoid or multiple fine inclusions were the rule. Secondary changes in the haemoglobin content of affected red cells were



TABLE 9.

The incidence of Pappenheimer bodies in the peripheral blood and sternal marrow of various haematological conditions.

Condition	PERIPHERAL BLOOD				STERNAL MARROW			
	No. Examined	No. Positive	Incidence of Inclusions %	Remarks	No. Examined	No. Positive	Incidence of Inclusions %	Remarks
Normal . . . . .	62	0	—		18	7	<1	
Splenectomy (Traumatic rupture) ..	1	1	1	6 weeks after splenectomy	0	—	—	
Erythroblastosis Foetalis	3	3	4 to 7	Normoblasts affected predominantly.	0	—	—	
Megaloblastic Anaemia (a) During relapse ..	23	4	2=Scanty 2=0.5-3	During reticulocytosis Cases were negative before liver therapy.	64	64	2.7	Marked decrease in affected red cells.
(b) During response to liver therapy ..	3	2	0.5-2		3	3	<1	
Essential Thrombocyto- paenic Purpura ..	3	2	Case 1=3 ,, 2=Scanty	During erythrocytic re- generation after haemorrhage. Daily observations.	2	2	<1-2	
After splenectomy ..	1	1	1		0	—	—	
Haemorrhage (Haematemesis) ..	5	2	Scanty	During phase of maximal erythrocytic regeneration	0	—	—	
Black-water-fever ...	1	1	2	Coincident with reticulo- cytosis.	1	1	1	
Anaemia in Chronic Infection .. ..	5	2	0.5		5	3	2-5	
Anaemia in Chronic Nephritis with Uraemia	4	3	Up to 2.5		4	4	<1-8	
Anaemia with Marrow Hypoplasia of Undeter- mined Aetiology ..	2	1	0.5		2	2	3-5	
Aplastic Anaemia ..	2	0			2	0	—	
Anaemia associated with Carcinoma .. ..	5	1	Scanty		3	3	$\frac{2}{1} < 1$ =7	No preparation of peri- pheral blood was available.
Leukaemia (a) Chronic myeloid ..	3	2	Up to 1 Scanty 0.7		3	2	$\frac{1}{2-5}$ $\frac{1}{2-5}$ 2-5	Highest incidence in case showing inclusions in peripheral blood.
(b) Myeloblastic ..	2	2						
(c) Monocytic .. ..	2	1						
Iron Deficiency Anaemia	5	0	—					
Hepato-lienal Fibrosis ..	3	0	—		3	1	1	
Polycythaemia ... ..	2	0	—		2	0	—	

rarely seen although they were observed in one of the cases of uraemia, in one of the cases of anaemia associated with carcinoma, and one of the cases associated with marrow hypoplasia of undetermined aetiology. In the sternal marrow, when fine inclusions occurred within normoblasts in early haemoglobination, they were found in close proximity to the nucleus but separated therefrom by a narrow clear zone. As in the cases of acquired haemolytic anaemia, the inclusions tended to be ill-defined in early haemoglobinated cells stained with Leishman, and assumed the definition and morphology of those seen in the peripheral blood as haemoglobination progressed.

#### DISCUSSION.

##### *Relationship of Inclusion Bodies to Other Erythrocytic Inclusions.*

The relationship of Pappenheimer's bodies to other known erythrocytic inclusions may now briefly be considered.

*Nuclear Remnants.* (Howell-Jolly bodies.) The failure of the inclusions to stain with haematoxylin and with methyl green, the negative Feulgen reaction, and the positive iron reaction differentiate them from nuclear remnants.

*Heinz Granules and Isaacs' Granules.* These are readily distinguishable from Pappenheimer's bodies since the former are eosinophilic, and the latter, in unstained preparations appear black when in focus, and fail to stain with the usual stains (Isaacs, 1924).

*Bartonella and Other Parasites.* The possibility of the inclusion bodies being related to blood parasites such as Bartonella, Haemobartonella, Eperythrozoon and Anaplasma has been discussed by Pappenheimer *et al.* (1945) and considered unlikely in the light of the available evidence.

*Grahamella Bodies.* Through the courtesy of Dr. E. S. Horgan, of Khartoum, blood films from gerbils showing numerous Grahamella bodies were examined. Although with Leishman the bodies resembled Pappenheimer's bodies they failed to stain for iron.

*Seidelin's Bodies.* (Paraplasma flavigenum.) These are small bodies occurring in the erythrocytes of guinea-pigs (Wenyon & Low, 1914) staining purplish blue with Leishman. We have observed solitary coccoid inclusions in the blood of young guinea-pigs and found them to give a positive iron reaction. They are therefore possibly related to Pappenheimer's bodies but their significance awaits further investigation.

*Erythrocytic Inclusions in Pyridoxine Deficiency.* Reference is made by Wintrobe, Follis, Miller, Stein, Alcayaga, Humphreys, Suksta and Cartwright (1943) to bodies, staining blue with Wright's stain, seen in the erythrocytes of pigs rendered anaemic as the result of pyridoxine deficiency. It is not stated whether these bodies stain for iron, but it is noteworthy that this form of anaemia is characterised by hyperferraemia and marrow hyperplasia, although there is no evidence of excessive haemolysis.

*Erythrocytic Inclusions in Atebrine Poisoning.* It was shown by Mushett and Siegel (1946) that the administration of quinacrine hydrochloride in massive doses to a variety of animal species resulted in an anaemia, and the occurrence of inclusion bodies, staining dark blue with Wright's stain, within erythrocytes and lymphocytes. We have confirmed these findings in rats and mice, but the bodies failed to stain for iron.

*Siderotic Granules of Siderocytes.* Doniach, Grüneberg and Pearson (1943), employing the prussian blue reaction, described the occurrence of iron-positive erythrocytic inclusions in the peripheral blood of five patients following splenectomy. Two were cases of traumatic rupture of the spleen, one was of thrombocytopenic purpura, one of splenic anaemia, and the fifth was a case of biliary cirrhosis. They also found similar inclusions in the peripheral blood of two cases of chronic uraemia. It may be noted that Pappenheimer's bodies have been demonstrated by us in the peripheral blood of examples of the first two conditions after splenectomy, and in uraemia. Grüneberg (1941a & b), with the same technique, had demonstrated siderotic granules in the peripheral blood of normal man, rat, and mouse embryos, and (1942) in the peripheral blood of mice showing a genetic abnormality (flexed tail and belly spot) associated with anaemia. In none of the above communications do the writers mention the staining reaction of the siderotic material with Romanowsky stains. Pappenheimer *et al.* (1945) found that the siderotic material of siderocytes occurring in flexed tailed mice stained blue with Giemsa, but they were not certain that they were identical with the inclusions of haemolytic anaemia because the latter were more sharply defined, stained more intensely and with a more purplish cast, were less numerous, and were more frequently diploid in form. We have shown that although the inclusion bodies in haemolytic anaemia stain usually purplish with Leishman they or their components not infrequently stain blue, that they may not always be sharply defined and that they may show a remarkable variation in shape and size. In view of these considerations it would appear that the siderotic granules described by Grüneberg (1941a & b, 1942) and by Doniach *et al.* (1943) are probably fundamentally similar to the Pappenheimer bodies.

Case (1943, 1945, 1946) described the occurrence of siderocytes in various haematological disorders, and also in citrated stored blood, and in citrated blood treated with acetyl phenyl hydrazine, with lead nitrate, and with other chemical agents. He employed as an iron stain potassium ferricyanide and hydrochloric acid after initial treatment of the films for two hours with a strong solution of ammonium sulphide, but later superseded this by the potassium thiocyanate and  $\alpha\alpha$  dipyridyl technique (Case, 1944). Employing both techniques we have repeated the observations on stored citrated blood, and on citrated blood treated

with acetyl phenyl hydrazine, and with lead nitrate, as well as on blood films from various haematological conditions. The siderotic granules in such preparations were small and uniform in size. Extracellular forms were frequent. We are satisfied that these granules do not stain with Leishman or with pyronin, and that they do not give an iron reaction with potassium ferrocyanide and hydrochloric acid. While Case in his publications makes no reference to staining with Romanowsky stains, Pappenheimer *et al.* (1945) quote a personal communication from Case stating that he was not satisfied that his siderotic material stained with Romanowsky stains.

Blood films from some of our cases of haemolytic anaemia when treated with potassium thiocyanate and  $\alpha\alpha$  dipyridyl revealed numerous small purplish granules both within the erythrocytes and lying free. These granules were presumably the same as these described by Case, since they were morphologically similar to those seen in citrated blood treated with acetyl phenyl hydrazine or lead nitrate. They appeared, however, to be distinct from the Pappenheimer bodies, since the latter could be observed within the red cells as refractile unstained bodies in the same frequency as in comparable blood films stained with Leishman. The Case's granules occurred indiscriminately both in erythrocytes containing Pappenheimer bodies and in otherwise normal cells. With potassium ferricyanide and hydrochloric acid subsequent to treatment with ammonium sulphide solution a similar result was obtained except that the Pappenheimer bodies also stained. In this connection it should be noted that in the personal communication from Case to Pappenheimer already referred to, he stated that the siderotic granules were not identical with the inclusion bodies present in Pappenheimer's preparations although they often occurred in the same cells. Case (1946) described the extrusion of the siderotic granules and their phagocytosis by polymorphonuclear leucocytes, but this was never observed in connection with Pappenheimer bodies. The siderocyte levels reported by Case (1945) bear, in the main, little relationship to the incidence of inclusions studied by Pappenheimer *et al.* (1945) or by ourselves. Although Case (1945) did not state the number of preparations in which the potassium ferricyanide and hydrochloric acid technique was employed, we would emphasize that with this method Pappenheimer bodies would also stain and would presumably be included as 'siderotic granules.'

With the reservations just mentioned, we are of the opinion that the siderotic granules of siderocytes described by Case are distinct from the Pappenheimer bodies. In view of the conception of Case (1943) that siderocytes are ageing erythrocytes, it should be noted that the Pappenheimer bodies may occur in erythrocyte precursors and reticulocytes as well as in mature erythrocytes.

*Punctate Basophilia.* Reference has been made to the occurrence of multiple small inclusions in a number of the cases studied by us. Since the appearance of the red cells containing such multiple inclusions, in films stained with Leishman or with Pappenheim's pyronin methyl green, was often indistinguishable from that seen in punctate basophilia or basophilic stippling, it appeared desirable to investigate whether the inclusions were related to, or identical with, the basophilic granules of stippling as seen in lead poisoning.

This study is not yet complete but it is appropriate to summarize our present findings here. Basophilic stippling has been studied in the peripheral blood and bone marrow of human cases of lead intoxication and of guinea-pigs poisoned with lead acetate. The staining reactions of the granules in the stippled cells were apparently similar to those of the Pappenheimer bodies. The coarser granules stained with Leishman a purplish-blue almost black colour, to blue, and frequently gave a positive reaction with potassium ferrocyanide and hydrochloric acid. The smaller granules gave a more definitely blue reaction with Leishman, but the iron reaction was much less constant, being usually negative in very small and ill-defined granules. The centrifuged deposit obtained from lysed red cells of experimental guinea pigs showing coarse stippling in the peripheral blood revealed numerous granules which stained with Leishman and with iron stains. It may also be noted here that cells showing coarse stippling frequently displayed apparent alteration in haemoglobin content (Plate 7) similar to that described in cells containing large and numerous Pappenheimer bodies, and that the development of coarse stippling in the normoblasts of the bone marrow was morphologically identical with that of the Pappenheimer bodies seen in the haemolytic anaemias and other conditions.

In view of these observations it would seem that the granules of basophilic stippling may be fundamentally similar to the Pappenheimer bodies.

#### *The Nature of the Inclusion Bodies.*

The possibility that the inclusion bodies are infective in origin has been discussed at length by Pappenheimer *et al.* (1945). Their widespread distribution in a diversity of conditions and the considerable variation in their morphology, in our opinion, render it unlikely that they are parasites or that they are the manifestations of an infective process.

It would seem more likely that the bodies are the result of defective haemoglobinization. Among the evidence we believe to support this view the following findings may be reiterated. The inclusion bodies appear in red cell precursors coincidentally with the earliest evidence of haemoglobinization. In such polychrome normoblasts the inclusions are confined to the close proximity of the nucleus where haemoglobinization is

commonly believed to begin. When multiple inclusions are present within individual erythrocytes, the number of inclusions within the normoblasts increases with the degree of haemoglobination up to, but not beyond, the late polychrome stage. Moreover, when the inclusion bodies are multiple and large in size, defective haemoglobination is constantly present, the haemoglobin content of the cell being reduced to an extent proportional to the number and size of the inclusion bodies present.

It is manifest that the inclusions do not result merely from an aggregation of haemosiderin, not only because of their staining with Leishman and other stains, but also because exposure to alkali results in the removal of the iron from the inclusions leaving their staining reaction with Romanowsky stains unimpaired. Consequently it may be inferred that a second moiety which fails to give an iron reaction enters into the constitution of the inclusions.

Pappenheimer *et al.* (1945) attempted to isolate ferritin from their inclusion bodies, but with negative results. It appeared to us worth while repeating this attempt because of the observation of Granick and Hahn (1944) that the iron fraction of ferritin may be separated from the protein apoferritin by exposure to alkali, a treatment which will also result in the removal of the iron from the Pappenheimer bodies. This possibility seemed to be strengthened by our observations that material having similar staining reactions to the inclusion bodies was to be found in tissues where ferritin has been demonstrated, namely, bone marrow, liver, spleen, and the duodenal mucosa of guinea pigs after feeding with ferrous sulphate (Hahn, Granick, Bale & Michaelis, 1943; Granick, 1946). In order to test this hypothesis attempts were made to isolate crystals of ferritin from centrifuged deposits from lysed blood rich in inclusions, using the method of Granick (1942). The results were negative. It must be emphasised that this does not exclude the 'non-crystallisable fraction' of Granick (1942) which is capable of regenerating ferritin from the iron-free protein apoferritin.

Studies by a number of authors (Cesaris-Demel, 1907; Hawes, 1909; Keys, 1921, 1924; Whitby & Britton, 1933) have indicated that stippled erythrocytes and reticulocytes are closely related. Since the granules in stippled cells may be similar to, if not identical with, the inclusion bodies, it would seem reasonable to suggest that the iron-free moiety may be composed of a substance similar to that of reticulum material. In consideration of the belief that protoporphyrin enters into the constitution of the reticulum of reticulocytes (Watson, 1937), an attempt was made to isolate protoporphyrin from the inclusions. For this purpose a deposit rich in the bodies was obtained from lysed blood and subjected to the method of Van den Bergh (1938) for the extraction of protoporphyrin. No fluorescence of the final hydrochloric acid extract was

detected. By the courtesy of Professor J. H. Gaddum, films of blood containing a high proportion of cells with inclusions, and also films of a deposit of lysed blood before and after treatment with alkali, were examined by fluorescent microscopy. No fluorescence was detected. These observations cannot be regarded as conclusive, but as far as they go they fail to provide support for the suggestion that the inclusion material contains protoporphyrin.

*The Significance of the Inclusion Bodies.*

(1) *Acquired Haemolytic Anaemia.* Comparison of bone marrow films from our cases of acquired haemolytic anaemia with those from the other haematological conditions studied reveals a very significant increase in the incidence of affected normoblasts in the former group. The lowest incidence recorded in marrow films in the cases of acquired haemolytic anaemia in a haemolytic phase was 25 per cent, and the highest 85 per cent. Of eighteen normal marrows examined, seven were positive but inclusion containing red cells were found only on prolonged search. In the other diverse haematological conditions investigated the maximum incidence of affected normoblasts was 8 per cent.

It has already been noted that in the acquired haemolytic anaemias the incidence of affected normoblasts in the sternal marrow was related to the activity of the haemolytic process. When the haemolysis was severe (Cases 1, 2, 4, 5 & 6) affected cells were numerous, whereas with less severe haemolysis (Cases 3 & 7) they were significantly less numerous. From the material available it would also appear in general that the frequency of affected normoblasts parallels not only the severity of the haemolytic process but also the frequency of affected erythrocytes subsequently seen in the peripheral blood after splenectomy. Sternal marrow films made while patients were in a phase of spontaneous remission (Cases 3 & 4) showed only scanty inclusions in contrast to films made while the patients were in a haemolytic phase.

In the peripheral blood before splenectomy the incidence of inclusions was variable, the highest figure being 11 per cent in Case 1 during a haemolytic crisis. It should be noted that evidence of excessive haemolysis was always present when inclusions were seen in the peripheral blood prior to splenectomy.

Splenectomy was in all cases (Cases 1, 2, 3, 5, 6 & 7) followed by remission of the haemolytic process of varying degree and duration. It is significant that in those cases in which the number of affected normoblasts in the marrow was very high (Cases 1, 2, 5 & 6) the subsequent increase in the erythrocyte counts was accompanied by a striking rise in the percentage of erythrocytes containing inclusions. Furthermore, in those cases where repeated counts were feasible (Cases 1 & 2) it is

evident that the rise in the total red cell count, for a variable period after splenectomy, can be accounted for entirely by the increase in the absolute number of inclusion-containing erythrocytes, since the number of unaffected cells showed little change (Figs. 1 & 2).

In explanation of these observations it is suggested that the dramatic rise in the incidence of affected erythrocytes, in parallel with the rise in the total red cell count immediately following splenectomy, is due to the removal of a mechanism which is concerned with the suppression of the entry of the affected erythrocytes into the peripheral blood, or with their elimination therefrom. Since normoblasts containing the inclusions were equally abundant in the marrow both before and after splenectomy, it seems probable that the spleen is concerned with the removal of the affected erythrocytes from the peripheral blood rather than with the suppression of their formation.

An obvious corollary of this theory is that a red cell containing inclusion bodies is a defective cell fated to rapid elimination from the circulation, a process in which the spleen plays a major part. According to this view, abnormal erythropoiesis resulting in the production of inclusion-containing cells may constitute a major aetiological factor in the cases of haemolytic anaemia under consideration.

If this conception is correct, the occurrence of a spontaneous remission in the haemolytic process should be accompanied by the disappearance, or a marked decrease in the numbers, of the affected cells both in the peripheral blood and the bone marrow. This has in fact been observed in certain of our cases of haemolytic anaemia. Thus, in Case 4, a remission with a substantial rise in the red cell count was accompanied by the disappearance of the inclusions from the peripheral blood, and a marked diminution in their number in the sternal marrow, whereas during the height of the haemolytic process inclusion bodies had been found in 9 per cent of the red cells in the peripheral blood, and to be abundant in the marrow. Similar findings in the peripheral blood were recorded in Case 2 during a phase of secondary spontaneous remission some months after splenectomy. In this case splenectomy was followed by clinical and haematological remission, the increase in the total red cell count being apparently accounted for by inclusion-containing cells as previously described. Three months later, however, manifestations of haemolysis recurred and the red cell count fell, largely at the expense of cells containing inclusions, which, nevertheless, still constituted some 40 per cent of the total. After two months the signs of excessive haemolysis disappeared and the red cell count rose to beyond the original level, but this time the number of red cells containing inclusion bodies underwent a marked fall to below 2 per cent (Fig. 2), suggesting a remission in the underlying pathological process responsible for their formation. Unfortunately it was not feasible to perform another sternal puncture in this patient.



In certain of the cases studied by us while the spleen was intact, an appreciable proportion of red cells in the peripheral blood contained inclusions. It is perhaps significant that in these cases the inclusion bodies were invariably small; large multiple inclusions were seen in the peripheral blood only after splenectomy. This would suggest that the susceptibility of the affected red cells to removal from the circulation was related to their total content of the inclusion material.

Presumably the recurrence of haemolytic activity after splenectomy seen in certain cases was due to the agency of residual reticulo-endothelial tissue, which, however, was less effective than the spleen in eliminating inclusion-containing cells. In this connection it may be noted that the recurrence of haemolysis, subsequent to splenectomy, was severe in Cases 2 and 6, whereas in Case 1 it was mild, yet the total number of affected erythrocytes was approximately the same in all three cases preceding the recurrence of haemolysis. There was this difference, however, in Case 1 the majority of affected cells contained solitary inclusions and these were small; whereas in Cases 2 and 6 multiple and large inclusions were the rule (Plate 3).

The late increase in the proportion of affected cells in Case 6 subsequent to splenectomy is difficult to explain in view of the accompanying fall in the red cell count. Possibly it is due to an exacerbation of the pathological process responsible for the formation of the inclusions.

Regarding the mechanism of the removal of the affected cells by the spleen a possible explanation is suggested by the work of Elliott and Libet (1944), who showed that iron salts, and also ferritin, can catalyse the oxidation of phospholipids. These observers consequently anticipated that such substances would have a significant effect on the permeability and other functions of cell surfaces, since phospholipids are prominent constituents thereof. It would seem reasonable to assume that the inclusion material may be capable of this catalysis, the resulting effect on the red cell being to render it unduly susceptible to destruction within the splenic sinusoids.

Reference has already been made to the occurrence of inclusions and masses of inclusion-like material within reticulo-endothelial cells. It must remain an open question whether they result from erythrophagocytosis or from phagocytosis of the inclusion material subsequent to the destruction of the corpuscles elsewhere. There is also the possibility that a certain amount of inclusion material may originate outside the red cells. Support for this possibility is provided by the observation in many of our preparations of the intimate association of groups of inclusion-containing red cells, in varying stages of haemoglobination, with masses of material having the same staining reactions as the inclusion bodies.

It may be interpolated here that, although we have presented our cases of acquired haemolytic anaemia as a group, we do not wish it to be inferred that we regard them as examples necessarily of a single pathological entity. The term idiopathic acquired haemolytic anaemia is employed merely as a convenient provisional designation. It is appreciated that this somewhat vaguely-defined syndrome may embrace a number of fundamentally dissimilar pathological states. The fact that the high incidence of inclusion bodies in the bone marrow, and in the peripheral blood after splenectomy, was a phenomenon common to all the cases available to us may, of course, have been fortuitous. More extensive observations are obviously necessary before it can be asserted that this phenomenon is a constant feature in patients suffering from idiopathic acquired haemolytic anaemia.

(2) *Congenital Acholuric Jaundice.* The data concerning the incidence of Pappenheimer bodies in this condition are too scanty to warrant definite conclusions being drawn, but it will be seen that the available figures are very different from those obtained in the cases of acquired haemolytic anaemia in respect of the frequency of inclusions both in the sternal marrow and in the peripheral blood after splenectomy. Although the significance of the inclusion bodies is unknown, it is tempting to interpret this difference as indicating a fundamental dissimilarity between the two types of haemolytic anaemia. Serological evidence for the existence of such a dissimilarity has recently been provided by Loutit and Mollison (1946).

(3) *Other Haematological Conditions.* From consideration of the other haematological conditions studied it is possible to classify them into groups, namely, those associated with increased erythropoietic activity and the appearance of immature cells in the peripheral blood, *e.g.*, erythroblastosis foetalis; those associated with toxæmia, *e.g.*, uraemia, and chronic infection; and those associated with neoplastic conditions, *e.g.*, carcinoma and leukaemia. It should be noted that in the first group the incidence of inclusion bodies seems to be correlated with the intensity of the erythropoietic activity, since the bodies appear to attain their maximum incidence during the phase of reticulocyte response. With diminution in the intensity of this activity the incidence of inclusion-containing red cells falls. In lead poisoning we have found Pappenheimer bodies in a high proportion of normoblasts in the sternal marrow. This is being studied and will form the subject of a subsequent publication.

The significance of the Pappenheimer bodies in these miscellaneous conditions obviously requires further study. In view of the paucity of relevant data at our disposal we do not propose to discuss this question further here.

## SUMMARY.

1. Bodies resembling those described by Pappenheimer *et al.* (1945) have been studied in a variety of haematological conditions. They occur within erythrocytes and their haemoglobinated precursors, both in the peripheral blood and in the bone marrow as revealed by sternal puncture.
2. The morphology and staining reactions of the inclusion bodies have been described and illustrated. They give a positive iron reaction and stain with Leishman, methyl blue, pyronin, and a number of other stains, but fail to do so with specific nuclear stains, namely, haematoxylin and methyl green, and they do not give the Feulgen reaction.
3. A series of seven cases of acquired idiopathic haemolytic anaemia has been described with special reference to the incidence of inclusion bodies.\* Before splenectomy, which was performed in six of the cases, these bodies were numerous in the sternal marrow but relatively scanty in the peripheral blood. Shortly after splenectomy the incidence in the bone marrow was unchanged in the four cases in which it was examined, but in all cases the number of red cells containing inclusion bodies in the peripheral blood underwent a dramatic increase which was commensurate with the rise in the total red cell count. It is consequently suggested that the red cells containing the inclusion bodies may normally be removed by the spleen, and that the mechanism responsible for the occurrence of the inclusion bodies may constitute a major aetiological factor in the production of the type of acquired haemolytic anaemia under consideration.
4. Similar inclusion bodies have been found in the peripheral blood and sternal marrow in a variety of haematological disorders. Their incidence never approached the high figures seen in the cases of acquired haemolytic anaemia.
5. The relationship of the inclusion bodies to other erythrocytic inclusions has been discussed. They differ from the siderotic granules of siderocytes described by Case, but appear to be similar to those described by Grüneberg in mice with a genetic abnormality, and to be related to the basophilic stippling of lead poisoning.
6. The nature of the inclusion bodies is unknown. It is suggested that they develop as the result of interference with haemoglobin anabolism.

\* A further case recently seen is described in the Appendix.

## ACKNOWLEDGMENT.

It is a pleasure to record our indebtedness to various friends and colleagues for their help. Professor L. S. P. Davidson and Dr. J. N. M. Chalmers gave us the clinical data and haematological preparations of patients under their care. Dr. J. Bryant and A. P. Agnew referred patients to us. Drs. J. V. Dacie, H. W. Fullerton and E. S. Horgan sent us haematological material. Professor J. W. S. Blacklock granted us facilities in his department and permitted Mr. Donald Hay to give valuable technical assistance. Professor J. G. Gaddum gave us facilities for fluorescent microscopy. Dr. S. L. Tompsett placed his expert biochemical knowledge at our disposal, and Professor J. A. G. Burton provided ideal surgical co-operation.

## REFERENCES.

- Brookfield, R. W. (1928). *J. Path. Bact.* **31**: 227.  
 Case, R. A. M. (1943). *Nature, Lond.* **152**: 599.  
 Case, R. A. M. (1944). *J. Physiol.* **103**: 2, 14P.  
 Case, R. A. M. (1945). *J. Path. Bact.* **57**: 221.  
 Case, R. A. M. (1946). *Proc. roy. Soc. B.* **133**: 235.  
 Cesaris-Demel, A. (1907). *Fol. Haematol.* **4**: Suppl. 1.  
 Davidson, L. S. P. Davis, L. J. & Innes, J. (1942). *Quart. J. Med. (N.S.)*. **11**: 19.  
 Davis, L. J. (1944). *Edinburgh med. J.* **51**: 70.  
 Doniach, I. Grüneberg, H. & Pearson, J. E. G. (1943). *J. Path. Bact.* **55**: 23.  
 Elliott, K. A. C. & Libet, B. (1944). *J. biol. Chem.* **152**: 617.  
 Granick, S. (1942). *J. biol. Chem.* **146**: 451.  
 Granick, S. & Hahn, P. F. (1944). *J. biol. Chem.* **155**: 661.  
 Granick, S. (1946). *J. biol. Chem.* **164**: 737.  
 Grüneberg, H. (1941). *Nature, Lond.* **148**: 114.  
 Grüneberg, H. (1941). *Nature, Lond.* **148**: 469.  
 Grüneberg, H. (1942). *J. Genetics.* **44**: 246.  
 Hahn, P. F. Granick, S. Bale, W. F. & Michaelis, L. (1943). *J. biol. Chem.* **150**: 407.  
 Hawes, J. B. (1909). *Boston med. surg. J.* **161**: 493.  
 Isaacs, R. (1924). *Anat. Record.* **29**: 4, 299.  
 Key, J. A. (1921). *Arch. intern. Med.* **28**: 511.  
 Key, J. A. (1924). *Amer. J. Physiol.* **70**: 86.  
 Loutit, J. F. & Mollison, P. L. (1946). *J. Path. Bact.* **58**: 711.  
 Mushett, C. W. & Siegel, H. (1946). *Blood.* **1**: 537.  
 Pappenheimer, A. M. Thompson, W. P. Parker, D. D. & Smith, K. E. (1945). *Quart. J. Med. (N.S.)*. **14**: 75.  
 Pappenheimer, A. M. (1946). *Personal communication.*  
 Van den Bergh, A. A. H. & Hyman, A. J. (1928). *Deutsch. med. Wchnschr.* **54**: 1492.  
 Watson, C. J. & Clarke, W. O. (1937). *Proc. Soc. exper. Biol. Med.* **36**: 65.  
 Wenyon, C. M. & Low, G. C. (1914). *J. trop. Med. Hyg.* **8**: 369.  
 Whitby, L. E. H. & Britton, C. J. C. (1933). *Lancet.* **1**: 1173.  
 Wintrobe, M. M. Follis, R. H. Miller, M. H. Stein, H. J. Alcayaga, R. Humphreys, S. Suksta, A. & Cartwright, G. E. (1943). *Johns Hopkins Hosp. Bull.* **72**: 1.

## APPENDIX.

## CASE HISTORIES

*CASE No. 1.* Mrs. A., a housewife aged 53, had enjoyed good health until 1941 when she began to suffer from intermittent attacks of nausea and vomiting. In June, 1944, during such an attack, she became jaundiced for the first time. Since then she had experienced several bouts of jaundice, variable in duration and severity. After the first attack of jaundice she had become increasingly dyspnoeic on exertion, easily fatigued, and had suffered from palpitation. In October, 1945, the dyspnoea became worse and her feet and ankles became swollen. She came under our care on 19/10/45.

*Personal and family history.* The patient's earlier health had been satisfactory except for some dyspepsia twenty years previously. There was no evidence of exposure to toxic substances or of taking drugs. The patient's family history was thoroughly investigated but no history of jaundice or of anaemia was elicited in respect of grandparents, parents, aunts, brother, sisters, or children, with the exception that her maternal grandmother died of 'jaundice' at an advanced age.

*Clinical findings.* The patient was a sparely built woman with signs of moderately severe jaundice. The mucous membranes were pale. Oedema was present in both legs below the knees. The lower margin of the liver was palpable 4 cm. below the costal margin, and the lower pole of the spleen 8 cm. below the left costal margin. No enlargement of the lymph glands was noted. The temperature was not elevated. The stools were dark brown.

*Laboratory findings.* R.B.C.: 1,700,000; Hb.: 45%; C.I.: 1.3; M.C.V.: 95 cu.  $\mu$ ; W.B.C.: 7,600; reticulocytes: 27%. The peripheral blood films showed marked anisocytosis and polychromasia; 8% of the red cells were microspherocytes. Red cell fragility in hypotonic saline was increased, 15% haemolysis being present in 0.60% saline and 80% in 0.42% saline. Sternal marrow: hypercellular with normoblastic erythropoiesis. The plasma bilirubin was reported 2.5 mgm.%. The Wassermann reaction was negative. The urine contained excessive urobilinogen but no bilirubin. Radiological examination revealed no skeletal abnormalities.

*Progress.* During the next month the jaundice persisted and the reticulocyte count remained at a high level. The red cell count was 1,590,000 on 3/11/45 when blood transfusions totalling 2½ pints were given. On 15/11/45 the patient became pyrexial and the red cell count had fallen to 1,190,000. Further transfusions of 3 pints were given and splenectomy decided upon. This operation was performed by Professor J. A. G. Burton on 18/11/45 when a spleen weighing 1200 grams was removed. Subsequently the patient's general and haematological condition showed a progressive and striking improvement. On 18/1/46 no jaundice was apparent; the lower liver border was just palpable; the red cell count was 4,380,000; the haemoglobin 86%; the reticulocytes less than 1%; the plasma bilirubin 0.3 mgm.%, although a trace of urobilinogen was present in the urine. Microspherocytes were still present, however, and the red cell fragility in hypotonic saline remained increased. The patient has been kept under observation during the past 18 months and has remained subjectively well with normal red cell counts and haemoglobin levels. In May, 1946, however, the reticulocyte count had again risen to 4%, and has remained at about this level in the succeeding period of one year. The aldehyde test for urobilinogenuria, moreover, has been constantly positive. On 30/7/47 the red cell count and haemoglobin were 4,330,000 and 94% respectively with reticulocytes 4%.

*Inclusion Bodies.* Attention was first focussed on inclusions when, in a Leishman-stained blood film prepared some four weeks after splenectomy, they were noticed within approximately 50% of the erythrocytes. This led to a review of filed preparations. The total erythrocyte counts and the incidence of inclusion-containing erythrocytes are depicted in Table I and Fig. 1. Sternal marrow films obtained on 21/10/45, before splenectomy, and on 24/12/45, after splenectomy, showed inclusion bodies within the erythrocytes, the haemoglobinated and partially haemoglobinated normoblasts, and also within monocytes. Approximately 75% of the haemoglobinated normoblasts contained inclusions, both before and after splenectomy. Comparison of the marrow films obtained before splenectomy with peripheral blood films made on the same day showed that the proportion of erythrocytes containing inclusions was considerably higher in the marrow than in the peripheral blood. In sections of the spleen, inclusion bodies and masses of inclusion-like material were seen in the endothelial cells lining the sinuses.

*CASE No. 2.* Mrs. T., a housewife aged 58, had enjoyed good health until November, 1945, when she first noticed that slight exertion caused breathlessness and praecordial pain, and that her complexion was becoming sallow. These symptoms rapidly became more severe and she soon became frankly jaundiced. She was admitted to hospital under our care on 15/12/45.

*Personal and family history.* The patient had previously enjoyed exceptionally good health, and had given birth to nine healthy children. There was no history of exposure to toxic substances or of taking drugs. No history suggestive of jaundice or anaemia could be discovered in respect of her grandparents, parents, sisters, brothers or children.

*Clinical findings.* The patient was an obese woman with signs of jaundice and severe anaemia. No other significant abnormalities were detected, and the liver, spleen and lymph glands were not enlarged clinically. Pyrexia was not present. The stools were dark brown.

*Laboratory findings.* R.B.C. : 1,100,000 ; Hb. : 30% ; C.I. : 1.36 ; W.B.C. : 9,200 ; reticulocytes : 62%. The blood film showed marked anisocytosis with polychromasia and numerous normoblasts. Approximately 10% of the red cells were microspherocytes. The red cell fragility in hypotonic saline was increased, haemolysis commencing in 0.56% saline and being complete in 0.44%. Sternal marrow : hypercellular with normoblastic erythropoiesis. The icterus index was 40, and the urine gave a strong positive test for urobilinogen, no bilirubin was present. The Wassermann reaction was negative. Radiological examination showed enlargement of the spleen but no skeletal abnormalities. A test meal revealed a histamine-fast achlorhydria.

*Progress.* The patient received a transfusion of 2 pints of blood shortly after admission to hospital, which resulted in some symptomatic improvement and a rise in the red cell count to 2,010,000. During the next month the red cell count gradually rose to 2,460,000, the reticulocyte count ranged from 7% to 16%, and the intensity of the jaundice fluctuated. Two more transfusions were given but the patient's condition remained much the same, and on 20/3/46 she was discharged from hospital at her own request, having declined to consider the question of splenectomy. At this time, the red cell count was 2,760,000 with 10.5% reticulocytes. She was readmitted to hospital on 4/4/46 severely anaemic and jaundiced following a haemolytic crisis. The red cell count was 1,220,000, the haemoglobin 33%, normoblasts again being prominent in blood films. Blood transfusions were given and splenectomy was performed by Professor J. A. G. Burton on 12/4/46. This operation

was followed by a marked improvement in the patient's general condition. The jaundice rapidly cleared, there was a progressive rise in the red cell count and a fall in the reticulocyte count and plasma bilirubin. She was discharged from hospital on 16/5/46 when the red cell count was 4,110,000, the haemoglobin 90% and the reticulocytes less than 1%. The red cell fragility in hypotonic saline was still increased. The patient has since been kept under observation as an out-patient. She remained well for a period of six weeks, but on reporting in July, 1946, she complained of a return of fatigue, and dyspnoea on exertion. Since the beginning of June there had been a progressive fall in the red cell count and an increase in the reticulocyte count. On 6/8/46 the red cell count had fallen to 2,300,000, the haemoglobin to 62%, the reticulocyte count had risen to 14% and the plasma bilirubin to 2 mgms.%. The patient refused readmission to hospital. She reported again on 12/9/46 when a remarkable spontaneous improvement was evident. She felt well, her red cells had risen to 4,100,000, her haemoglobin to 90% and the reticulocyte count was less than 1%. The urine no longer contained demonstrable urobilinogen. During the succeeding period of observation this improvement has been maintained. On 9/3/47 the red cell count and haemoglobin were 5,100,000 and 105% respectively with reticulocytes less than 1%.

*Inclusion bodies.* The total erythrocyte counts and the incidence of inclusion-containing erythrocytes are shown in Table 2 and Fig. 2. Sternal puncture, performed on two occasions before splenectomy (15/12/45 and 7/4/46) showed inclusion bodies in haemoglobinated and partially haemoglobinated members of the red cell series and in monocytes and reticulum cells. Some 70% of the haemoglobinated normoblasts contained inclusions on both occasions. It was evident that the proportion of erythrocytes containing inclusions was considerably higher in the marrow films than in peripheral blood films made on the same dates. Unfortunately the patient refused further sternal puncture after splenectomy. In sections of the spleen, inclusions and inclusion-like material were demonstrable in endothelial cells lining the sinuses.

*CASE No. 3.* Mrs. K., a housewife aged 33, enjoyed good health until 1943, when she had an attack of jaundice of a week's duration. In January, 1946, she developed a similar attack after the birth of a healthy first child. In April, 1946, the symptoms recurred and she was admitted to another hospital where the spleen was found to be enlarged and a tentative diagnosis of haemolytic anaemia was made. During the ensuing month her red cell count remained around 3,000,000 with a colour index of unity and a reticulocyte count fluctuating between 5% and 10%. The icterus index ranged from 17 to 23, and urobilinogenuria was constantly present. The gall bladder function was normal. Injections of liver extract were given with some apparent improvement in the patient's condition. With a view to further investigation of her condition she came under our care on 30/5/46.

*Personal and family history.* The patient's previous health had been excellent and there was no history of the taking of drugs or of exposure to toxic substances. Her father, mother, and three brothers were alive and well, a sister had died of Hodgkin's disease and a brother of diphtheria. No history of jaundice or anaemia could be obtained in respect of these or of any other relative.

*Clinical findings.* The patient was a well nourished woman with no demonstrable abnormality on physical examination. Jaundice was not evident and no enlargement of the spleen, liver or lymph glands could be detected. The stools were of normal appearance.

*Laboratory findings.* R.B.C. : 3,410,000 ; Hb. : 67% ; C.I. : 0.96 ; M.C.V. : 90 cu.  $\mu$  ; red cell fragility in hypotonic saline : normal ; reticulocytes : less than 1% ; W.B.C. : 5,400. The peripheral blood film showed no abnormalities apart from a moderate degree of anisocytosis ; no microspherocytes were seen. Sternal marrow : hypercellular with normoblastic erythropoiesis. The Wassermann reaction was negative. Urine : no urobilinogen nor bilirubin detected. Test meal : free hydrochloric acid.

*Progress.* The patient's general condition continued to improve and her red cell count to rise in the absence of specific treatment. She was discharged from hospital on 15/6/46 and observed as an out-patient. On 4/7/46 she felt unwell, complained of abdominal discomfort and was readmitted to hospital on 10/7/46. The patient was now manifestly jaundiced and the spleen was palpable 3 cms. below the costal margin. The red cell count was 4,300,000 with 82% haemoglobin. The reticulocyte count was 11%. A quantitative red cell fragility test in hypotonic saline now revealed a slight increase in fragility. During the next two weeks, although the red cell count did not fall below 3,800,000, the reticulocyte count remained elevated at around 8%, and the jaundice became more intense, the icteric index rising from 13 to 50. Splenectomy was accordingly advised and was performed by Professor J. A. G. Burton on 2/8/46. This was followed by a striking improvement in the patient's general condition. On 26/8/46 the red cell count was 4,100,000, the reticulocytes were less than 1%, the icteric index was 5 and no urobilinogen was detected in the urine. The patient has been kept under observation and has remained well, with a normal blood picture. On 3/5/47 the red cell count and haemoglobin were 4,800,000 and 98% respectively with reticulocytes less than 1%.

*Inclusion bodies.* The total erythrocyte counts and the incidence of inclusion-containing erythrocytes are shown in Table 3. Sternal punctures were performed on 3/6/46, during the phase of spontaneous remission ; on 18/7/46 during the relapse prior to splenectomy, and on 23/8/46 subsequent to splenectomy. In preparations made on all three dates inclusions were seen in erythrocytes, and normoblasts in various stages of haemoglobinisation. It is significant to note that on 3/6/46, during the phase of spontaneous remission, inclusions were found in only 2% of the haemoglobinised normoblasts, whereas on 18/7/46 and on 23/8/46 inclusions were present in approximately 25% and 16% of these cells respectively. In sections of the spleen inclusions and inclusion-like material were demonstrable in the endothelial cells lining the sinus.

*CASE No. 4.* Mrs. F., a housewife aged 45, had enjoyed good health until September, 1946, when she began to feel unduly fatigued and became jaundiced early in November. She was admitted to another hospital on 11/11/46 where haemolytic anaemia was diagnosed. At this time the patient was pyrexial, jaundiced, and anaemic, with a red cell count of 1,060,000 and a reticulocyte count of 15%. Microspherocytes were present and the red cell fragility in hypotonic saline was increased. The spleen and liver were enlarged. She received a transfusion of 2 pints of blood and was transferred to our wards on 17/11/46 by the courtesy of Dr. Joseph Bryant.

*Personal and family history.* No significant earlier medical history was obtained. The patient had never been pregnant. There was no suggestion of drug addiction or of exposure to toxic substances. No history of jaundice or anaemia in her relatives was obtained.

*Clinical findings.* The patient was a well nourished woman slightly jaundiced and apyrexial. The mucous membranes were pale. The liver edge was just palpable and the spleen was enlarged 2 cms. below the costal margin. No enlargement of the lymph glands was noted. The stools were dark brown.



*Laboratory findings.* R.B.C.: 1,600,000; Hb.: 41%; C.I.: 1.3; M.C.V.: 130 cu.  $\mu$ ; reticulocytes: 15%; W.B.C.: 8,200. The peripheral blood films showed marked anisocytosis, poikilocytosis and polychromasia, microspherocytes constituted 8% of red cells and occasional normoblasts were seen. The red cell fragility in hypotonic saline was increased, lysis commencing in 0.56% saline and being complete in 0.40%. Sternal marrow: hypercellular with normoblastic erythropoiesis. The Wassermann reaction was negative. Gastric analysis: histamine-fast achlorhydria. Urine: positive reaction for urobilinogen, no bilirubin present.

*Progress.* The icterus rapidly disappeared and the plasma bilirubin fell to within normal limits. The red cell count progressively rose and the reticulocyte count fell. On 14/12/46 three days before her discharge her red cell count was 4,000,000, the haemoglobin 77% and the reticulocyte count less than 1%. During the succeeding four months she has remained well with a normal blood picture.

*Inclusion bodies.* The erythrocyte counts and the incidence of inclusion-containing erythrocytes are indicated in Table 4. It will be seen that no inclusion bodies were seen in the peripheral blood after the first occasion. Sternal puncture was performed on 14/11/46 and on 23/11/46. On the first occasion inclusion bodies were seen in 60% of the haemoglobinated normoblasts and were also present in partially haemoglobinated normoblasts and in erythrocytes. On the second occasion, however, inclusions were present in only 3% of the haemoglobinated normoblasts. In preparations made on both dates inclusions and masses of inclusion-like material were found within monocytes and reticulum cells, and also lying free in the marrow.

*CASE No. 5.* Miss E., a clerk aged 21, had enjoyed good health until the beginning of July, 1946, when she began to feel fatigued and dyspnoeic on exertion. These symptoms increased in intensity and she was admitted to Professor I. S. P. Davidson's wards in the Royal Infirmary, Edinburgh, on 3/8/46.

*Personal and family history.* There was no significant earlier medical history nor any suggestion of exposure to toxic substances or of the taking of drugs. No history was obtained of jaundice or anaemia in the patient's relatives.

*Clinical findings.* The patient was a well-nourished woman with signs of a mild degree of jaundice. The mucous membranes were pale. Pyrexia was present and the liver and spleen were just palpable, but there was no enlargement of lymph glands.

*Laboratory findings.* R.B.C.: 1,670,000; Hb.: 38%; C.I.: 1.1; red cell fragility in hypotonic saline: increased; reticulocytes: 10%; W.B.C.: 17,000. The peripheral blood film showed anisocytosis and poikilocytosis with numerous normoblasts but no microspherocytes. Sternal marrow: hypercellular, normoblastic erythropoiesis. Urine: urobilinogen present in excess but no bilirubin.

*Progress.* Repeated transfusions of packed cells and whole blood were given, and on 20/8/46 splenectomy was performed. This was followed by improvement in the patient's general condition which was accompanied by a rise in the red cell count and a fall in the reticulocyte count. On 11/9/46 the red cell count was 3,000,000, the haemoglobin 60% and the reticulocytes less than 1%. The subsequent progress was complicated by the development of a subphrenic abscess and the red cell count and haemoglobin began to fall once more. The anaemia progressed and was associated with a persistent increase in reticulocytes and in the excretion of urobilinogen. When last heard of eight months after splenectomy, the red cell count was 1,220,000.

*Inclusion bodies.* The erythrocyte counts and the incidence of inclusion-containing erythrocytes on the dates on which preparations of the peripheral blood were examined are set out in Table 5. Sternal marrow preparations made on 3/8/46, before splenectomy, and on 18/11/46, after splenectomy, showed inclusions in red cells and normoblasts presenting evidence of haemoglobination and also in monocytes and reticulum cells. Counts of normoblasts showed that between 65% and 75% of such cells were affected. As in the previous cases comparison of marrow preparations made before and after splenectomy showed the only difference to be an increase in the number of affected erythrocytes. Sections of the spleen were not available.

*CASE No. 6.* Miss L., a clerk aged 22, enjoyed good health until 1937, when she began to suffer from headaches and dyspnoea on exertion. In 1940 she was informed that she was suffering from pernicious anaemia and was given parenteral liver extracts without improvement. The anaemia pursued a fluctuating course and she was investigated in various haematological clinics. Iron, liver extracts and repeated transfusions of whole blood and packed cells were given at intervals without improvement. On 22/9/45 she came under Professor L. S. P. Davidson's care in the Royal Infirmary, Edinburgh, where a diagnosis of acquired haemolytic anaemia was subsequently made.

*Personal and family history.* No other medical history of significance was obtained, and there was no suggestion of exposure to toxic substances. There was no family history of jaundice or anaemia.

*Clinical findings.* The patient was a well-nourished young woman with signs of an anaemia. Jaundice was not evident and no enlargement of the liver, spleen or lymph glands was noted.

*Laboratory findings.* R.B.C.: 2,200,000; Hb.: 44%; C.I.: 1; M.C.V.: 97 cu. $\mu$ ; reticulocytes: 2%. The peripheral blood showed anisocytosis and poikilocytosis with many hypochromic cells, and also a number of fully stained macrocytes; no microspherocytes were seen. Sternal marrow: hypercellular with normoblastic erythropoiesis. The serum gave an indirect Van den Bergh reaction. Gastric analysis: free hydrochloric acid.

*Progress.* Proteolysed liver and repeated transfusions were given without improvement, and on discharge from hospital on 5/11/45 the blood level was the same as that on admission. She was readmitted on 21/2/46 when the clinical and laboratory findings were substantially those of the preceding admission. On 29/4/46 splenectomy was performed, and this was followed by an improvement in the patient's general condition. On 24/5/46 the red cell count had risen to 3,130,000 and the haemoglobin to 70%, but on 11/6/46, four days before discharge from hospital, the red cell count had fallen to 2,660,000 and the haemoglobin to 60%. The last information of this patient, obtained in August, 1946, was that her condition had deteriorated and further transfusions were being considered.

*Inclusion bodies.* The total erythrocyte counts and the incidence of inclusion-containing erythrocytes are given in Table 6. Sternal marrow films obtained on 24/9/45 and on 5/3/46, before splenectomy, and on 17/5/46 after splenectomy, were available. In all preparations inclusions were seen in red cells and normoblasts in various stages of haemoglobination, and in monocytes and reticulum cells. Counts of fully haemoglobinated normoblasts in all preparations showed that between 80 and 85% of such cells contained inclusions. Comparison of marrow films before splenectomy with those made subsequent to splenectomy showed that the only difference was an increase in the number of affected erythrocytes in the latter preparations. Sections of the spleen were not available.

CASE No. 7. We are indebted to Dr. J. N. M. Chalmers for the notes and haematological preparations of this case. A male, aged 58 years, came under observation in November, 1938, for a persistent normochromic anaemia associated with hyperbilirubinaemia, increased reticyocyte count and slightly increased fragility of red cells to hypotonic saline. Gross splenomegaly was noted. There was no family history suggestive of haemolytic anaemia nor was there history of exposure to toxic substances. Splenectomy was performed on 3/4/40 and this resulted in a progressive climb in the erythrocyte count, a fall to normal of the icteric index and the reticulocyte count. The further progress of this patient is unknown.

*Inclusion bodies.* The total erythrocyte counts and the incidence of inclusion-containing erythrocytes are shown in Table 7. Marrow preparations made prior to splenectomy showed normoblastic erythropoiesis. Inclusions were seen in the red cells and in the normoblasts showing evidence of haemoglobination. While counts were impracticable on the preparations available, comparison with peripheral blood films showed that, in marrow films, the incidence of erythrocytes containing inclusions was higher than in the peripheral blood. Sternal puncture was not repeated after splenectomy and sections of the spleen were not available.

#### ADDENDUM.

Since this paper was written the following case has come under our observation. A housewife, aged 42, had a splenectomy performed in 1940 for what must be regarded from the history as acquired haemolytic anaemia. She was first seen by us on 6th Sept., 1947, when the red cell count was 4,100,000 and 64 per cent of the red cells contained Pappenheimer inclusions.

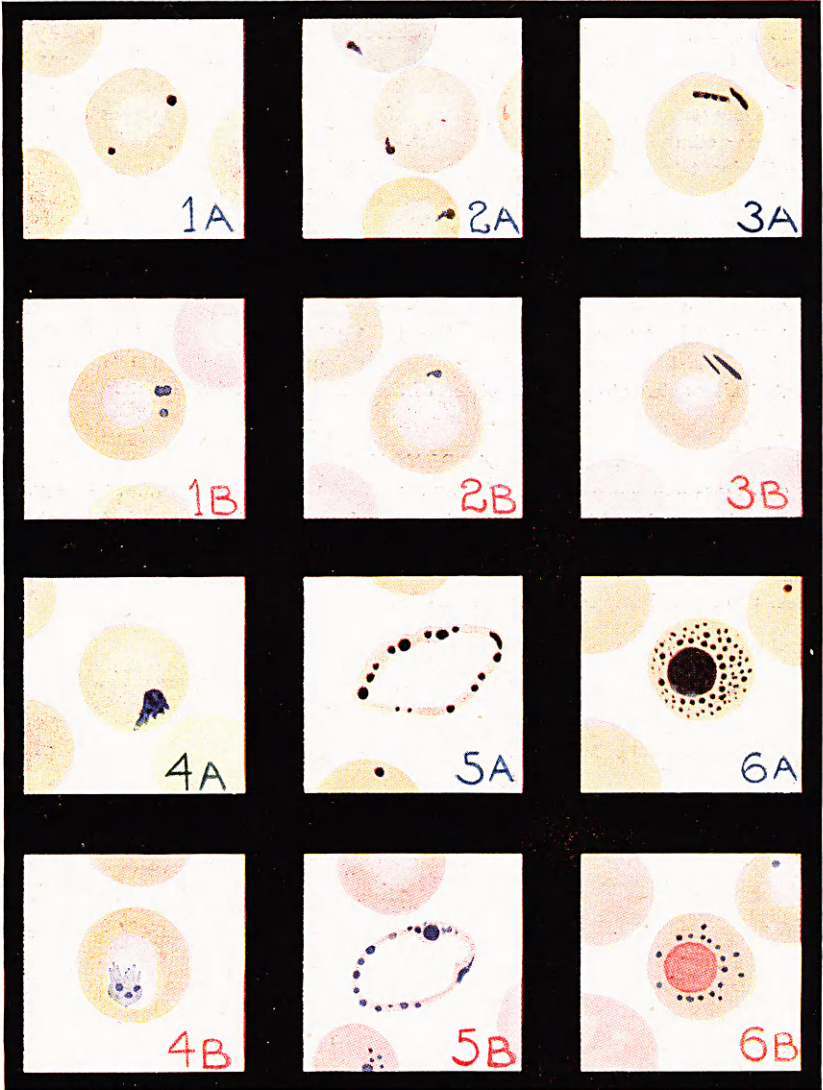


Plate 1. Various forms of Pappenheimer bodies as seen in erythrocytes and normoblasts in the peripheral blood.

A—Leishman's stain.

B—Potassium ferrocyanide and hydrochloric acid: dilute carbol fuchsin.




Plate 2. Various forms of Pappenheimer bodies as seen in sternal marrow films.  
 A—Leishman's stain.  
 B—Potassium ferrocyanide and hydrochloric acid : dilute carbol fuchsin.

Fig. 1.

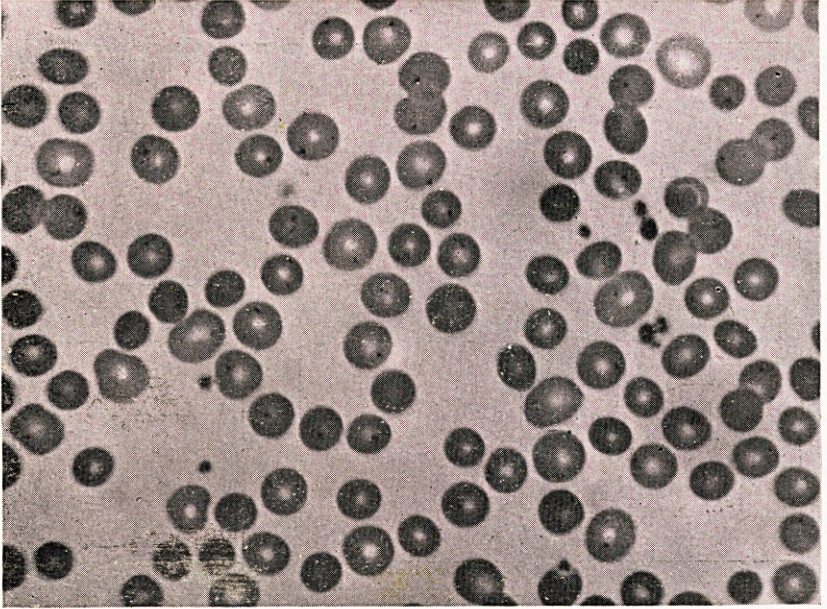


Fig. 2.

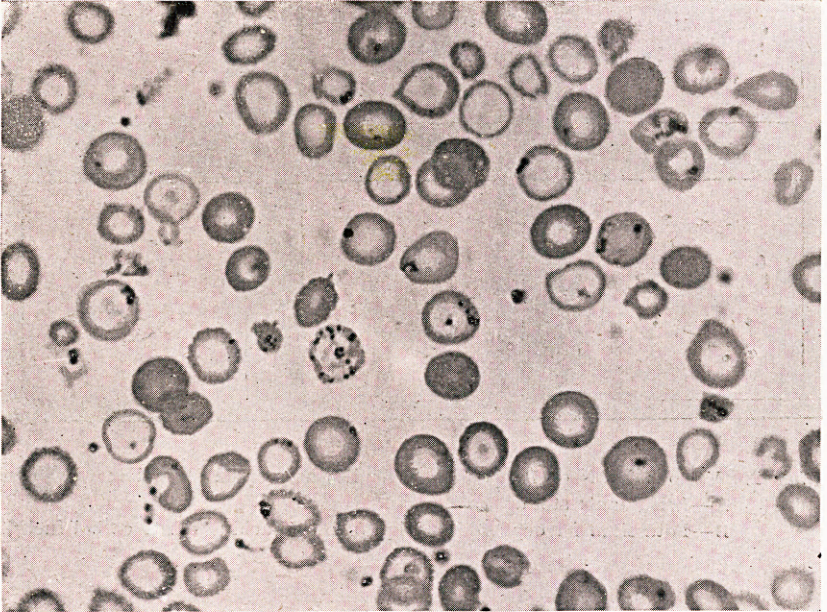


Fig. 1.

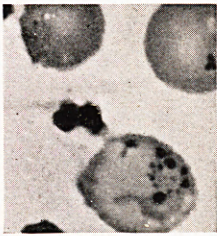


Fig. 2.

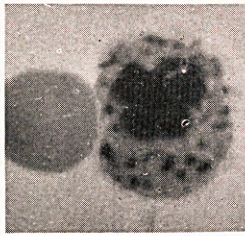


Fig. 3.

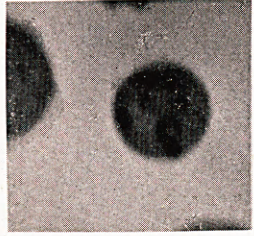


Fig. 4.

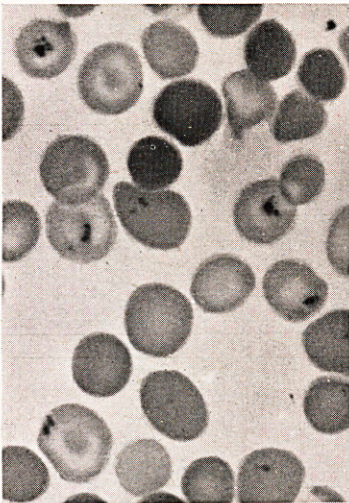


Fig. 5.

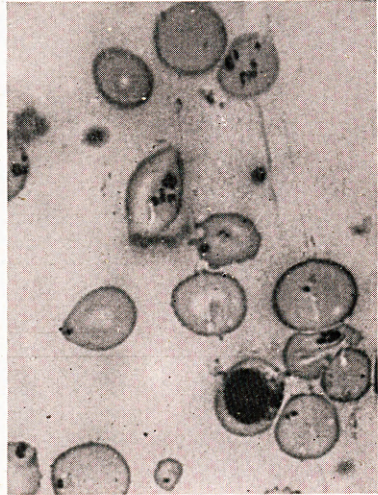


Fig. 6.

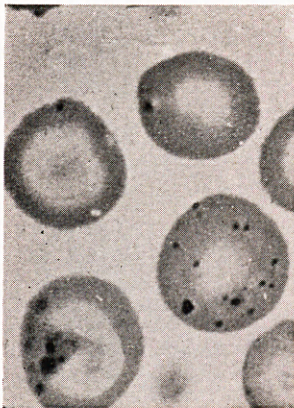


Fig. 7.

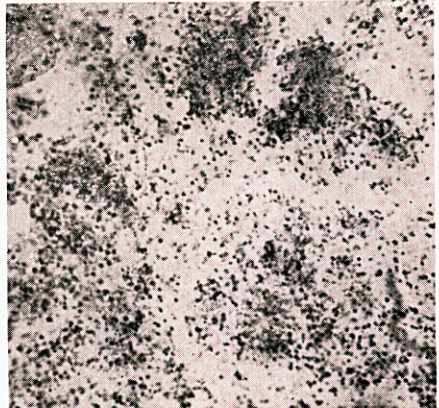


Fig. 1.

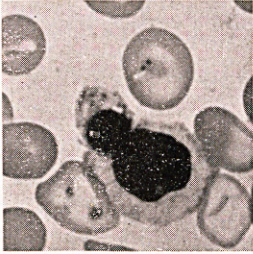

Fig. 2.

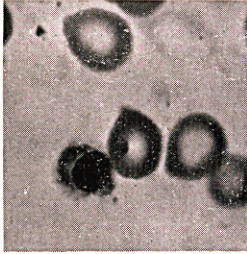

Fig. 3.

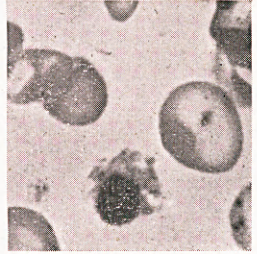


Fig. 4.

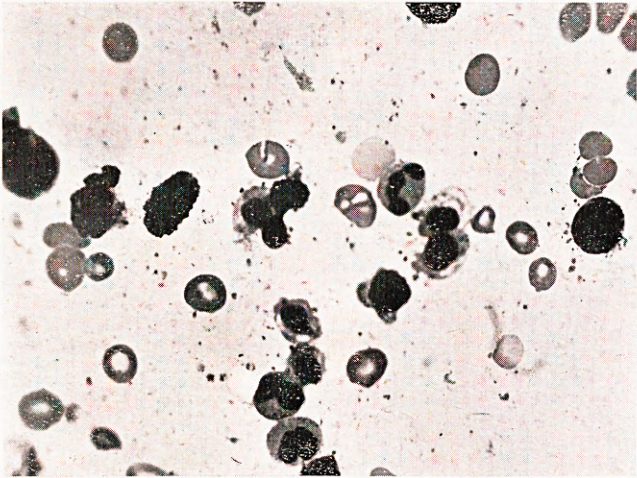


Fig. 5.

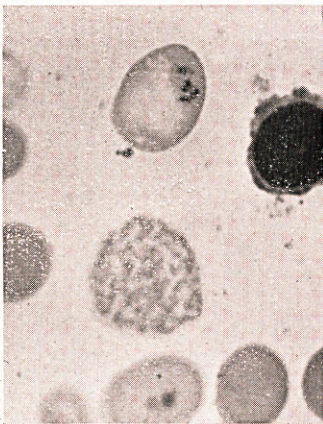


Fig. 6.

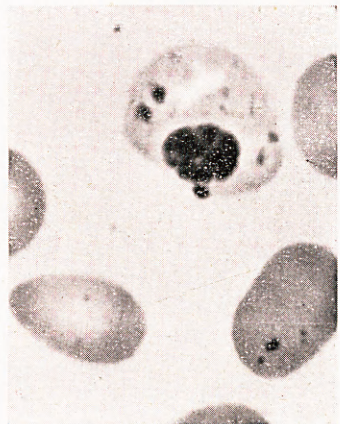




Fig. 1.

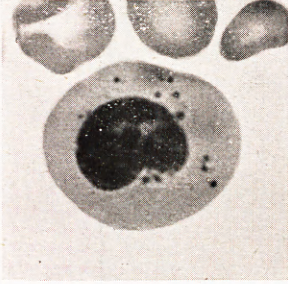


Fig. 2.

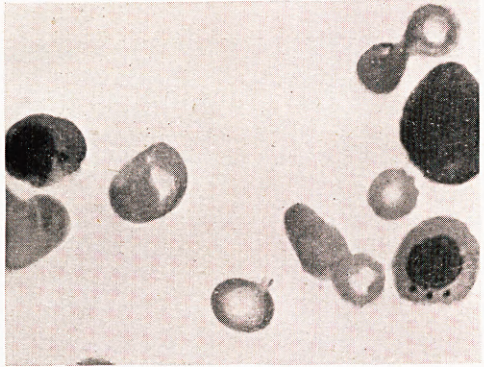


Fig. 3.

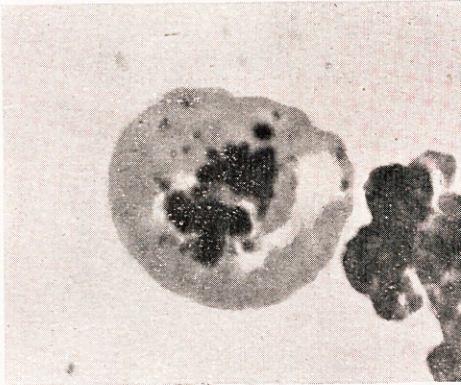


Fig. 4.

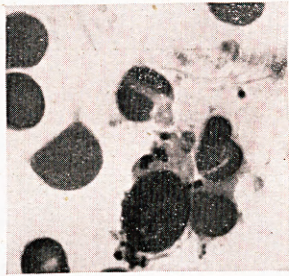


Fig. 5.

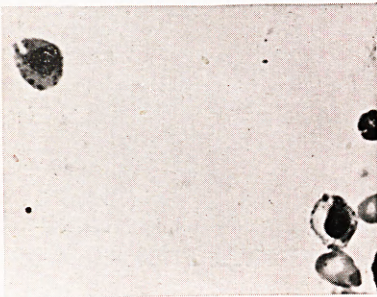


Fig. 6.

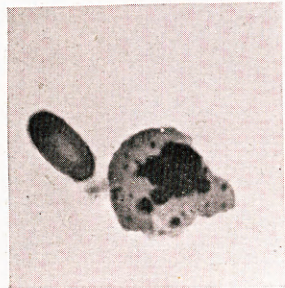


Fig. 1.

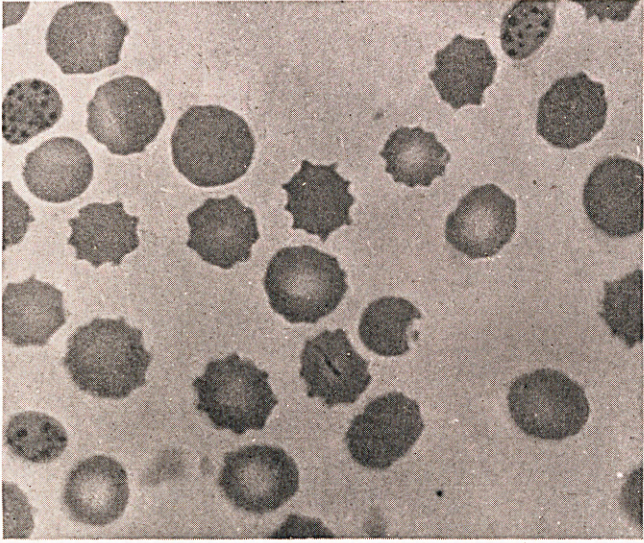
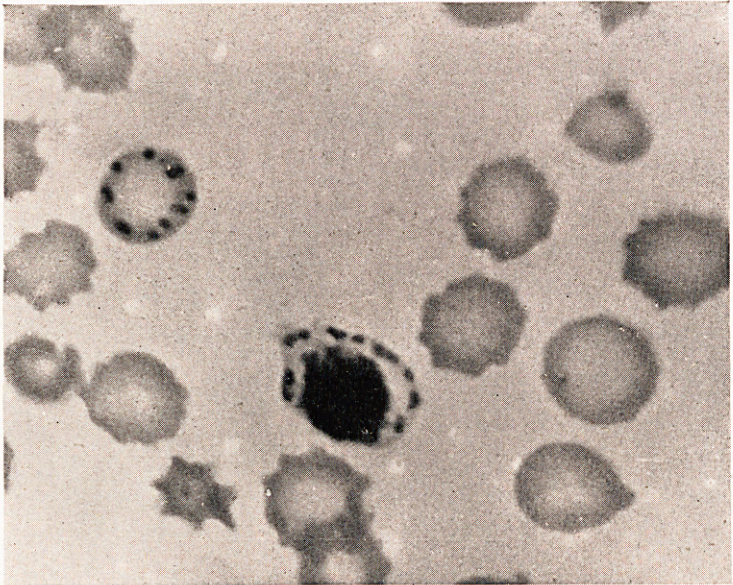


Fig. 2.



## LEGENDS FOR PLATES 3 to 7.

*Plate 3.* Peripheral blood films from cases of acquired haemolytic anaemia after splenectomy stained with Leishman.

*Fig. 1.* Case 1. Note solitary inclusion bodies. *Fig. 2.* Case 6. Note multiple inclusion bodies.

*Plate 4.* Peripheral blood films from cases of acquired haemolytic anaemia after splenectomy stained with potassium ferrocyanide, hydrochloric acid and dilute carbol fuchsin.

*Fig. 1.* Note defective haemoglobinization in erythrocyte containing multiple coarse inclusion bodies. *Figs. 2 and 6.* Inclusion bodies in normoblasts in the peripheral blood. *Fig. 3.* Example of irregular masses. *Fig. 4.* Examples of amoeboid form of inclusions. *Fig. 5.* Multiple very fine inclusion bodies. *Fig. 7.* Deposit of lysed blood from Case 1 showing numerous Pappenheimer bodies.  $\times 600$ .

*Plate 5.* Sternal marrow films from cases of acquired haemolytic anaemia stained with potassium ferrocyanide, hydrochloric acid and dilute carbol fuchsin.

*Figs. 1, 3 and 4.* Note defective haemoglobinization in affected normoblasts. *Fig. 2.* Normoblast containing a crescent of inclusion material. *Fig. 5.* Erythrocytes containing inclusion material in one of which it is arranged as a fine mesh. *Fig. 6.* Normoblast containing bacillary and coccoid forms.

*Plate 6.* Preparations from various haematological conditions stained with potassium ferrocyanide, hydrochloric acid and dilute carbol fuchsin.

*Fig. 1.* Peripheral blood film from case of pernicious anaemia in relapse showing numerous inclusion bodies within a megaloblast. *Fig. 2.* Sternal marrow film from a case of advanced carcinoma with anaemia showing inclusion bodies in normoblasts. *Fig. 3.* Sternal marrow film from a case of chronic sepsis showing numerous inclusions within a normoblast showing karyorrhexis. *Fig. 4.* Sternal marrow film from a case of pernicious anaemia in relapse showing ruptured megaloblast with numerous inclusion bodies in the remains of the cytoplasm. *Fig. 5.* Sternal marrow from a case of uraemia showing inclusion bodies in two normoblasts, one of which displays defective haemoglobinization. *Fig. 6.* Sternal marrow film from a case of uraemia showing inclusion bodies within a normoblast.

*Plate 7.* Peripheral blood films from guinea pigs with experimental lead poisoning stained with potassium ferrocyanide, hydrochloric acid and dilute carbol fuchsin.

*Fig. 1.* Erythrocytes containing iron positive inclusion bodies. Note gradation in size. *Fig. 2.* Coarse iron positive inclusion bodies in an erythrocyte and normoblast. Note defective haemoglobinization.