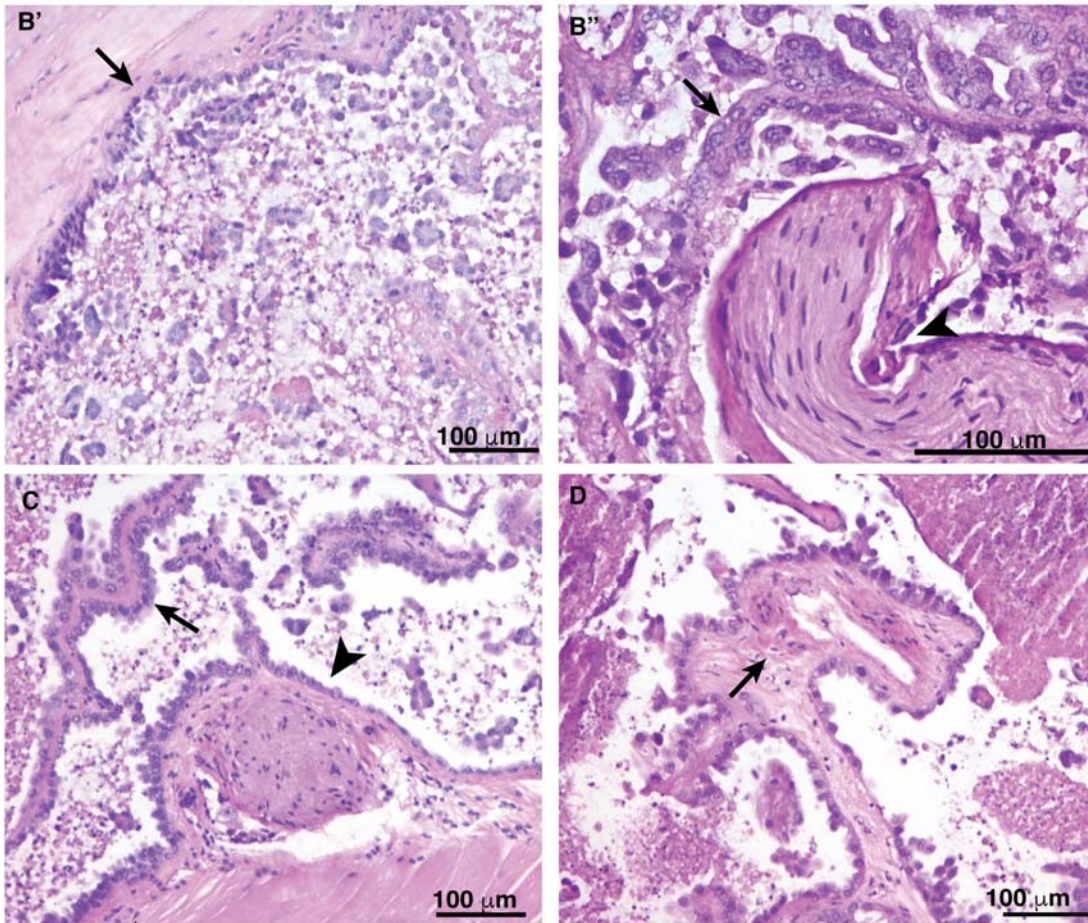


# Supplemental Materials

*Molecular Biology of the Cell*

Oyanadel et al.

Enlargements of selected Figure 10 images



Supplementary Figure 1: Regions with malignant traits in MDCK-Gal8<sup>H</sup> tumors. (Figure 10B'; Muscle infiltration (arrow). (Figure 10 B'') Papillae differentiation (arrow) and perineural invasion (arrow head). (Figure 10 C) Papillae (arrow), muscle infiltration (white arrow head) and perineural invasion (black arrow head). (Figure 10 D) A papillae with vascular structure (Arrow).