

An area of hyperplasia in the visceral pleura of one of the POT fiber treated rats

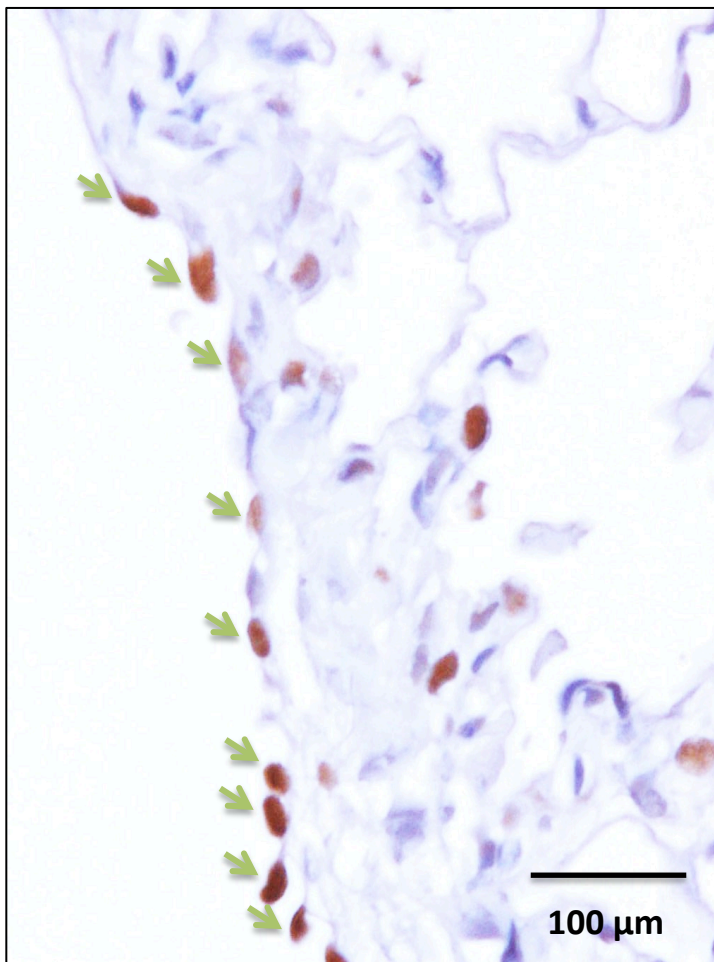


Figure S3. One of the POT treated rats developed hyperplasia of the visceral pleura 4 wks after the last TIPS administration. This area has a large number of PCNA positive visceral mesothelial cells (arrows).