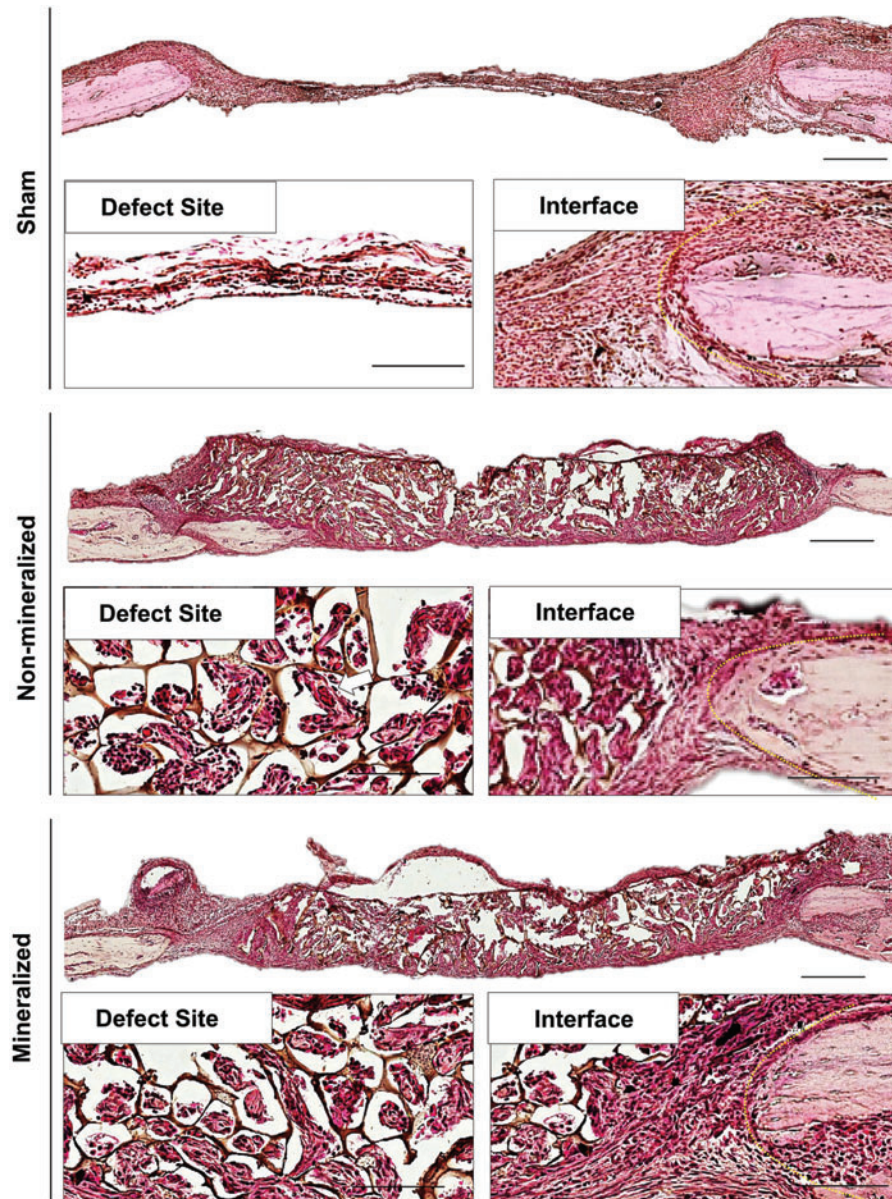


Supplementary Data



SUPPLEMENTARY FIG. S1. H&E staining of cranial sections following 2 weeks of implantation. High magnification images of the defect implant site (*lower left panels*) and at the interface between the defect site and native bone (*lower right panels*). *White arrow* depicts vessel formation. A *yellow dotted line* was used to delineate the location of the interface between implant and native bone. Scale bars: 500 mm (*upper panel*) and 30 mm (*lower panels*). H&E, hematoxylin and eosin.