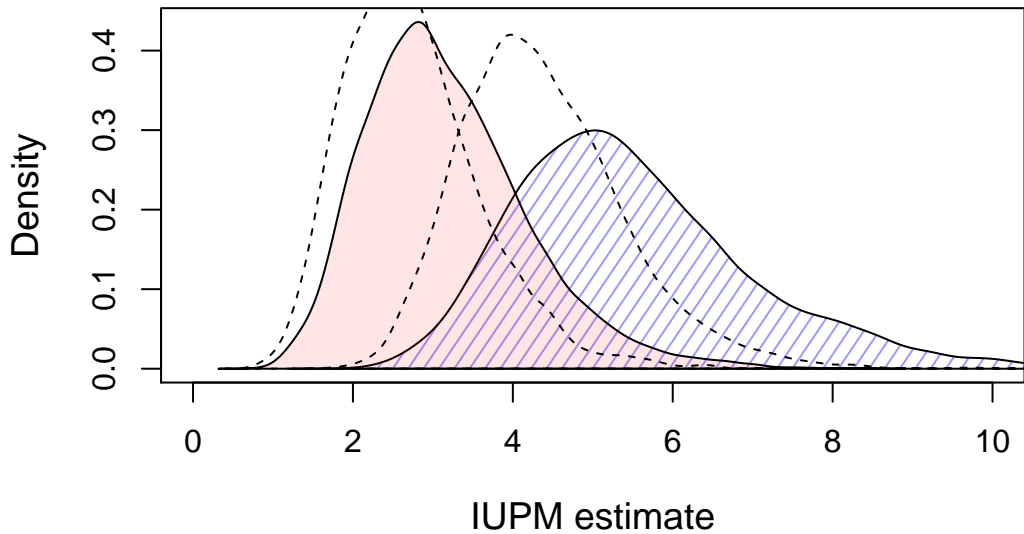


Patient 106



Patient 111

