

End-of-treatment and serial PET imaging in primary mediastinal B-cell lymphoma following dose-adjusted EPOCH-R: a paradigm shift in clinical decision making

Christopher Melani,¹ Ranjana Advani,² Mark Roschewski,¹ Kelsey M. Walters,² Clara C. Chen,³ Lucia Baratto,⁴ Mark A. Ahlman,³ Milos D. Miljkovic,¹ Seth M. Steinberg,⁵ Jessica Lam,² Margaret Shovlin,¹ Kieron Dunleavy,⁶ Stefania Pittaluga,⁷ Elaine S. Jaffe⁷ and Wyndham H. Wilson¹

¹Lymphoid Malignancies Branch, Center for Cancer Research, National Cancer Institute, National Institutes of Health, Bethesda, MD; ²Stanford Cancer Institute, Stanford University, CA; ³Nuclear Medicine Division, Radiology and Imaging Sciences, Clinical Center, National Institutes of Health, Bethesda, MD; ⁴Nuclear Medicine and Molecular Imaging Division, Stanford University, CA; ⁵Biostatistics and Data Management Section, Center for Cancer Research, National Cancer Institute, National Institutes of Health, Bethesda, MD; ⁶George Washington University Cancer Center, DC and ⁷Laboratory of Pathology, Clinical Center, National Cancer Institute, National Institutes of Health, Bethesda, MD, USA

CM and RA contributed equally to this work.

©2018 Ferrata Storti Foundation. This is an open-access paper. doi:10.3324/haematol.2018.192492

Received: March 5, 2018.

Accepted: May 10, 2018.

Pre-published: May 10, 2018.

Correspondence: wilsonw@mail.nih.gov

SUPPLEMENTARY FIGURES

Figure 1A. SUV_{max} in negative EOT FDG-PET non-progressors.

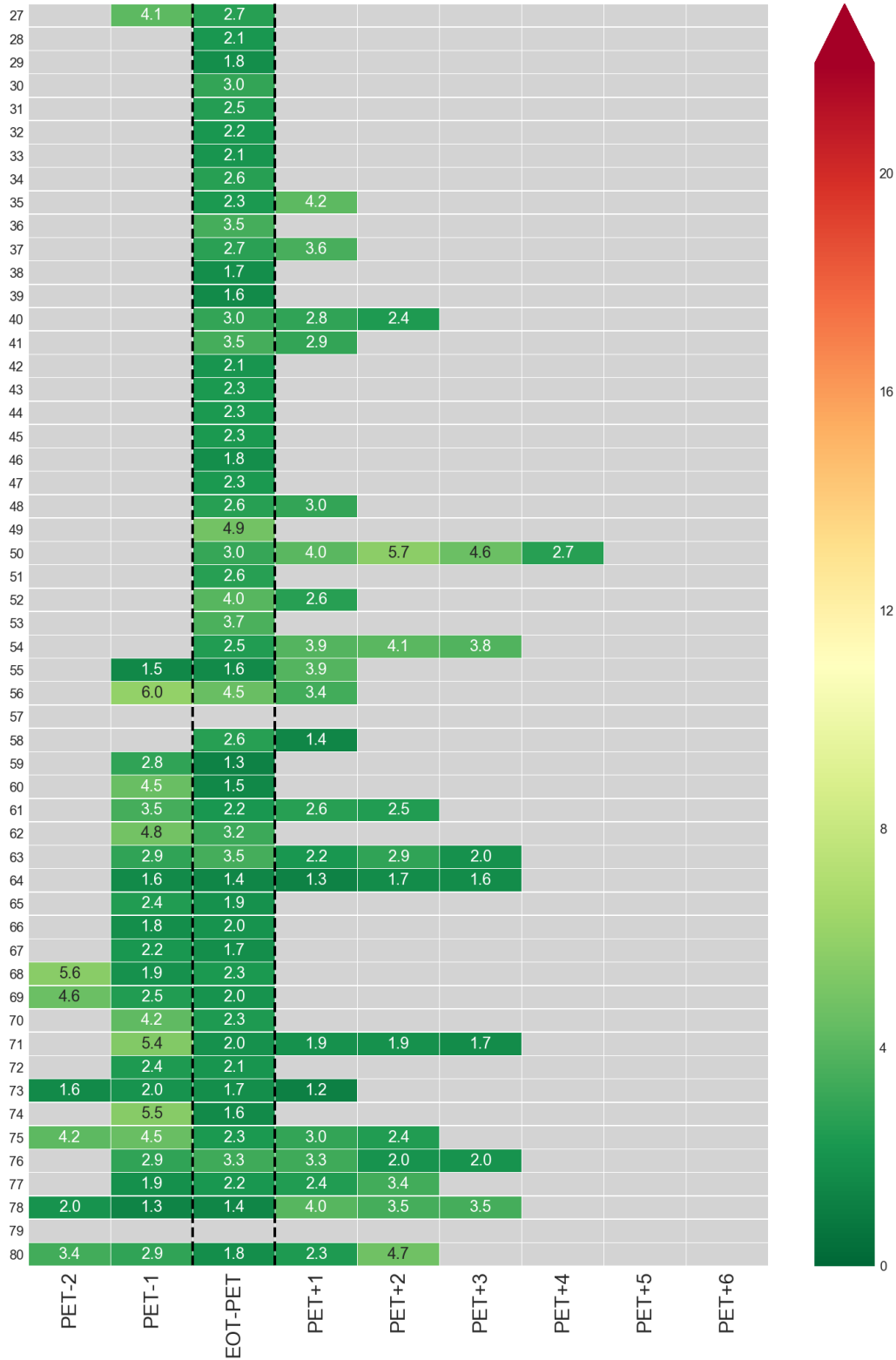


Figure 1B. Deauville score in negative EOT FDG-PET non-progressors.

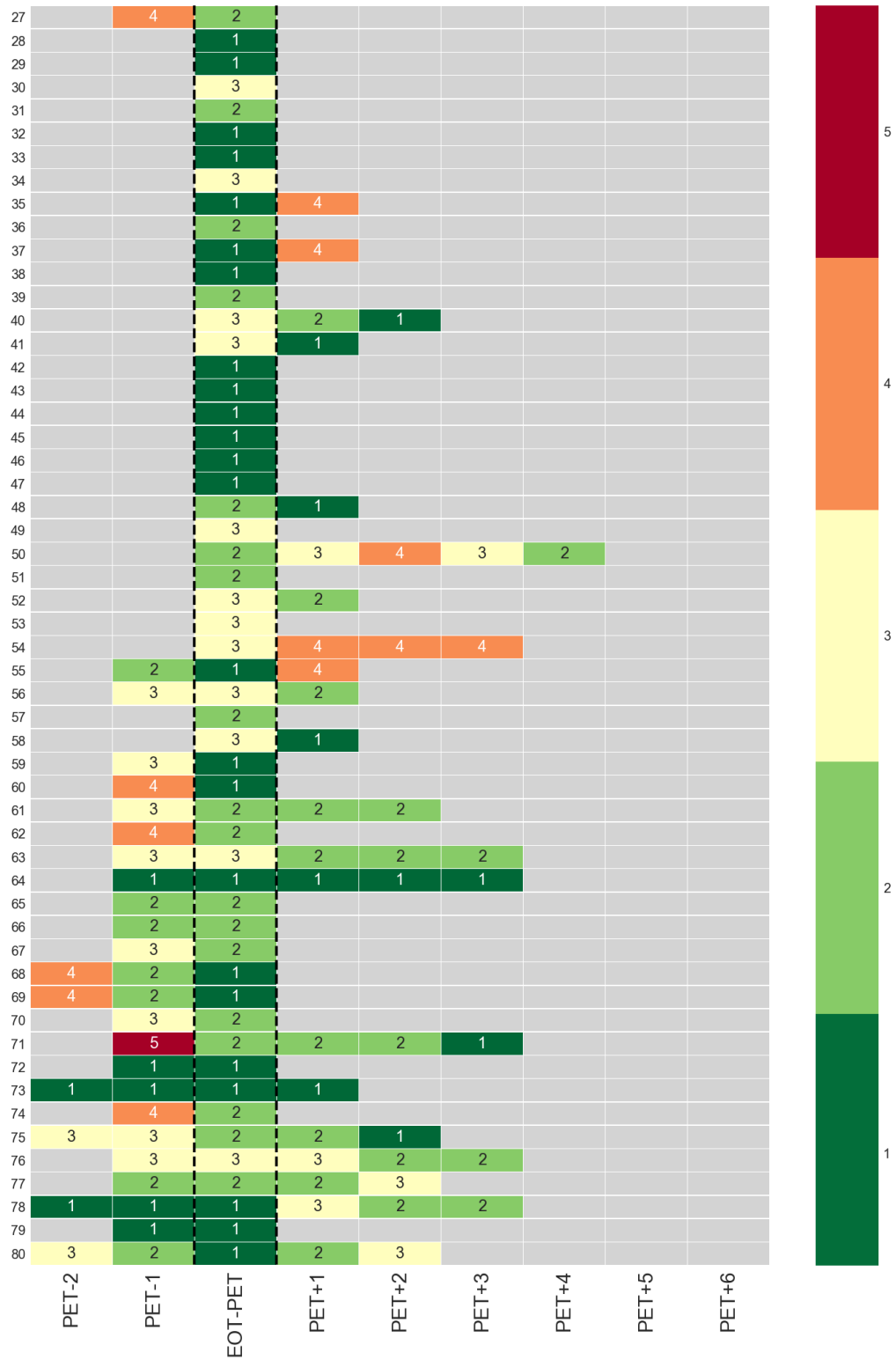


Figure 2A. Metabolic tumor volume in NCI patients with treatment failure.

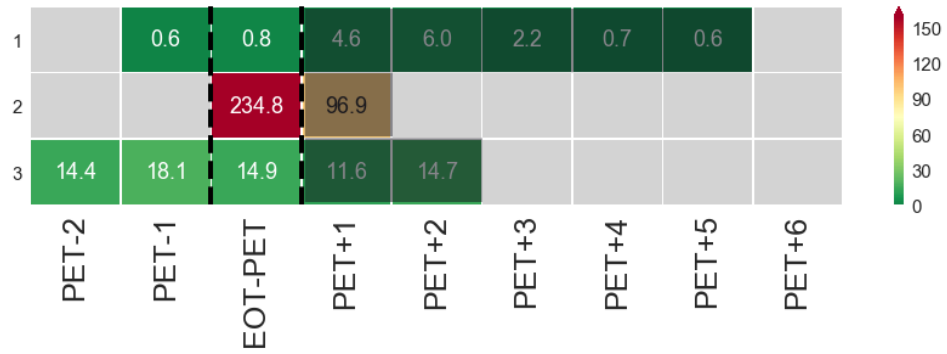


Figure 2B. Metabolic tumor volume in positive EOT FDG-PET non-progressing NCI patients.

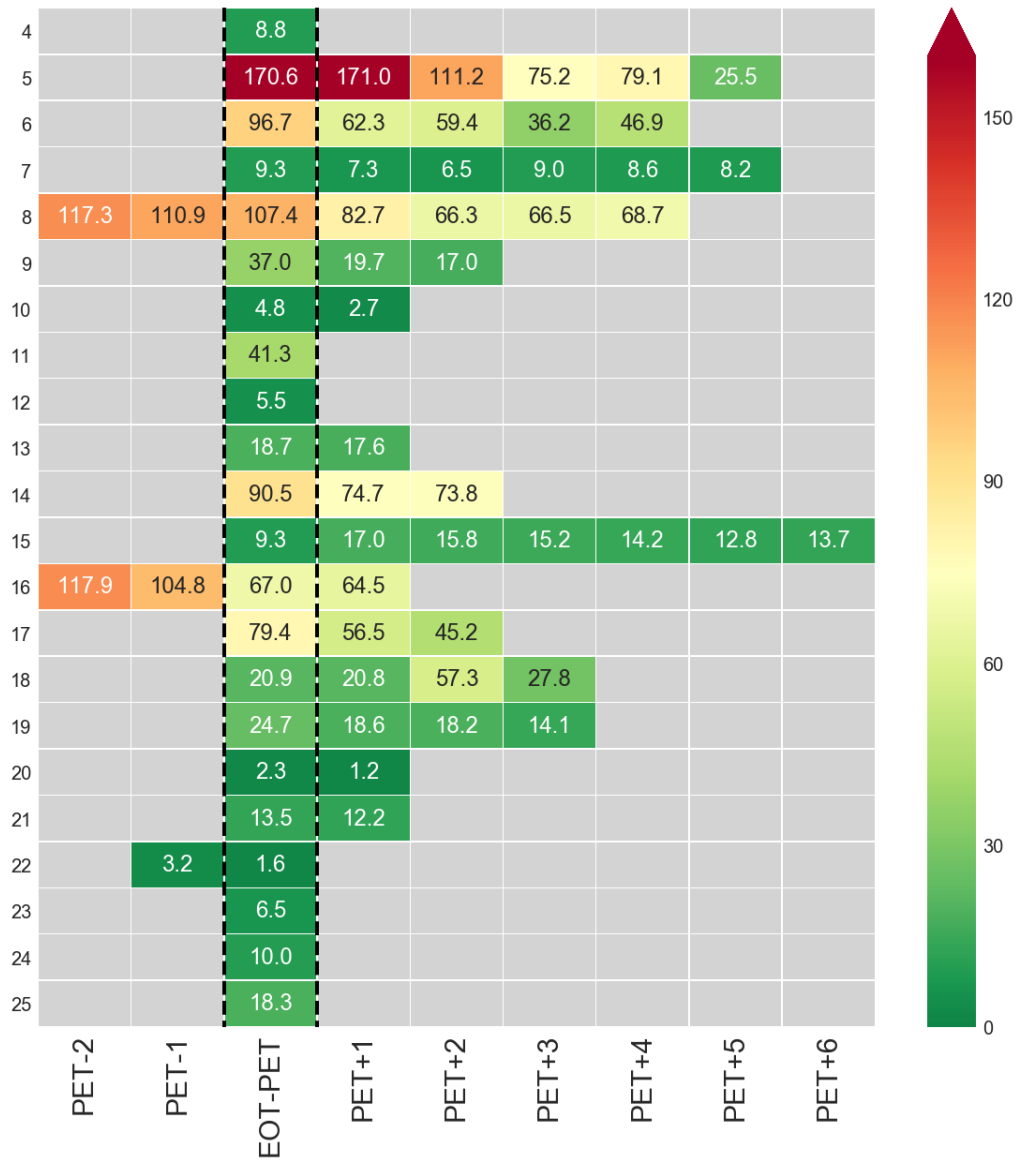


Figure 2C. Metabolic tumor volume in negative EOT FDG-PET non-progressing NCI patients.

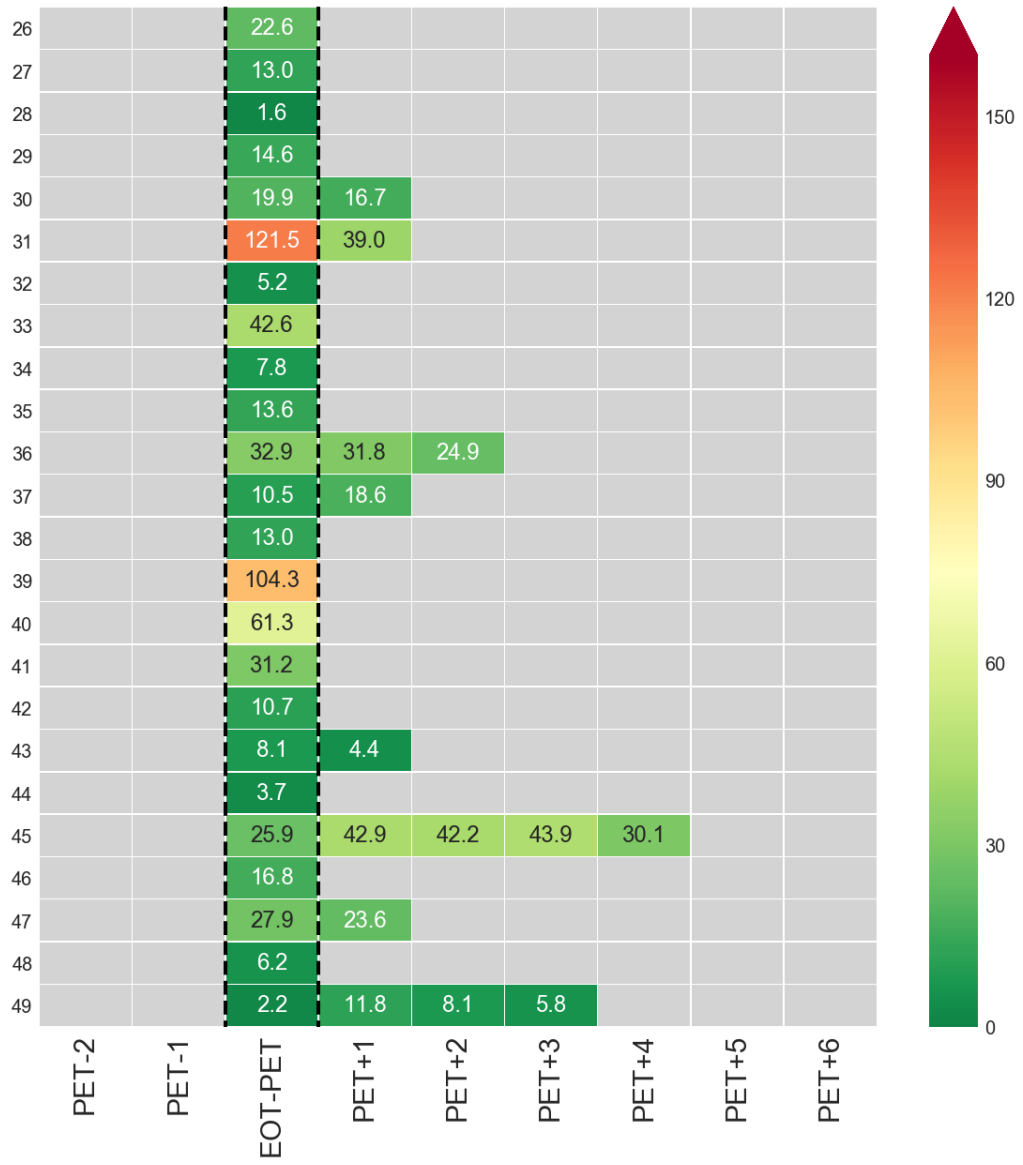


Figure 3A. Total lesion glycolysis in NCI patients with treatment failure.

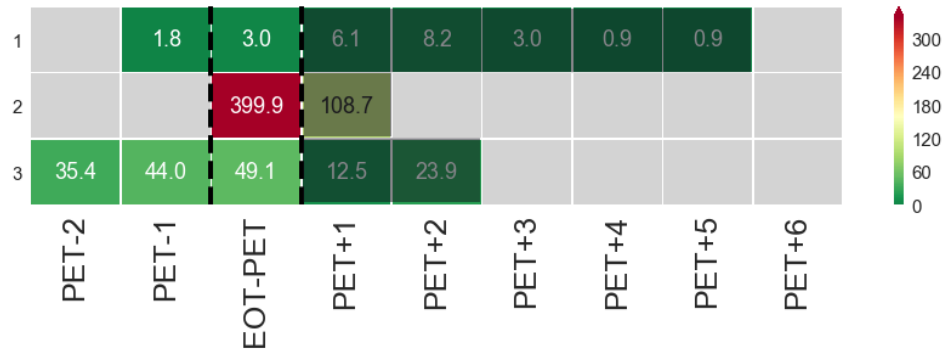


Figure 3B. Total lesion glycolysis in positive EOT FDG-PET non-progressing NCI patients.

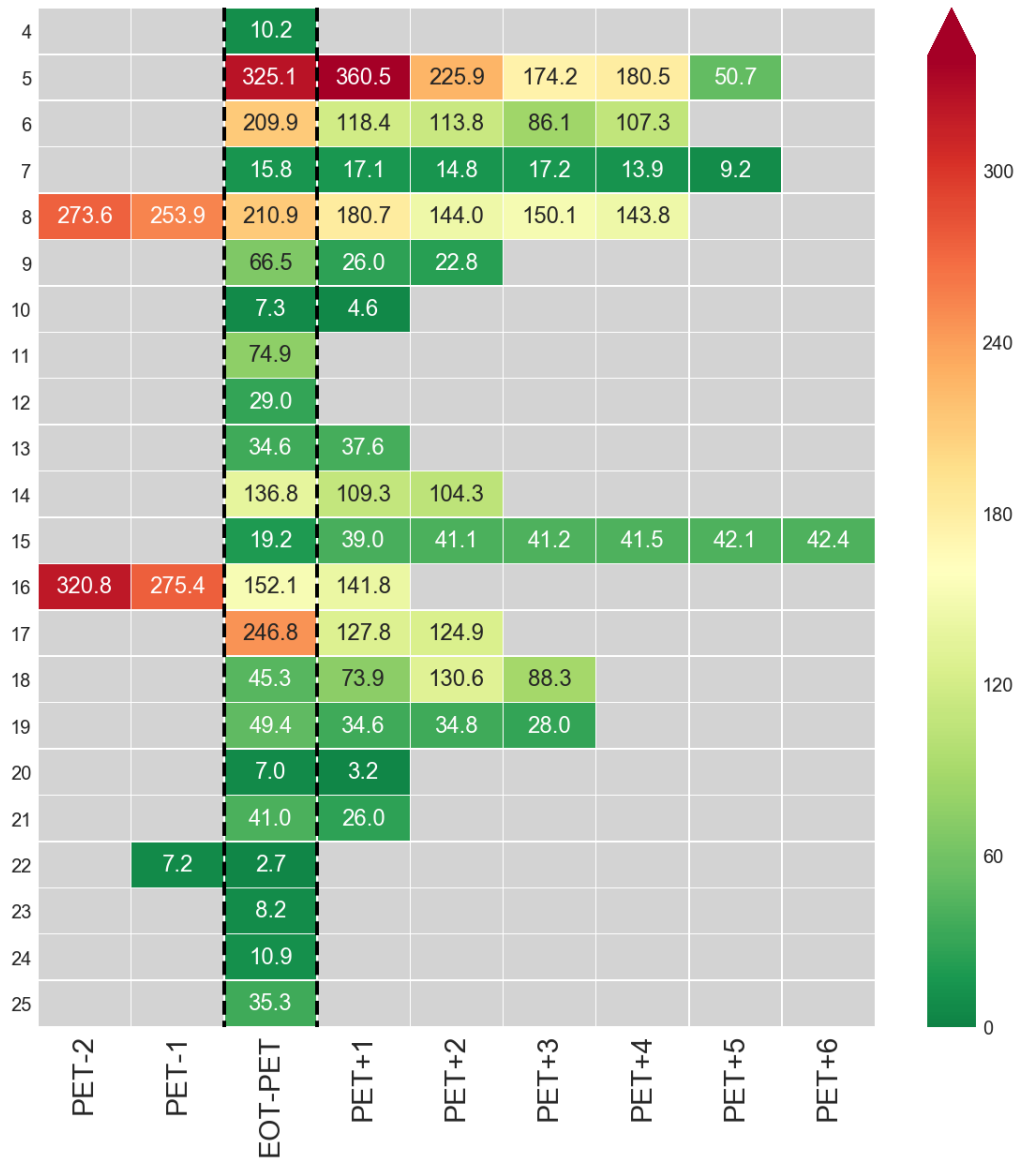
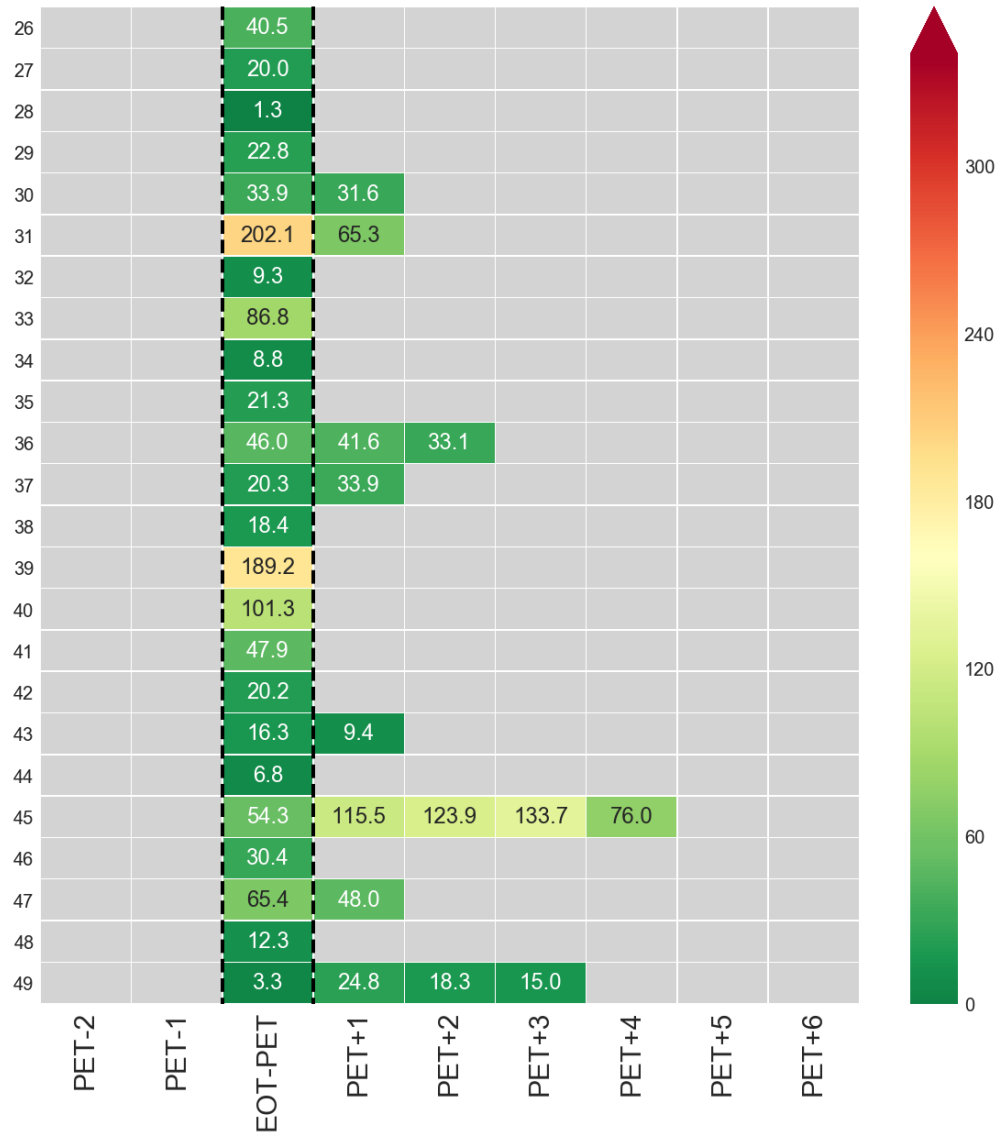


Figure 3C. Total lesion glycolysis in negative EOT FDG-PET non-progressing NCI patients.



SUPPLEMENTARY FIGURE LEGENDS

Figure 1. Serial FDG-PET imaging in negative EOT FDG-PET non-progressors.

Heatmap depiction of (A). SUV_{max} and (B). Deauville score, over time in the 56 non-progressing patients with a negative EOT FDG-PET scan. FDG-PET scans performed prior to the EOT FDG-PET are listed as negative numbers with those following the EOT FDG-PET listed as positive numbers. The EOT FDG-PET scan is bordered by black dashed lines. Two patients (#57 and #79) did not have EOT SUV_{max} values despite having an EOT Deauville score due to technical reasons.

Figure 2. Metabolic tumor volume (MTV) in NCI patients.

Heatmap depiction of MTV in the 49 NCI patients with an EOT FDG-PET scan and serial FDG-PET imaging. The significant variability in MTV values between (A). treatment failures, (B). positive EOT FDG-PET non-progressors, and (C). negative EOT FDG-PET non-progressors, is likely secondary to the overall low volume of disease following therapy in these patients as well as the inability to exclude non-malignant causes of FDG uptake (i.e. thymic rebound, normal variant brown fat, infectious/inflammatory causes, etc.) during contouring and calculation. FDG-PET scans performed prior to the EOT FDG-PET are listed as negative numbers with those following the EOT FDG-PET listed as positive numbers. The EOT FDG-PET scan is bordered by black dashed lines. FDG-PET scans performed following salvage intervention are shaded in black.

Figure 3. Total lesion glycolysis (TLG) in NCI patients.

Heatmap depiction of TLG in the 49 NCI patients with an EOT FDG-PET scan and serial FDG-PET imaging. The significant variability in TLG values between (A). treatment failures, (B). positive EOT FDG-PET non-progressors, and (C). negative EOT FDG-PET non-progressors, is likely secondary to the overall low volume of disease following therapy in these patients as well as the inability to exclude non-malignant causes of FDG uptake (i.e. thymic rebound, normal variant brown fat, infectious/inflammatory causes, etc.) during contouring and calculation. FDG-PET scans performed prior to the EOT FDG-PET are listed as negative numbers with those following the EOT FDG-PET listed as positive numbers. The EOT FDG-PET scan is bordered by black dashed lines. FDG-PET scans performed following salvage intervention are shaded in black.