

Supplementary information

Noninvasive Anatomical and Functional Imaging of Orthotopic Glioblastoma Development and Therapy using Optoacoustic Tomography

Ghayathri Balasundaram^{1†}, Lu Ding^{2†}, Li Xiuting^{1#}, Amalina Binte Ebrahim Attia^{1#}, Xose Luis Dean-Ben^{2#}, Chris Jun Hui Ho¹, Prashant Chandrasekaran¹, Tay Hui Chien¹, Lim Hann Qian¹, Chee Bing ONG³, Ralph. P. Mason⁴, Daniel Razansky^{2*}, Malini Olivo^{1*}

Affiliations:

¹Laboratory of Bio-optical Imaging, Singapore Bioimaging Consortium, Agency for Science Technology and Research (A*STAR), 11 Biopolis Way, #02-02 Helios, Singapore 138667.

²Institute for Biological and Medical Imaging, Technical University of Munich and Helmholtz Center Munich, Germany

³Advanced Molecular Pathology Lab (AMPL), Institute of Molecular and Cell Biology (IMCB), Agency for Science, Technology and Research (A*STAR), 61 Biopolis Drive, Proteos building, Singapore 138673

⁴Department of Radiology, University of Texas Southwestern Medical Center, Dallas, TX 75390, USA

*Correspondence: dr@tum.de, malini_olivo@sbic.a-star.edu.sg,

†, # Equal contributors

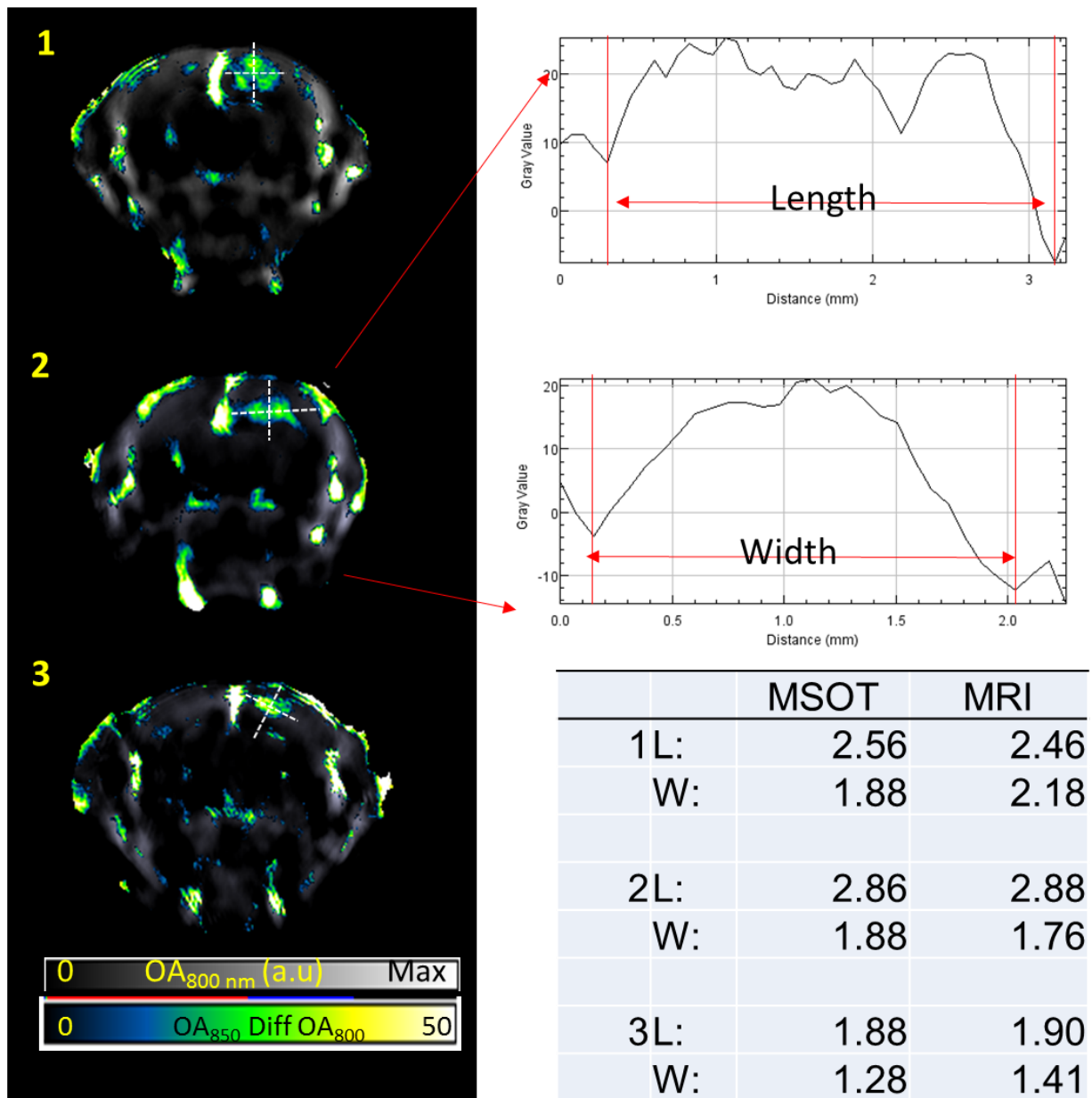


Fig S1. Anatomical imaging of murine orthotopic glioblastoma. Difference of single wavelength images at 850 nm and 800 nm projecting the shape and location of three tumors. Line plots drawn across tumor allows computing the length and width. The dimensions were similar to that observed using MRI T2 weighted imaging. All dimensions are in mm.

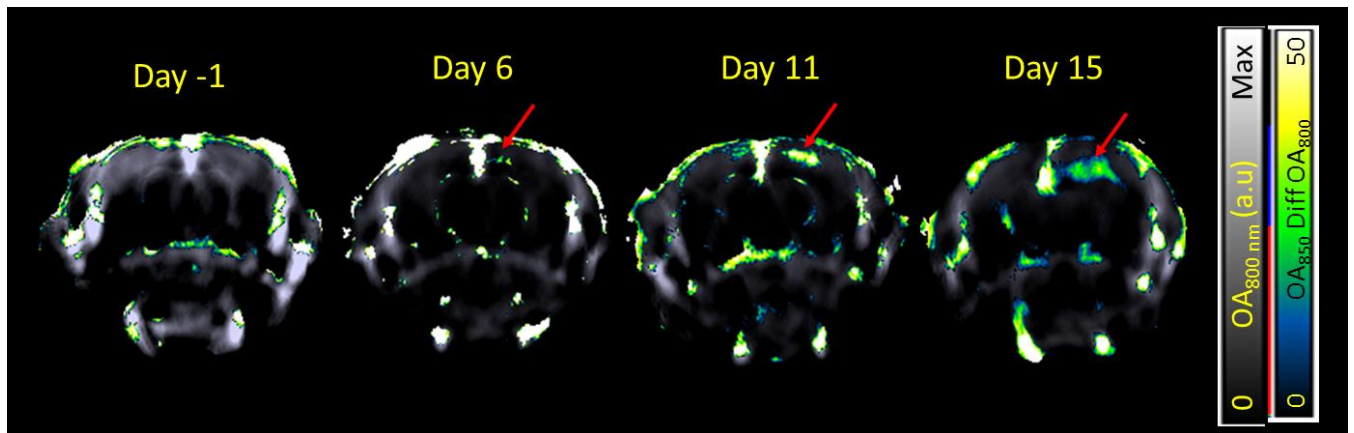


Fig S2. MSOT for evaluating tumor growth. Tumor growth was monitored up to 15 days using MSOT. The tumor was identified by hyperintense signals on the right cortex in the difference of single wavelength images at 850 and 800 nm. Tumor dimensions was measured manually on Image J at the largest cross section of the tumor and tumor volume was estimated as $1/2(\text{Length} \times \text{Width}^2)$.

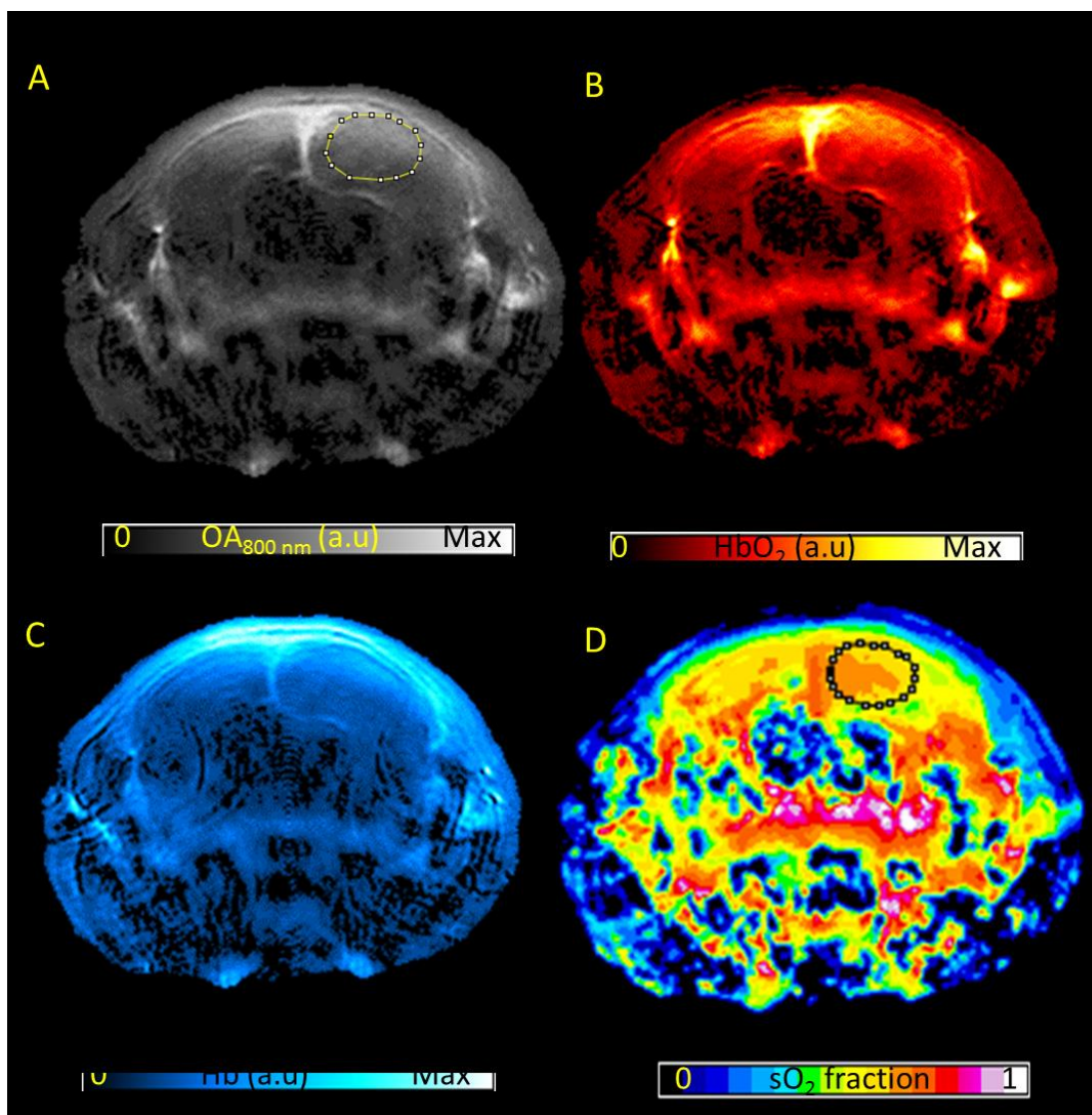


Fig S3. Functional Imaging of Glioblastoma. (A) Single wavelength optoacoustic image of the brain containing tumor (B) Oxyhemoglobin map, (C) deoxyhemoglobin map and (D) sO_2 fraction map after combined non-negative constrained reconstruction and unmixing.

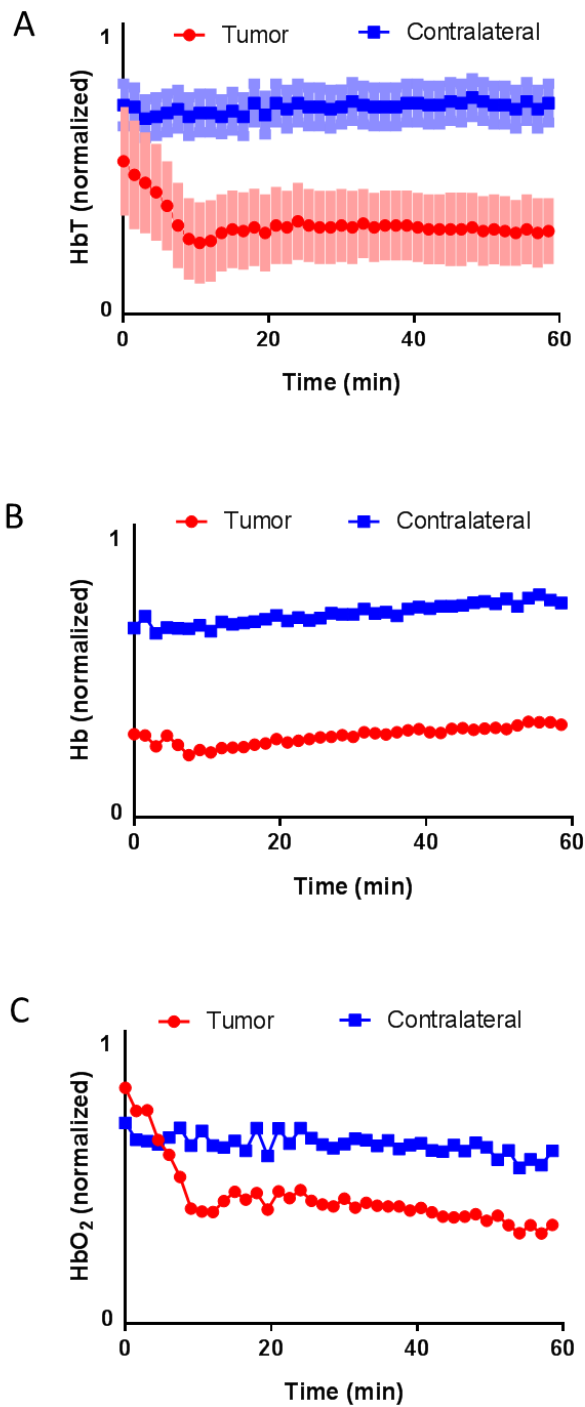


Fig S4. Real-time hemodynamic changes at the tumor upon administration of CA4P. Panel A, B and C shows the real-time total hemoglobin (HbT), deoxyhemoglobin (Hb) and oxyhemoglobin (HbO₂) changes respectively in the tumor and contralateral brain occurring immediately post CA4P administration over 1 hour in a representative animal. SD are represented by lighter shades on the graph.

Supplementary video 1. Video of Dynamic changes in saturated oxygen in tumor and contralateral brain upon vda treatment over 1 hour