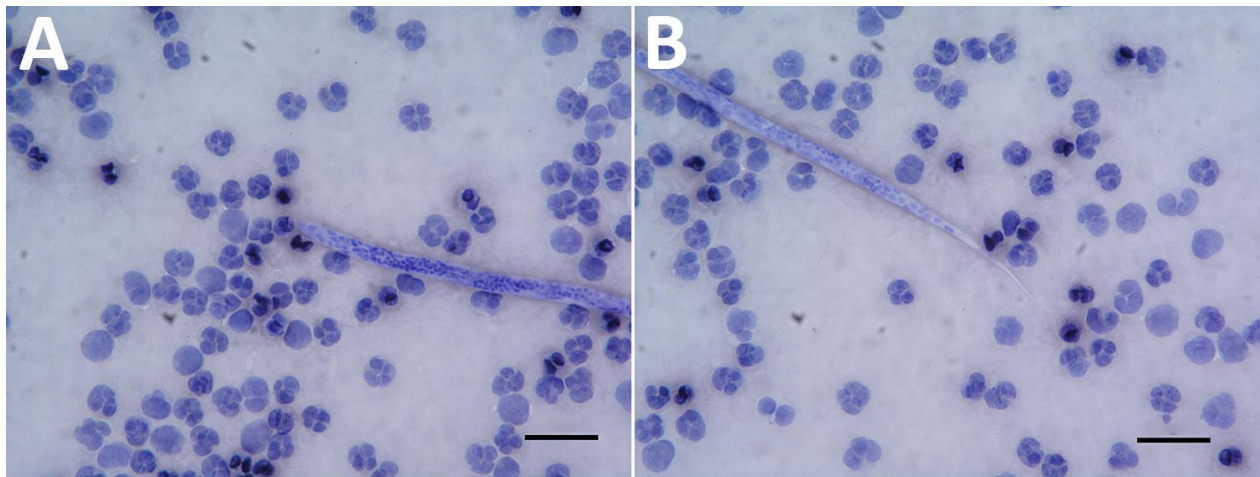


Dirofilaria repens Nematode Infection with Microfilaremia in Traveler Returning to Belgium from Senegal

Technical Appendix.



Technical Appendix Figure. *Dirofilaria repens* microfilaria in blood of a 76-year-old man who returned to Belgium from Senegal. A) Cephalic end of microfilaria. B) Tail end of microfilaria. Scale bars indicate 30 μm , original magnification $\times 500$.