# Supplementary Material

## Functional Networks Reemerge During Recovery of Consciousness after Acute Severe Traumatic Brain Injury

Zachary D. Threlkeld, MD[a,b], Yelena G. Bodien, PhD[a,b,c], Eric S. Rosenthal, MD[b], Joseph T. Giacino, PhD[c], Alfonso Nieto-Castanon, PhD[d] Ona Wu, PhD[e], Susan Whitfield-Gabrieli, PhD,[f] and Brian L. Edlow, MD[a,b,e]

From the [a]Center for Neurotechnology and Neurorecovery and [b]Department of Neurology, Massachusetts General Hospital, Harvard Medical School, Boston, MA; [c]Department of Physical Medicine and Rehabilitation, Spaulding Rehabilitation Hospital, Charlestown, MA; [d]Department of Speech, Language, and Hearing Sciences, Boston University, Boston , MA; [e]Athinoula A. Martinos Center for Biomedical Imaging, Department of Radiology, Massachusetts General Hospital, Charlestown, MA; [f]Martinos Imaging Center at McGovern Institute for Brain Research, Massachusetts Institute of Technology, Cambridge MA

* Corresponding Author:
Dr. Brian L. Edlow
Center for Neurotechnology and Neurorecovery
Massachusetts General Hospital
175 Cambridge Street – Suite 300
Boston, MA 02114
Phone: (617) 724-6352
email: bedlow@mgh.harvard.edu

Email addresses: zthrelkeld@mgh.harvard.edu (Z.D. Threlkeld); ybodien@mgh.harvard.edu (Y.G. Bodien), erosenthal@mgh.harvard.edu (E.S. Rosenthal), jgiacino@mgh.harvard.edu (J.T. Giacino), alfnie@gmail.com (A. Nieto-Castanon), ona@nmr.mgh.harvard.edu (O. Wu), swg@mit.edu (S. Whitfield-Gabrieli), bedlow@mgh.harvard.edu (B.L. Edlow)

## Supplementary Tables and Table Legends

### Supplementary Table 1 – Patient demographics and clinical characteristics.

| ID | Age | Sex | TBI Mechanism | iGCS | Acute fMRI (days post-injury) | CRS-R at Acute fMRI | LoC at Acute fMRI | GCS at Acute fMRI | Follow-up fMRI (days post-injury) | Large Focal Lesions on Acute Structural MRI |
|---|---|---|---|---|---|---|---|---|---|---|
| P1 | 27 | M | MVA | 5T | 16 | 23 | PTCS | 15 | 206 | R frontal and parietal contusions; small R frontal subdural hemorrhage |
| P2 | 21 | M | Ped vs. car | 4-8T | 1 | 4 | MCS | 7 | 174 | L frontal EVD tract |
| P3 | 19 | F | MVA | 5T | 3 | 1 | Coma | 5T | 371 | None |
| P4 | 34 | M | Fall | 5T | 15 | 3 | UWS | 6T | - | Bifrontal contusions; R frontoparietal contusion |
| P5 | 28 | F | MVA | 3 | 7 | 6 | UWS | 9T | 656 | L frontal contusion |
| P6 | 45 | M | MVA | 5T | 13 | 18 | MCS | 13 | - | None |
| P7 | 33 | M | Fall | 5-7T | 8 | 20 | PTCS | 11T | - | R posterior temporal contusion; L anterior temporal contusion |
| P8 | 32 | M | Ped vs. car | 5-7T | 11 | 9 | MCS | 10T | - | Hemorrhage in splenium of corpus callosum |
| P9 | 24 | M | Assault | 3-7T | 12 | 10 | MCS | 10 | - | R anterior temporal contusion; L tentorial subdural hemorrhage |
| P10 | 22 | F | Ped vs. car | 6T | 14 | 22 | PTCS | 14 | 187 | L temporo-parietal contusion; R thalamic hemorrhage |
| P11 | 27 | F | Fall | 3 | 8 | 1 | Coma | 5T | - | R anterior temporal contusion |
| P12 | 18 | M | Fall | 3-7 | 4 | 12 | MCS | 10T | - | L frontal contusion |
| P13 | 51 | M | Ped vs. car | 3 | 8 | 3 | UWS | 6T | - | R frontal contusion; L frontal and L mesial temporal contusions |
| P14 | 29 | M | Ped vs. car | 4-7 | 7 | 3 | MCS | 7T | 235 | L insular contusion; R frontal EVD tract |
| P15 | 33 | M | Fall | 3-4 | 3 | 12 | MCS | 10T | 191 | None |
| P16 | 26 | F | Ped vs. truck | 3-3T | 12 | 2 | UWS | 8T | - | R anterior temporal and L posterior temporal contusions; R frontal and L temporal subdural hemorrhages |
| P17 | 26 | M | Fall | 4T | 14 | 18 | PTCS | 11 | 190 | L temporal contusion; L frontal EVD tract |

The initial Glasgow Coma Scale (iGCS) is defined as the best (i.e. highest) and worst (i.e. lowest) post-resuscitation GCS score assessed by a qualified clinician who performed a reliable

examination (not confounded by sedation and/or paralytics) prior to ICU admission. Level of consciousness (LoC) is assessed via behavioral evaluation with the Coma Recovery Scale Revised (CRS-R) as coma, unresponsive wakefulness syndrome (UWS), minimally conscious state (MCS), or post-traumatic confusional state (PTCS). Large focal lesions do not include microhemorrhages detected by susceptibility-weighted imaging or punctate lesions detected by T2-weighted or diffusion-weighted MRI. Other abbreviations: EVD = external ventricular drain; fMRI = functional MRI; L = left; MVA = motor vehicle accident; Ped = pedestrian; R = right; TBI = traumatic brain injury.

**Supplementary Table 2 – Sedative, anxiolytic, and analgesic medications administered before and during functional MRI.**

| ID | Medication(s) Administered Before fMRI | Medication(s) Administered During fMRI |
|---|---|---|
| P1 | Diazepam 2.5 mg PGT | Morphine 6 mg IV |
| P2 | None | None |
| P3 | Propofol 300 mg/hr IV gtt | Propofol 300 mg/hr IV gtt |
| P4 | Lorazepam 1 mg IV | None |
| P5 | Hydromorphone 0.5 mg IV | Hydromorphone 0.5 mg IV |
| P6 | Quetiapine 12.5 mg PGT | None |
| P7 | Propofol 300 mg/hr IV gtt | Propofol 400 mg/hr IV gtt + Hydromorphone 0.5 mg |
| P8 | Propofol 200 mg/hr IV gtt | Propofol 200 mg/hr IV gtt |
| P9 | None | None |
| P10 | Lorazepam 1 mg IV | Haloperidol 5 mg IV |
| P11 | Propofol 50 mg/hr IV gtt | Propofol 50 mg/hr IV gtt |
| P12 | Propofol 300 mg/hr IV gtt | Propofol 300 mg/hr IV gtt |
| P13 | Fentanyl 50 mcg IV + Propofol 20 mg IV | Propofol 25 mg/hr IV gtt |
| P14 | Propofol 300 mg/hr IV gtt + Fentanyl 50 mcg IV | Propofol 200 mg/hr IV gtt |
| P15 | Propofol 300 mg/hr IV gtt + Fentanyl 50 mcg IV | Propofol 300 mg/hr IV gtt |
| P16 | 50 mcg fentanyl 2h prior to fMRI | None |
| P17 | None | None |

Abbreviations: gtt = continuous infusion; IV = intravenous; PGT = administered via percutaneous gastric tube.

**Supplementary Table 3 – Effect of FDR- versus FWE-correction.**

| | FDR-Corrected | | FWE-Corrected | |
|---|---|---|---|---|
| ID | Correlation | Anticorrelation | Correlation | Anticorrelation |
| C1 | 1.27 | -0.42 | 1.27 | -0.41 |
| C2 | 1.37 | -1.13 | 1.37 | -1.13 |
| C3 | 1.12 | -0.87 | 1.12 | -0.87 |
| C4 | 0.82 | -0.53 | 0.82 | -0.52 |
| C5 | 0.99 | -0.86 | 0.99 | -0.87 |
| C6 | 0.80 | -0.61 | 0.80 | -0.61 |
| C7 | 1.12 | -0.59 | 1.12 | -0.59 |
| C8 | 0.75 | -0.31 | 0.75 | -0.31 |
| C9 | 0.75 | -0.30 | 0.75 | -0.30 |
| C10 | 0.57 | -0.51 | 0.57 | -0.52 |
| C11 | 1.18 | -0.52 | 1.18 | -0.52 |
| C12 | 0.96 | -0.70 | 0.96 | -0.71 |
| C13 | 0.86 | -0.78 | 0.86 | -0.78 |
| C14 | 0.62 | -0.30 | 0.62 | -0.30 |
| C15 | 1.00 | -0.77 | 1.00 | -0.78 |
| C16 | 1.11 | -0.33 | 1.11 | -0.33 |
| P1 | 0.44 | -0.14 | 0.44 | -0.14 |
| P2 | 0.53 | -0.25 | 0.53 | -0.25 |
| P3 | -0.07 | 0.41 | -0.07 | 0.41 |
| P4 | 0.00 | 0.00 | 0.00 | 0.00 |
| P5 | 0.65 | 0.07 | 0.65 | 0.07 |
| P6 | 1.01 | -0.41 | 1.01 | -0.41 |
| P7 | 1.16 | -0.86 | 1.16 | -0.86 |
| P8 | 0.63 | 0.18 | 0.63 | 0.18 |
| P9 | 0.25 | -0.02 | 0.25 | -0.02 |
| P10 | 1.08 | -0.43 | 1.08 | -0.43 |
| P11 | 0.78 | -0.32 | 0.78 | -0.32 |
| P12 | 0.68 | -0.31 | 0.68 | -0.32 |
| P13 | 0.54 | -0.01 | 0.54 | 0.00 |
| P14 | 0.43 | -0.07 | 0.43 | -0.07 |
| P15 | 0.40 | 0.19 | 0.40 | 0.19 |
| P16 | 0.53 | -0.05 | 0.53 | -0.05 |
| P17 | 0.88 | 0.78 | 0.88 | 0.79 |
| P1* | 0.46 | -0.22 | 0.46 | -0.22 |
| P2* | 1.40 | -0.76 | 1.40 | -0.77 |
| P3* | 0.98 | -0.21 | 0.98 | -0.21 |
| P5* | 0.78 | -0.84 | 0.78 | -0.84 |
| P10* | 1.05 | -0.22 | 1.05 | -0.22 |
| P14* | 0.47 | -0.43 | 0.47 | -0.43 |
| P15* | 0.84 | -0.69 | 0.84 | -0.69 |
| P17* | 1.06 | -0.51 | 1.06 | -0.51 |

Global correlation and anticorrelation *z*-scores for each subject as calculated by cluster-level $P<0.05$ FDR- and FWE-correction for multiple comparisons. C1-C16 = healthy controls; P1-P17 = acute patient scans; * = follow-up patient scans.

**Supplementary Figures**

**Supplementary Fig. 1 – Normalization quality control.**

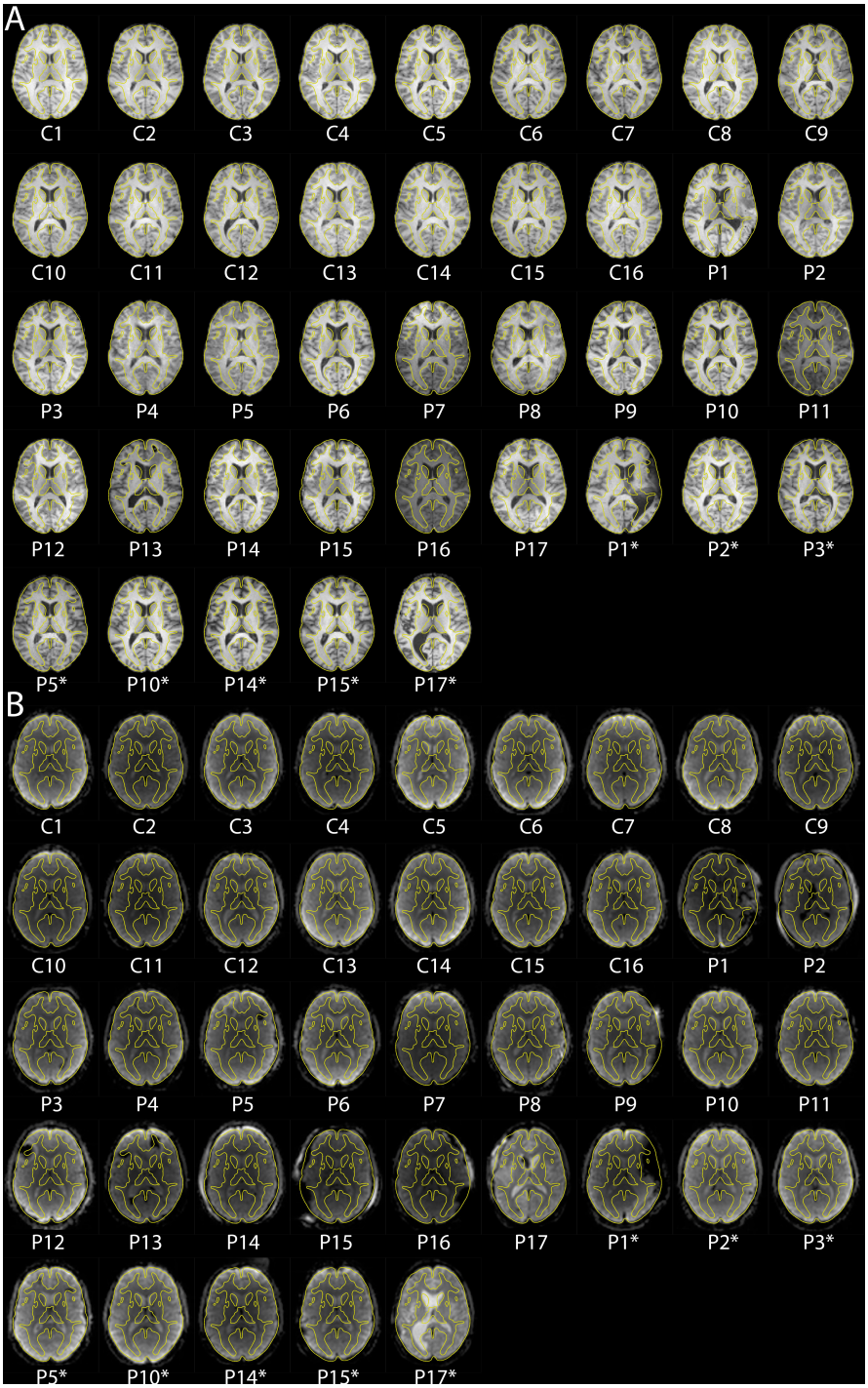


A representative axial image from each normalized structural (A) and functional (B) dataset is shown with the overlying Montreal Neurological Institute (MNI) template. Images are oriented in neurologic convention (left is left). C1-C16 = healthy controls; P1-P17 = acute patient scans; * = follow-up patient scans.

**Supplementary Fig. 2 – Correlation and anticorrelation masks used for extraction of global mean correlation and anticorrelation *z*-scores.**

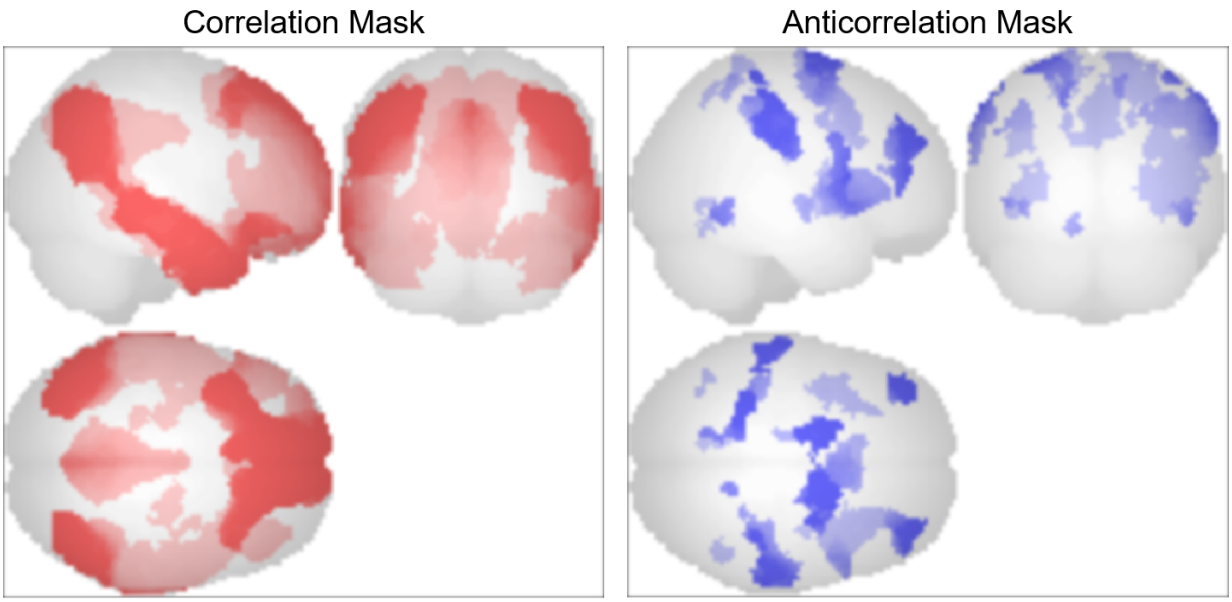


Masks were computed from voxels positively (correlation) or negatively (anticorrelation) correlated with default mode network seeds across all patients and healthy subjects.

**Supplementary Fig. 3 – Acute default mode network connectivity is associated with Coma Recovery Scale-Revised scores.**

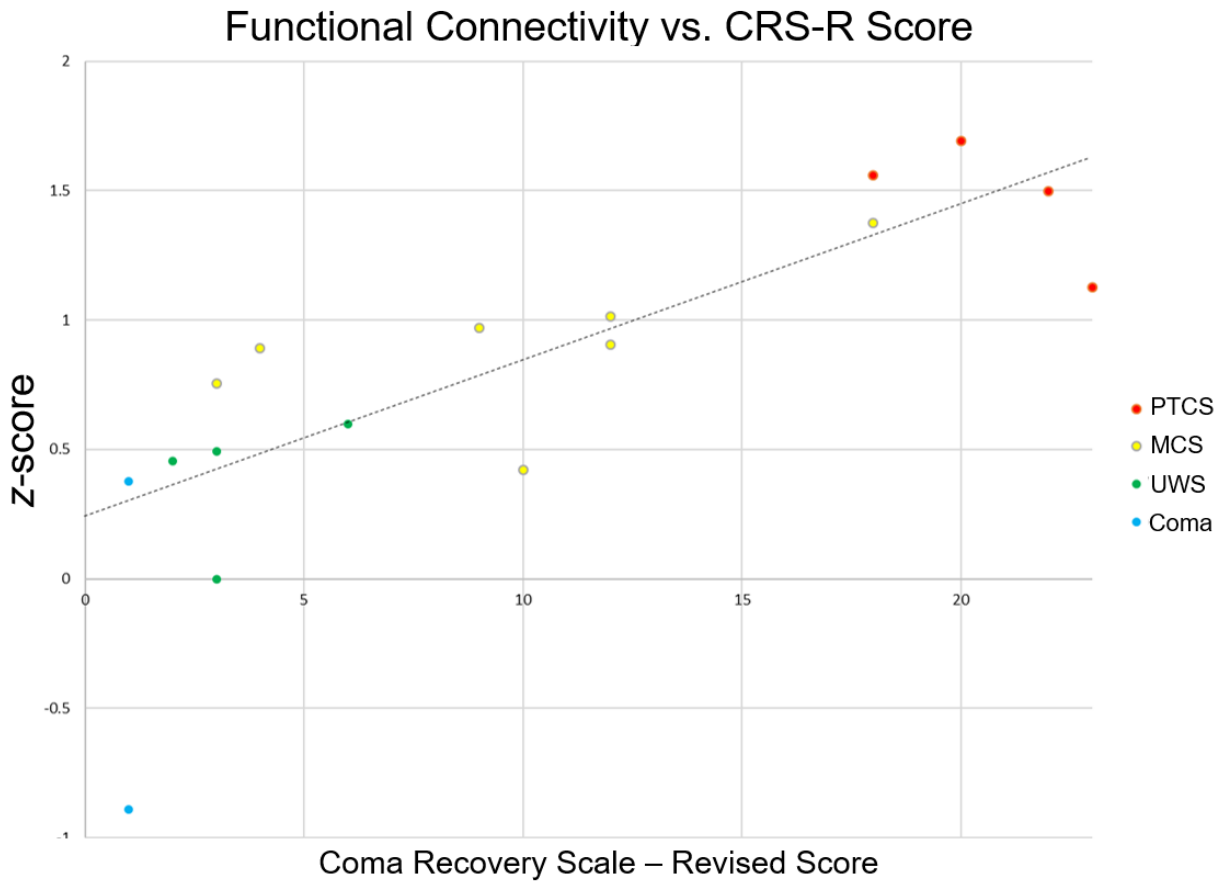


In a post-hoc analysis, mean z-scores in the posterior cingulate cortex and medial prefrontal cortex regions were extracted for each patient with acute DoC (n=17) and compared with concurrent Coma Recovery Scale-Revised total scores (Spearman's $\rho$ =0.88). MCS = minimally conscious state; PTCS = post-traumatic confusional state; UWS = unresponsive wakefulness syndrome.

**Supplementary Fig. 4 – Subject-level longitudinal changes in default mode network correlations and anticorrelations.**

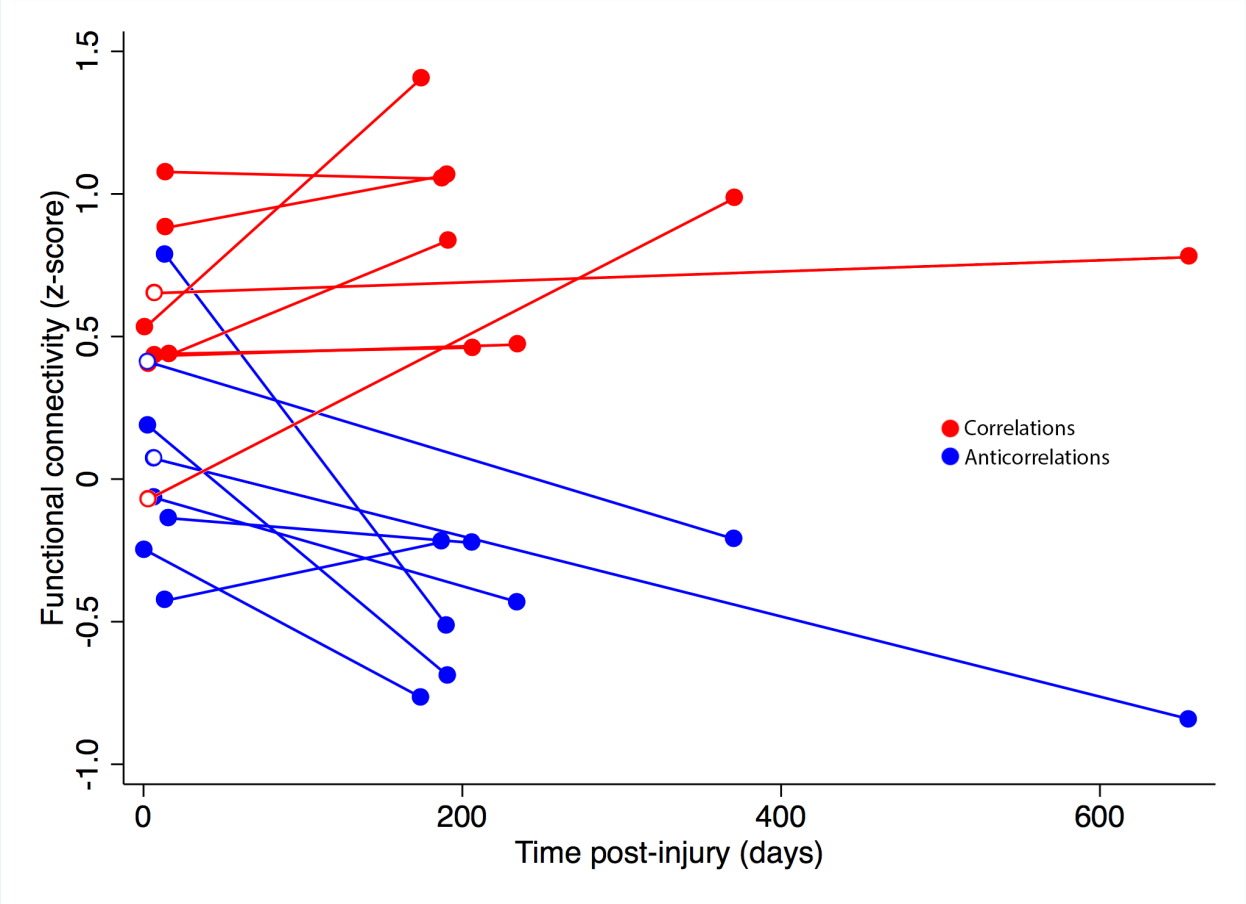


Patients who were followed longitudinally recovered from disorders of consciousness (DoC) and demonstrated normalization of DMN correlations (red) and anticorrelations (blue). Paired *t*-test indicated that changes in anticorrelations were significant ($P$=0.013), while changes in correlations trended toward significance ($P$=0.054). Open circles at time of initial assessment indicate a diagnosis of coma or UWS (i.e. unconscious); closed circles indicate a diagnosis of MCS or PTCS (i.e. conscious).