

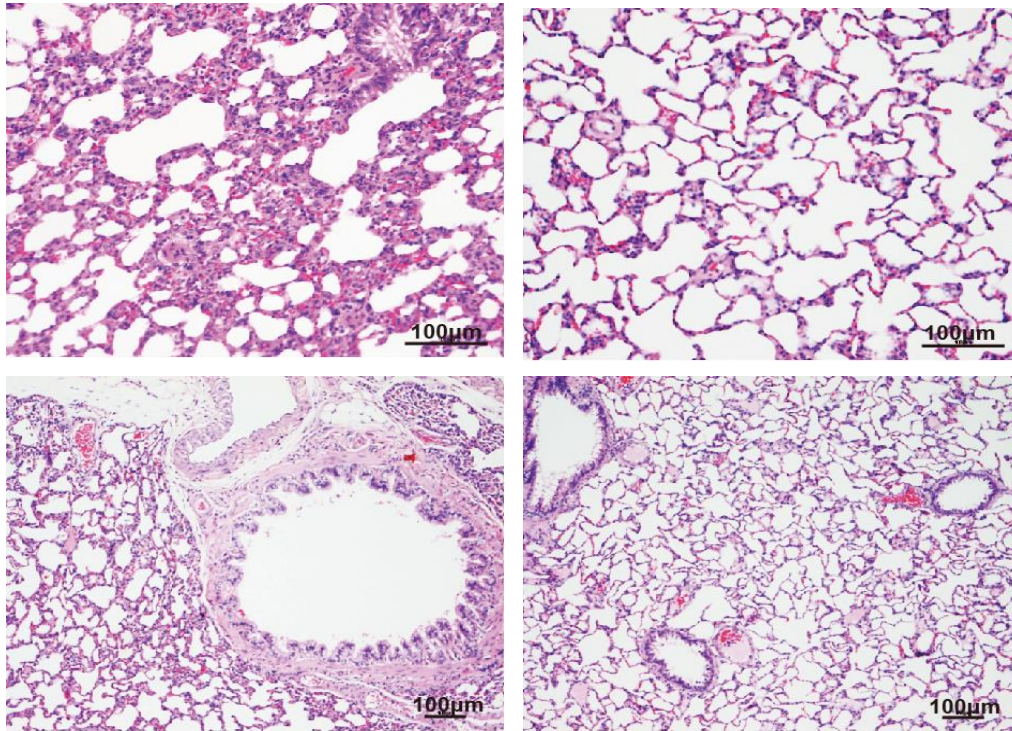Fig S1. Lung histology (HE Stained) of 8-week-old rats, showing inflammation in the alveolus of a rat exposed to unfiltered air (top left) compared to the alveolus of a rat exposed to filtered air exposure (top right). Similar histological evidence for inflammation in the bronchus of an unfiltered air exposed rat (bottom left) in reference to that of a filtered air exposed rat (bottom right).

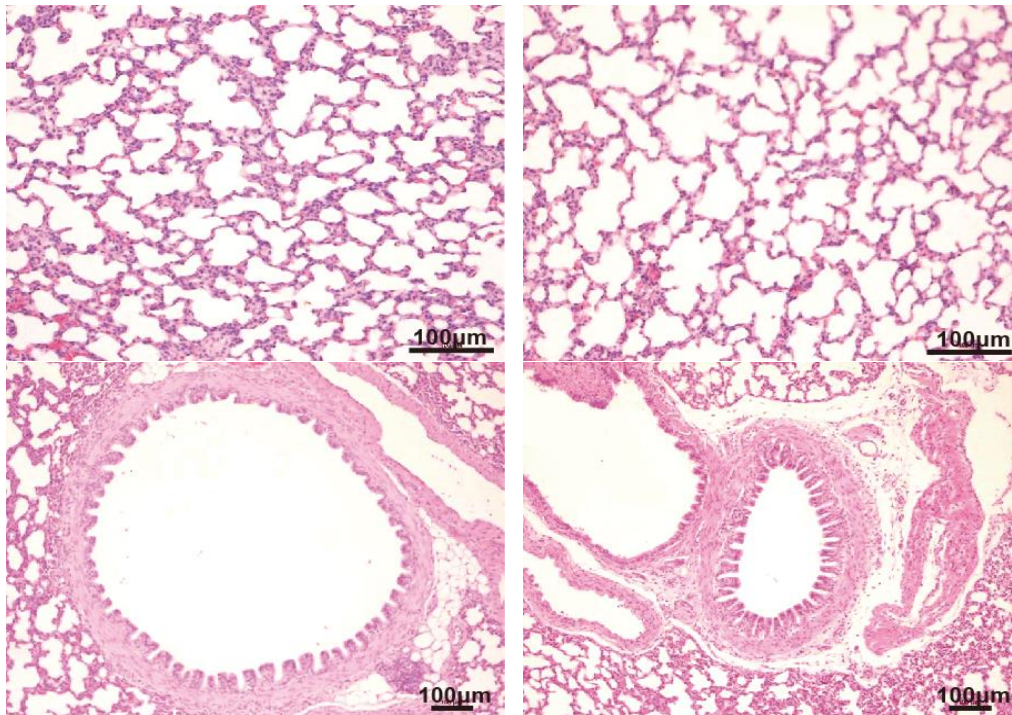


Fig S2. Lung histology (HE Stained) of 3-week old rats, showing no difference in inflammation status between rats exposed to unfiltered Beijing air and those exposed to filtered air. Top left: the alveolus of a rat exposed to unfiltered air. Top right: the alveolus of a rat exposed to filtered air. Bottom left: the bronchus of a rat exposed to unfiltered air. Bottom right: the bronchus of a rat exposed to filtered air.