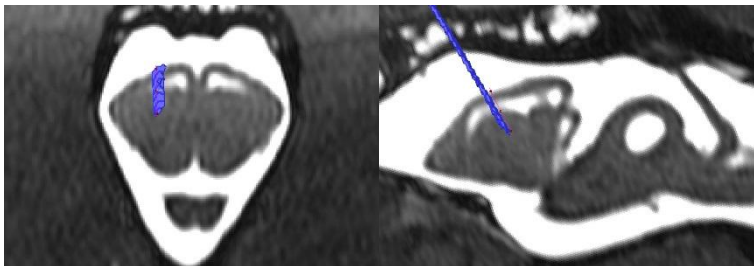
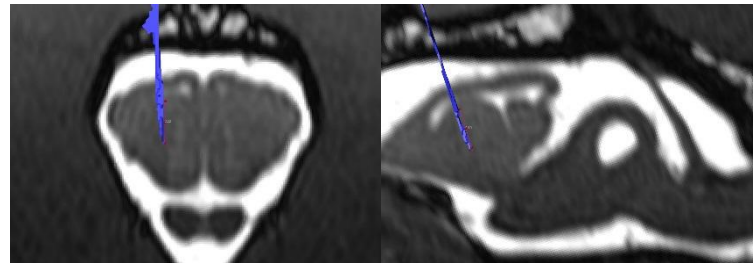


Dorso Ventricular Ridge + Dorsal Cortex

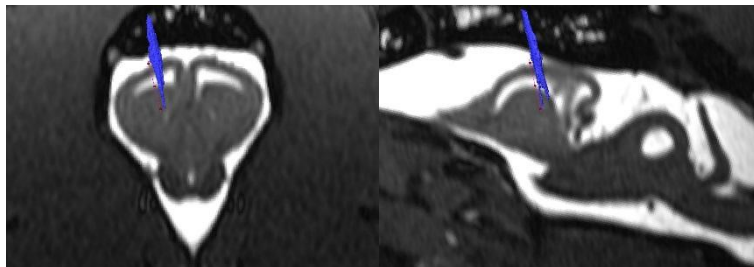
#1



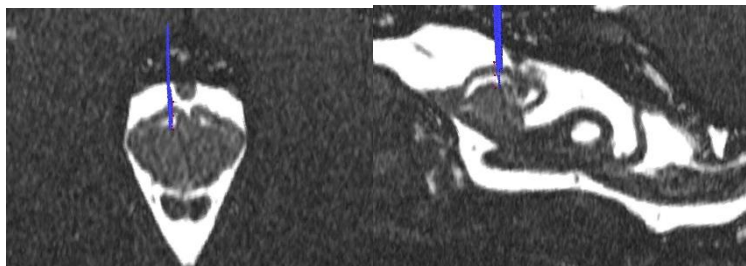
#2



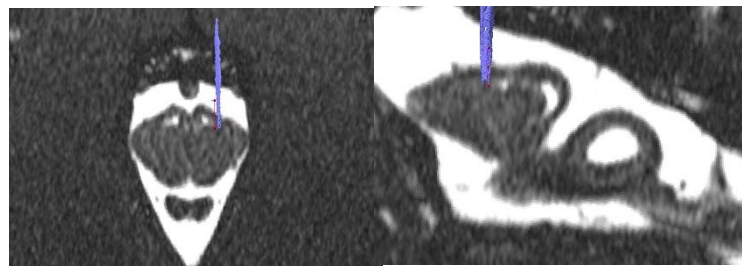
#3



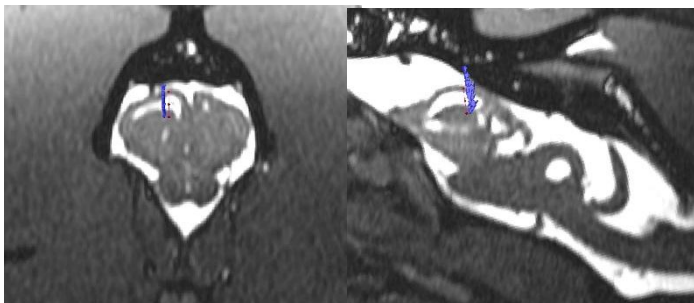
#5



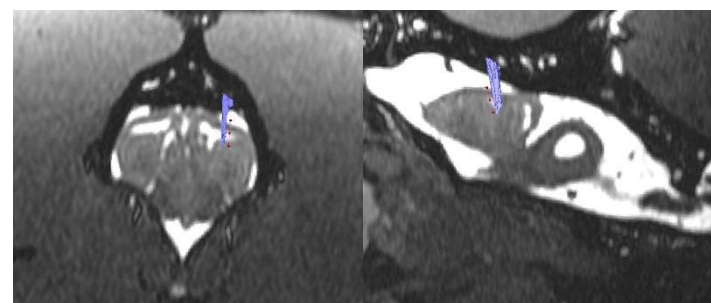
#5



#6

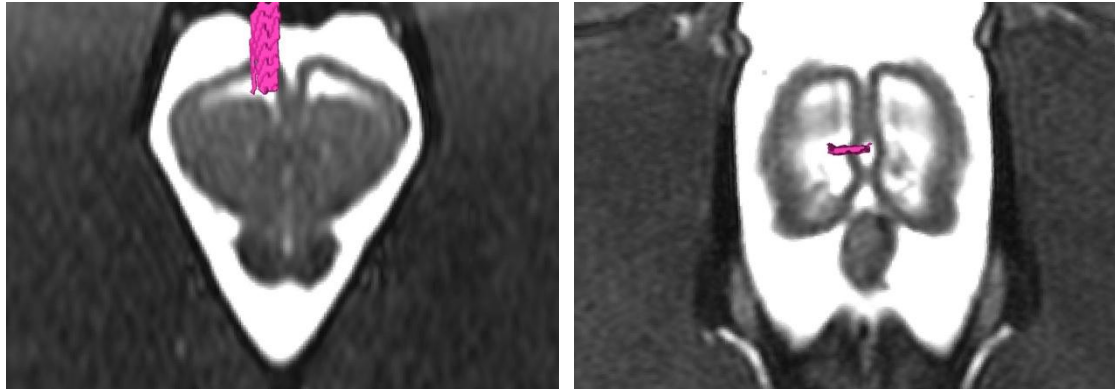


#6

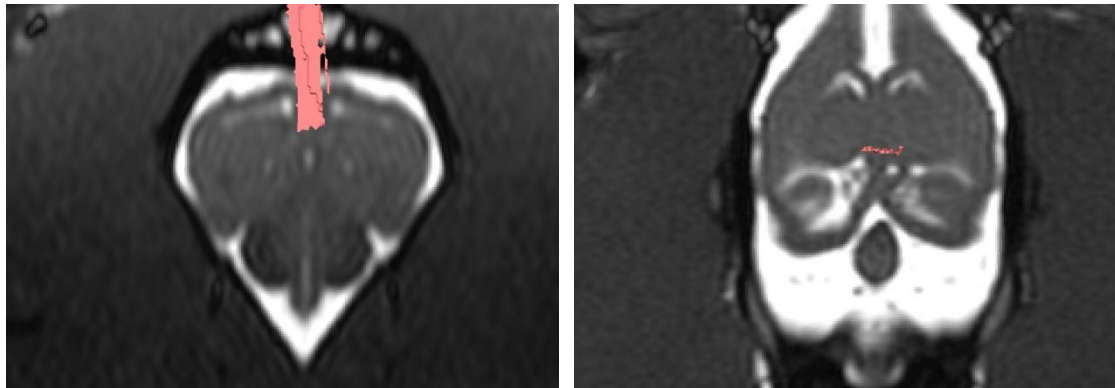


Medial Cortex

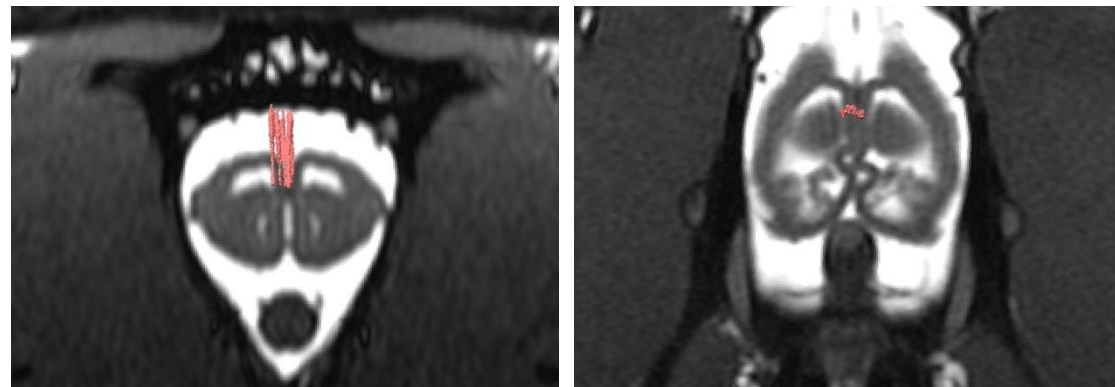
#1



#2

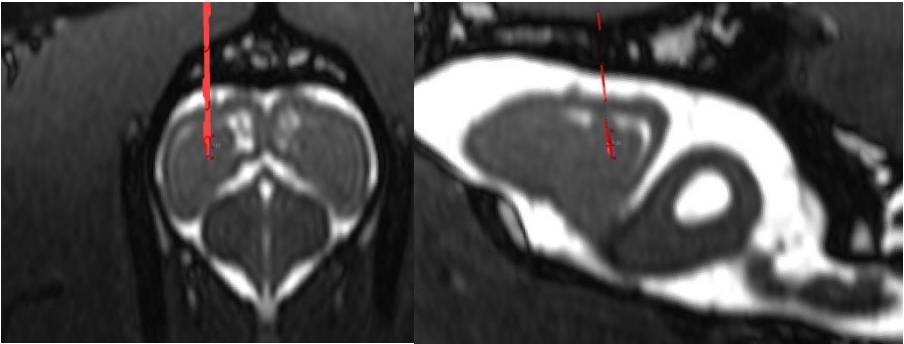


#3

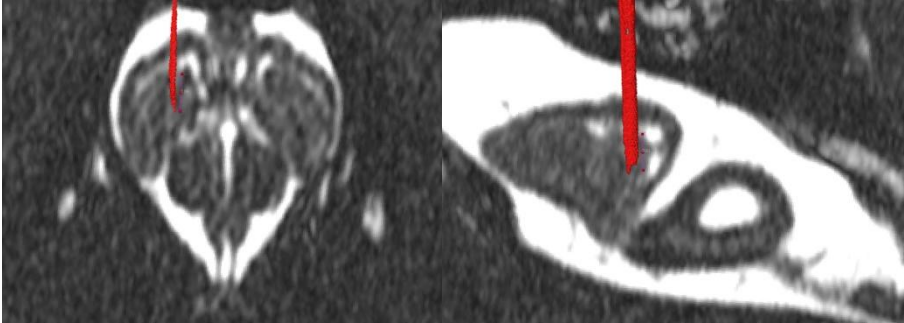


Nucleus sphericus without Dorsal cortex

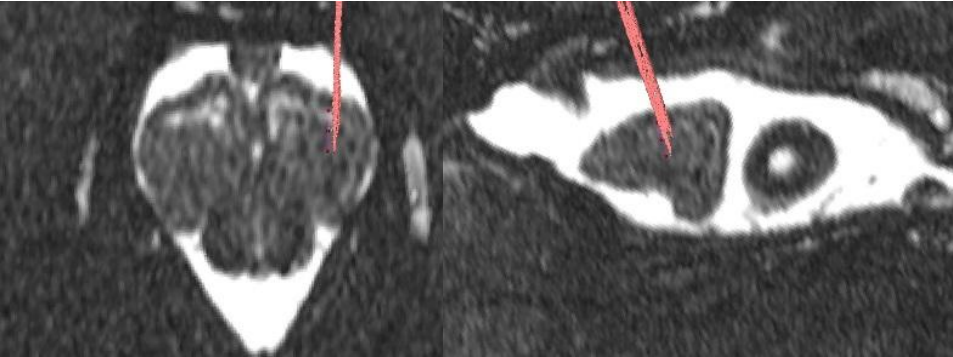
#1



#4

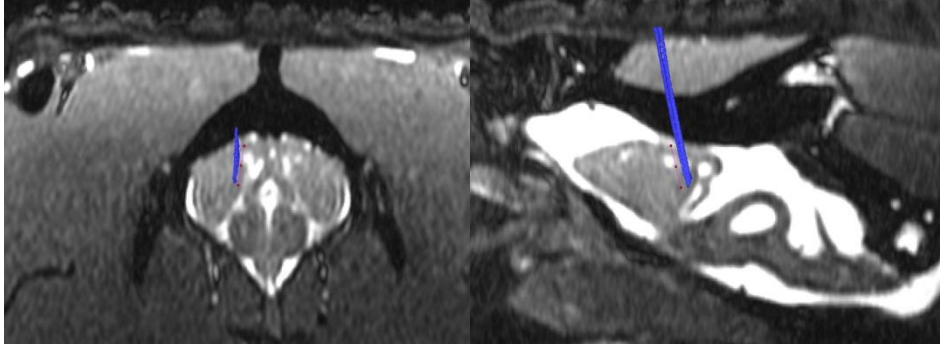


#4

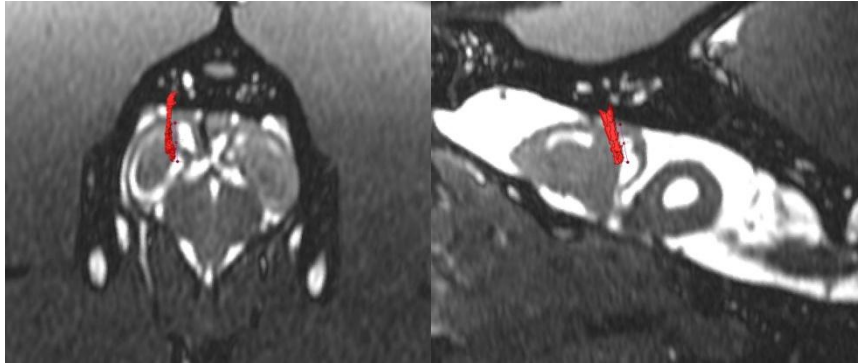


Nucleus sphericus with Dorsal cortex

#4

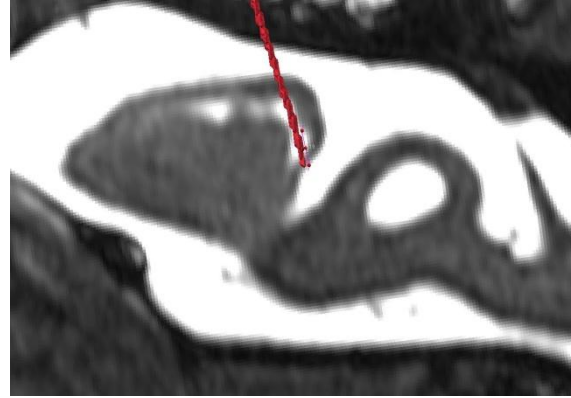
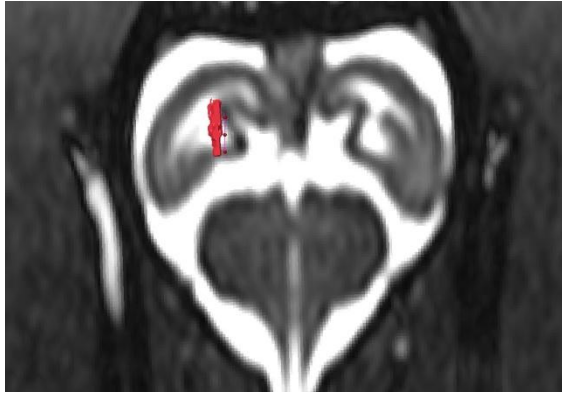

#6

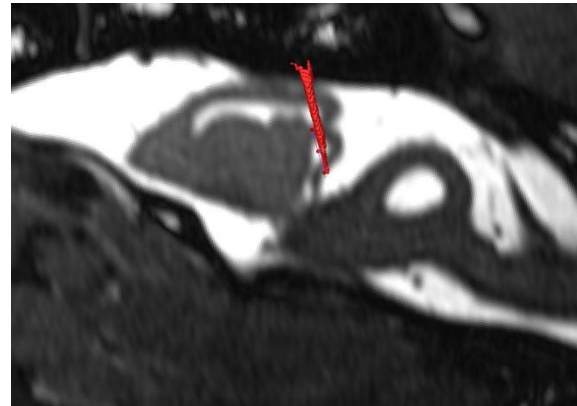
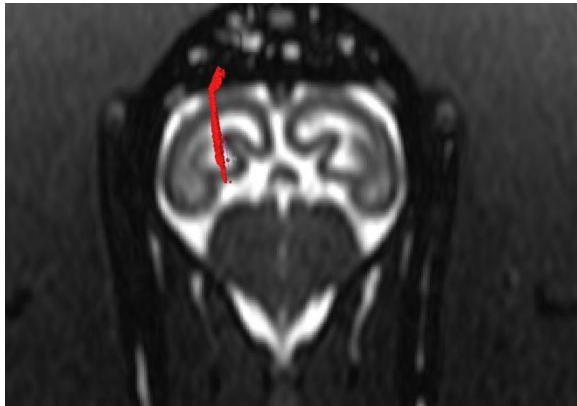


Caudal Medial Cortex

#1



#3



#6

