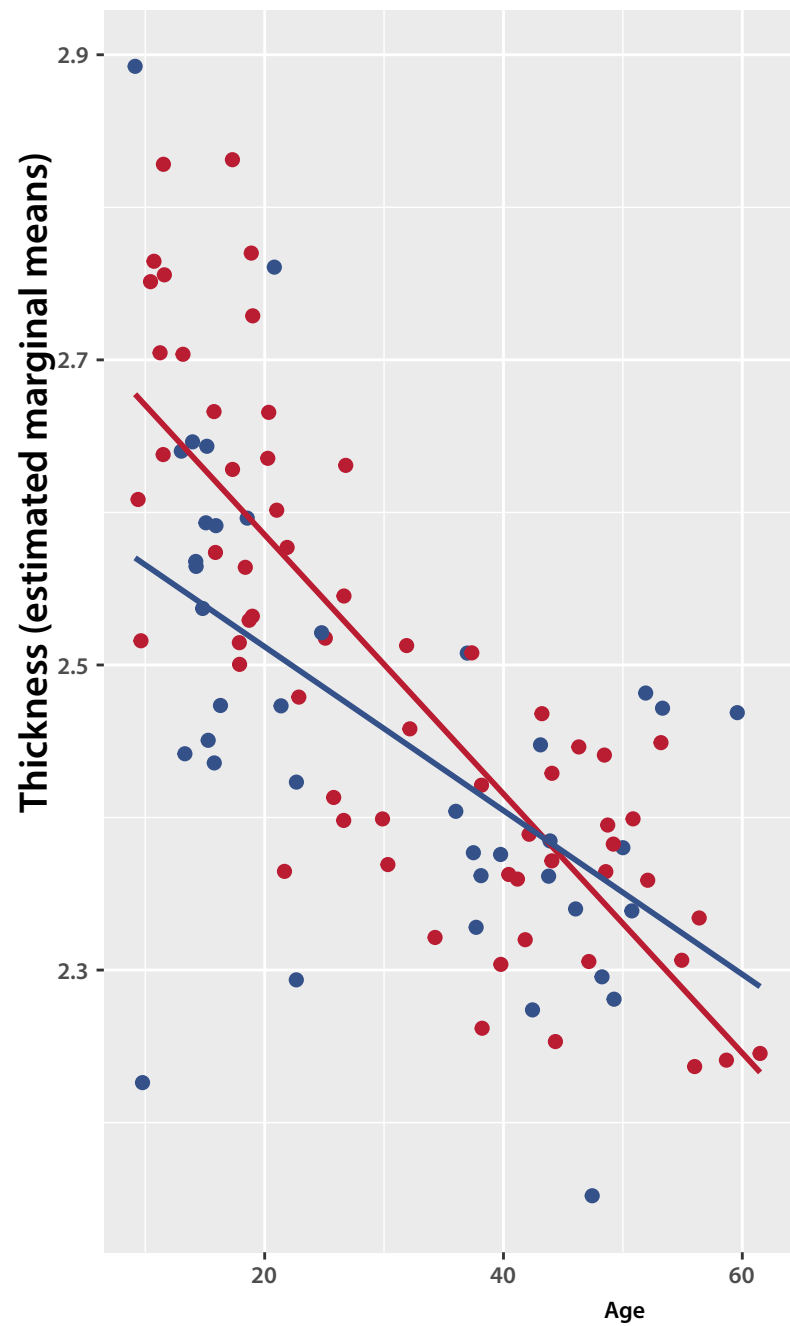


Right rostral middle frontal gyrus



Left supramarginal gyrus

