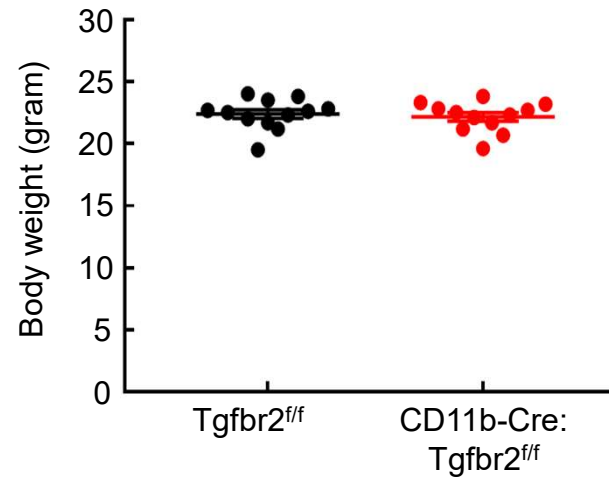
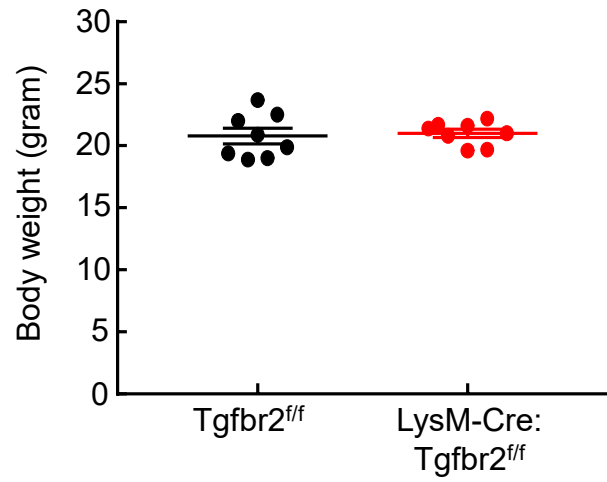
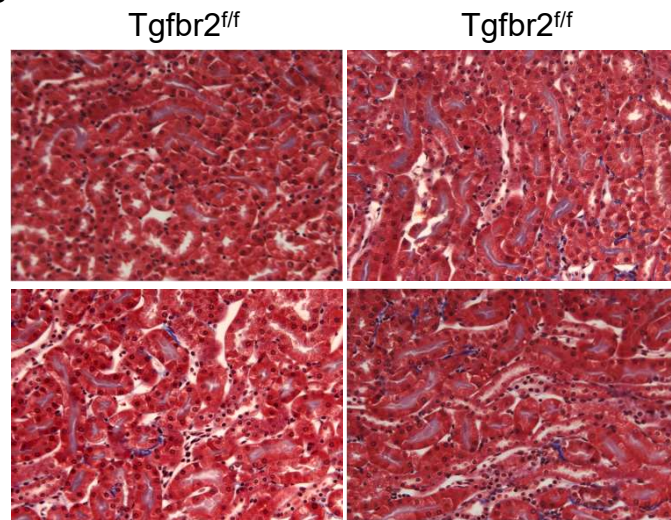


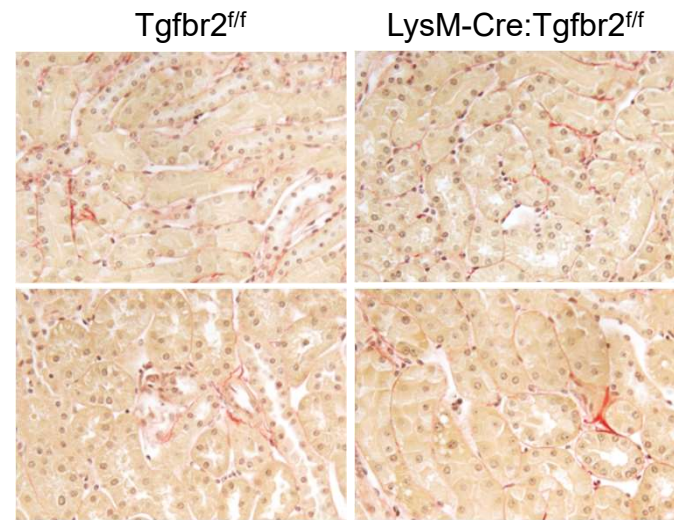
A



B

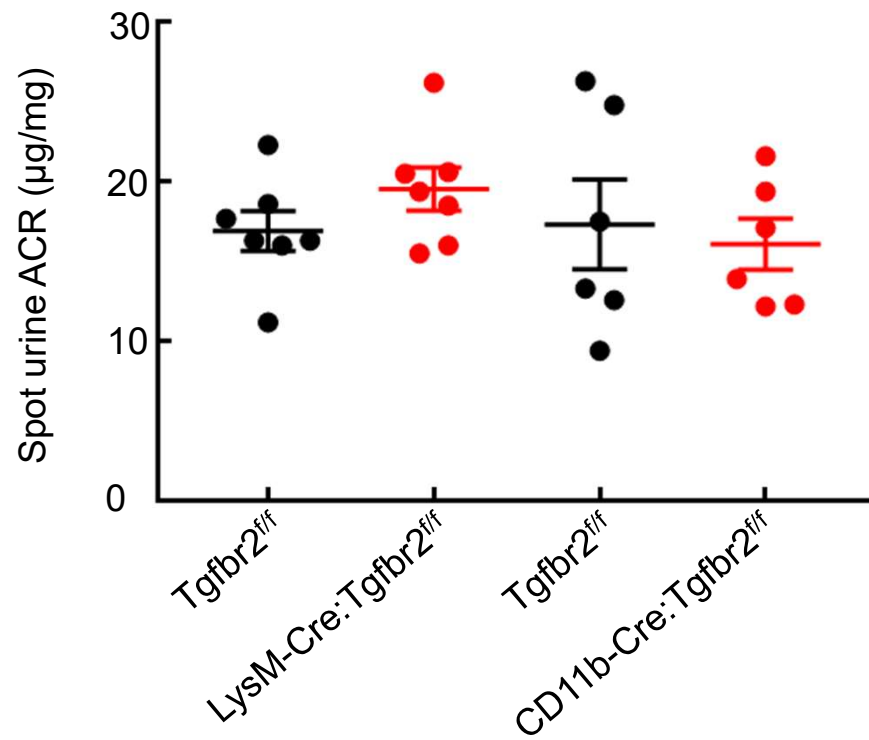


Masson's Trichrome staining: x 160

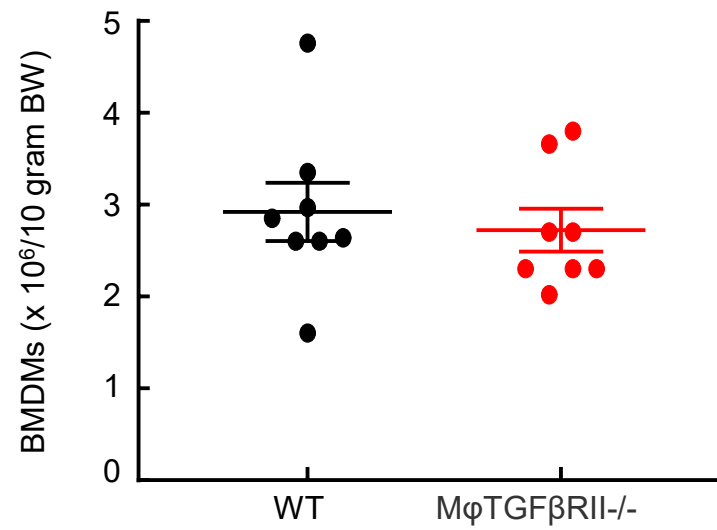


Sirius red staining: x 160

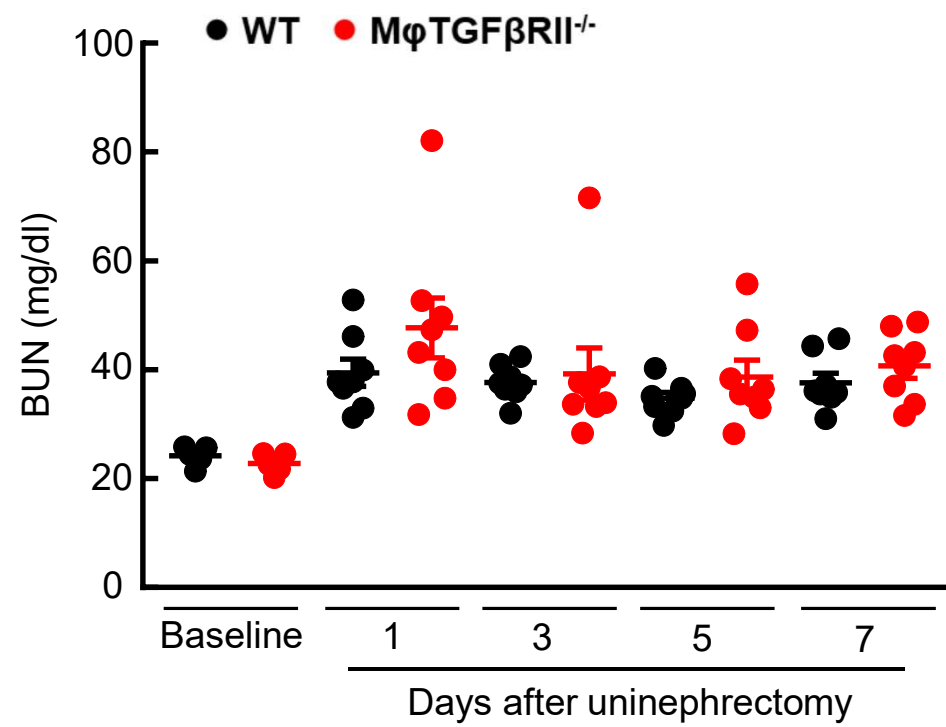
Supplemental Figure S1



Supplemental Figure S2

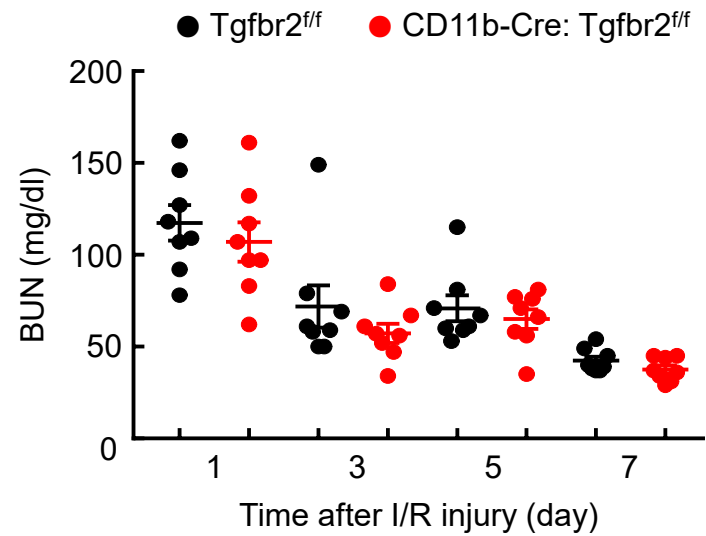
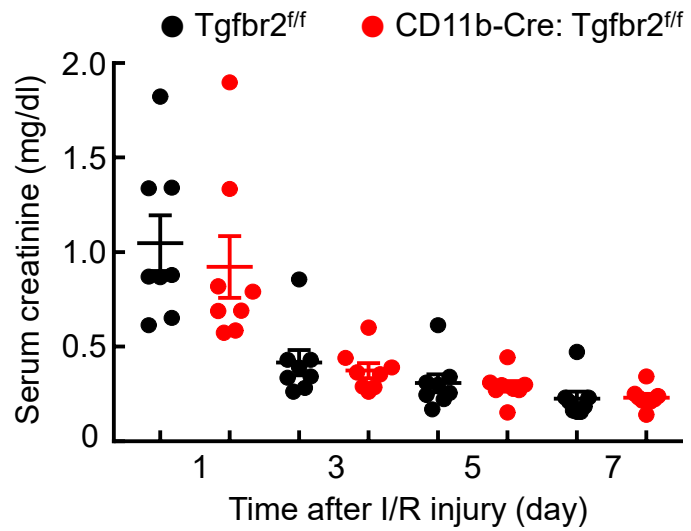


Supplemental Figure S3

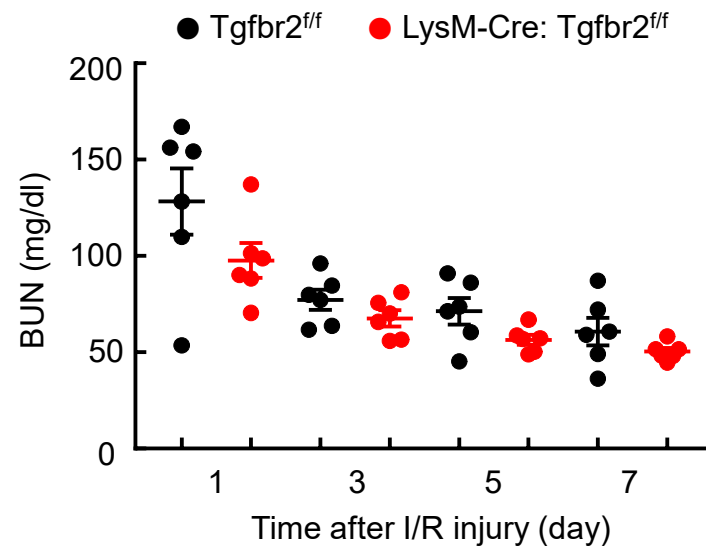
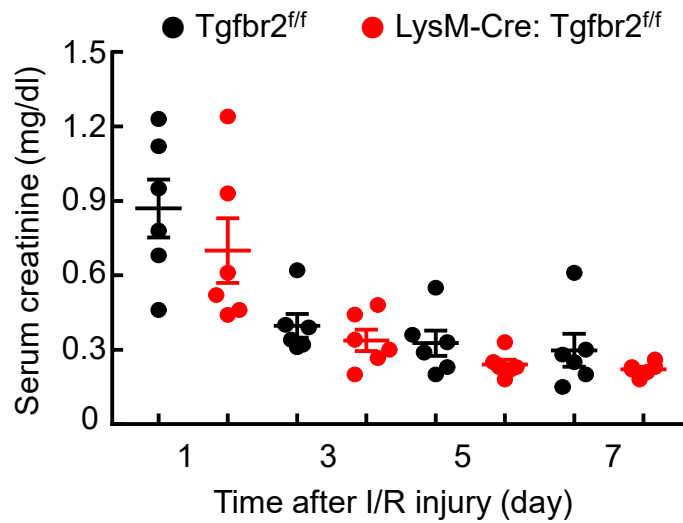


Supplemental Figure S4

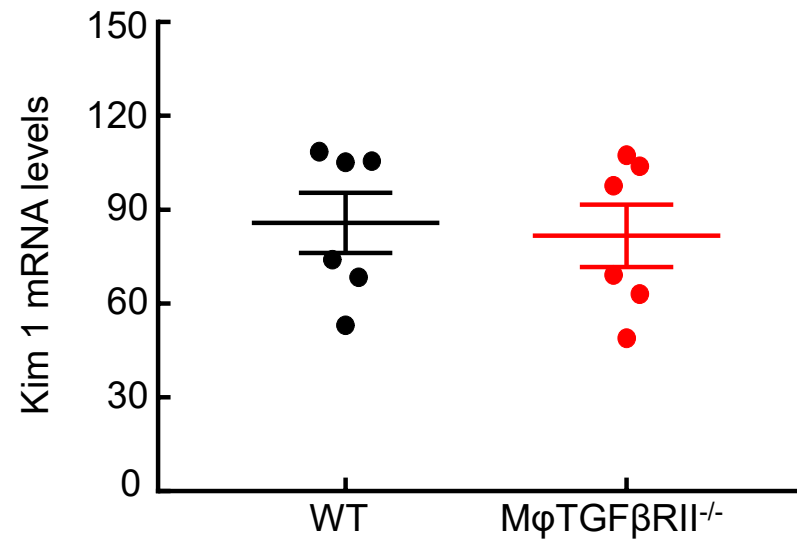
A



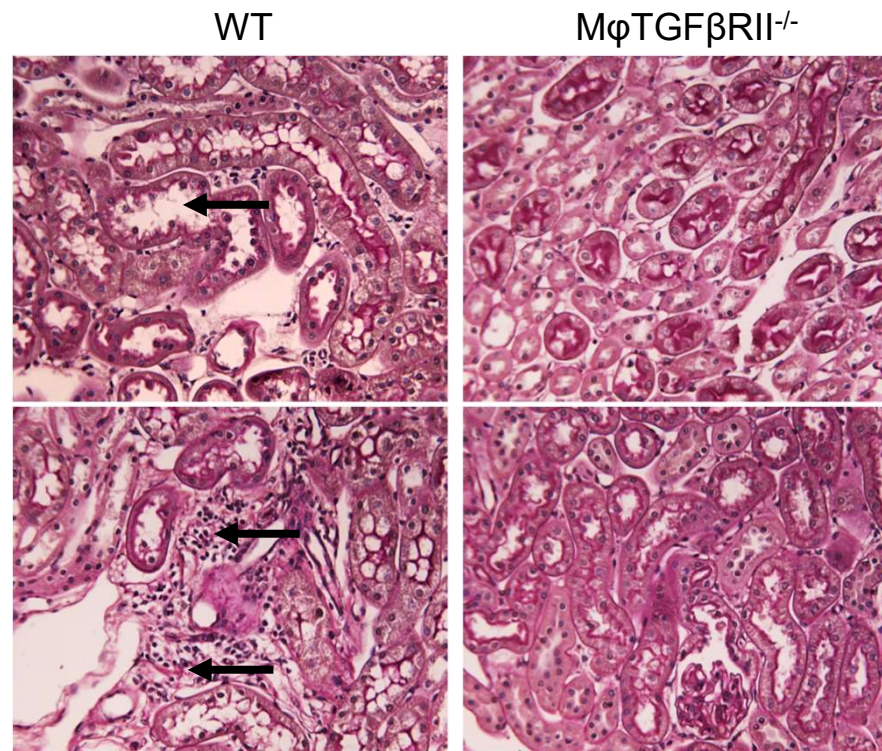
B



Supplemental Figure S5

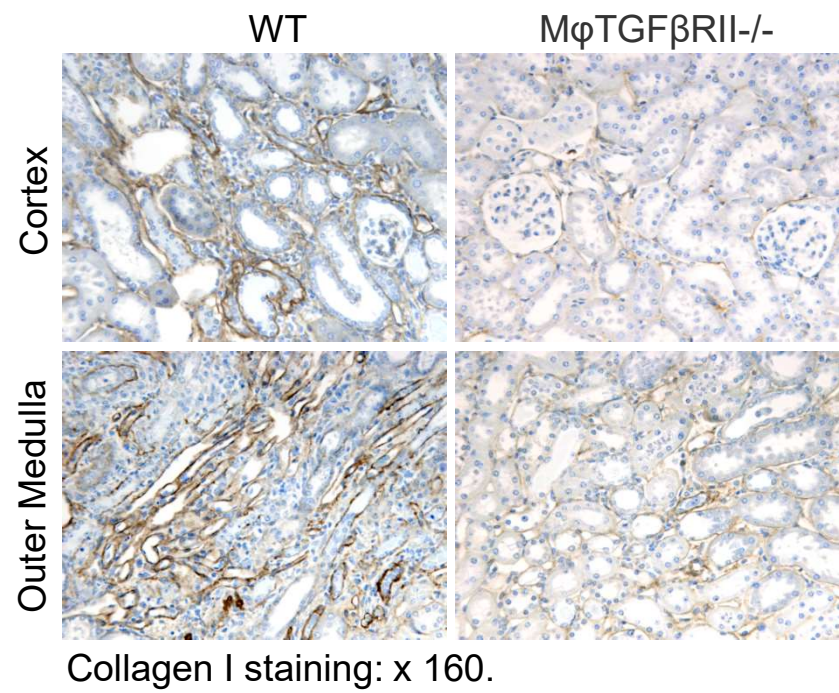
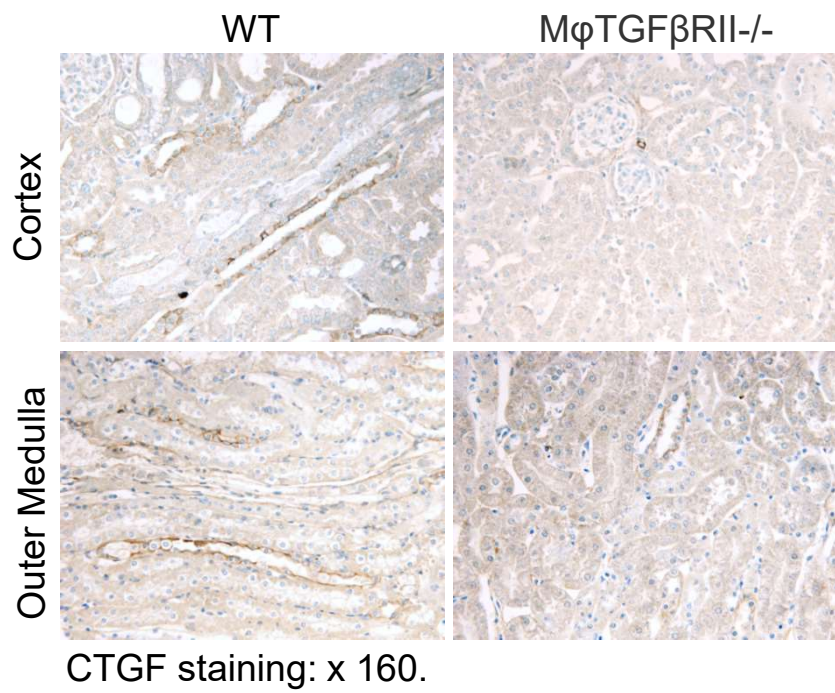


Supplemental Figure S6

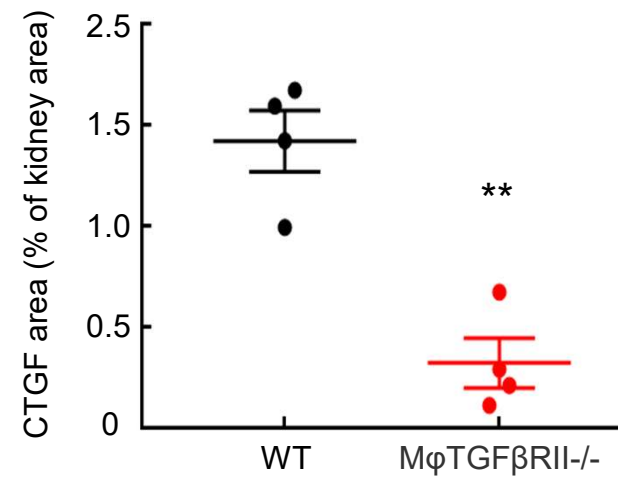
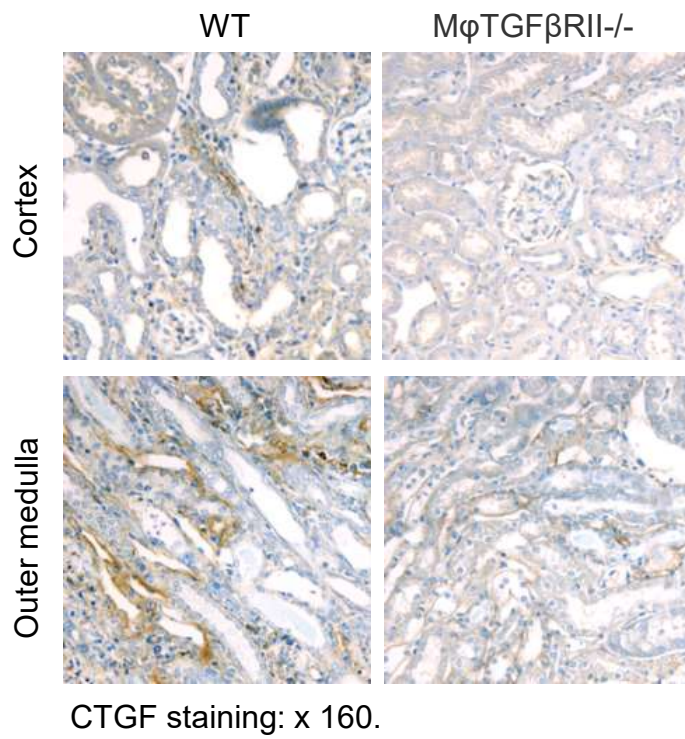


The Periodic Acid-Schiff staining: x 160.

Supplemental Figure S7



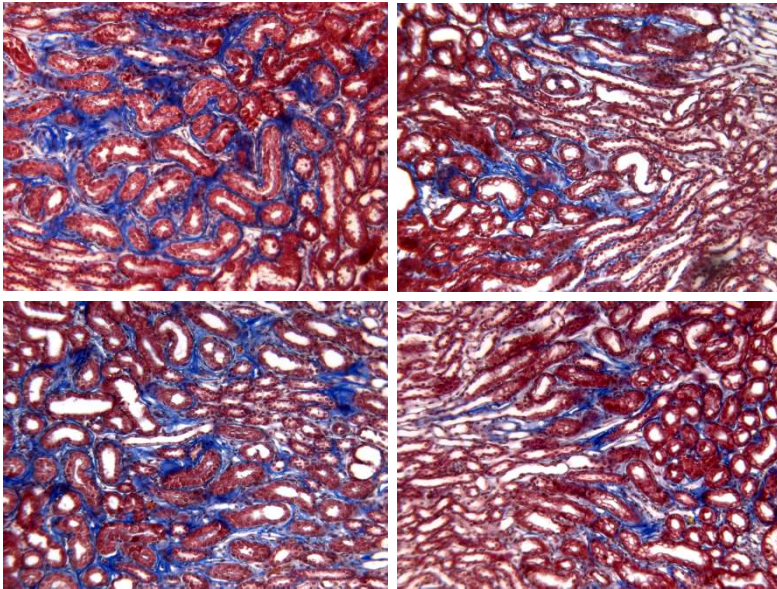
Supplemental Figure S8



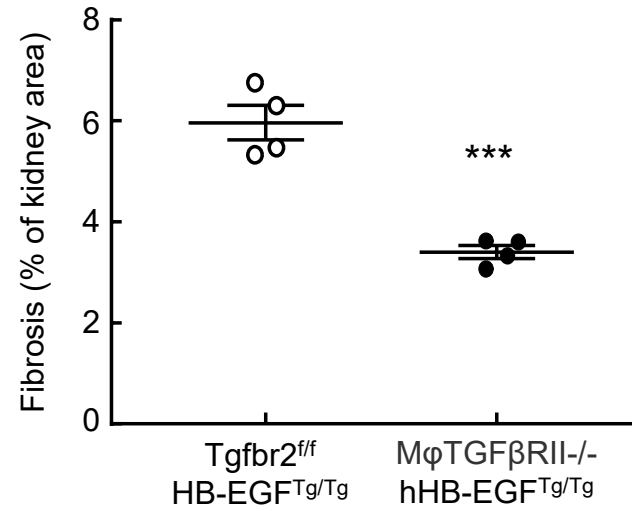
Supplemental Figure S9

Tgfr2^{ff}
HB-EGF^{Tg/Tg}

MφTGFβRII^{-/-}
hHB-EGF^{Tg/Tg}

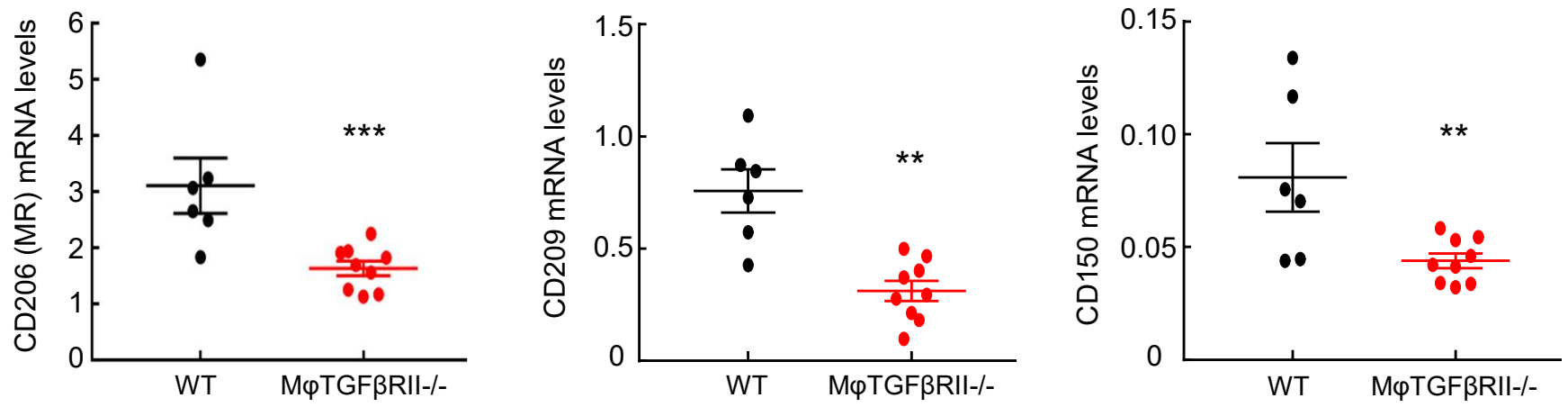


Masson's Trichrome staining: x 100.

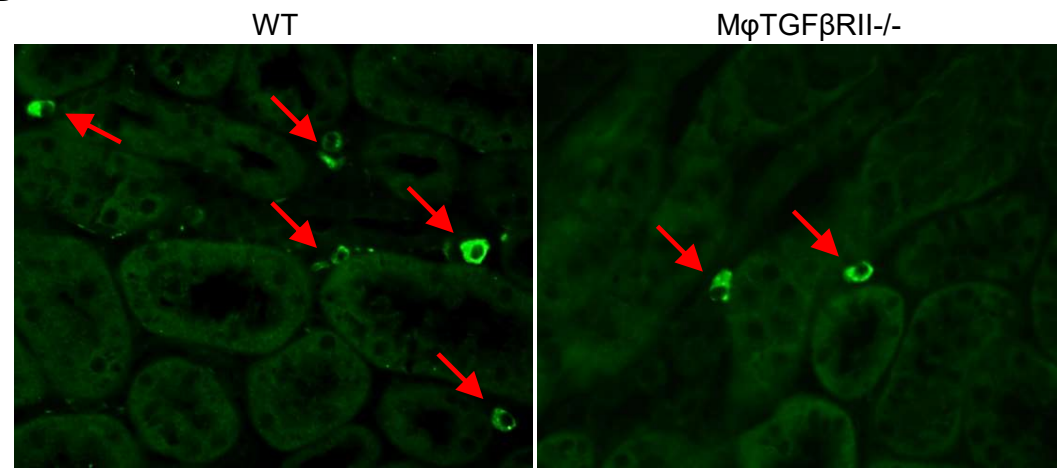


Supplemental Figure S10

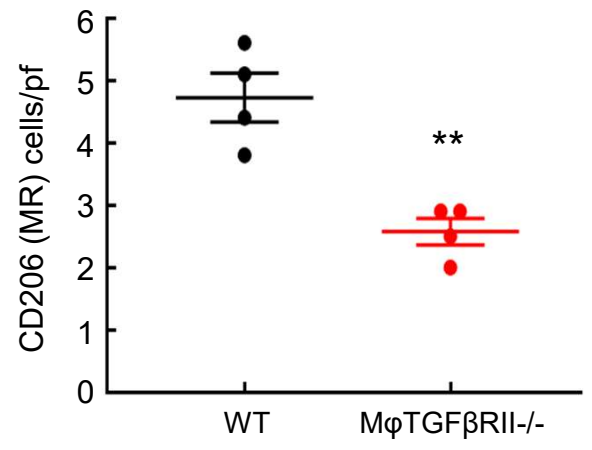
A



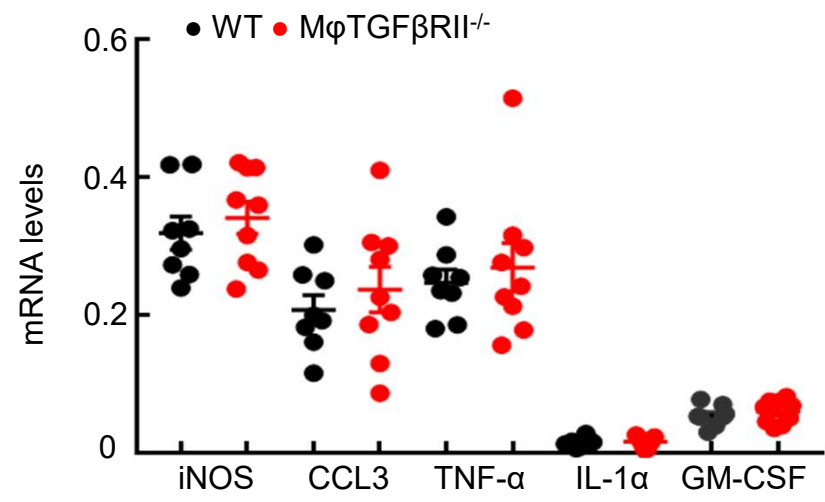
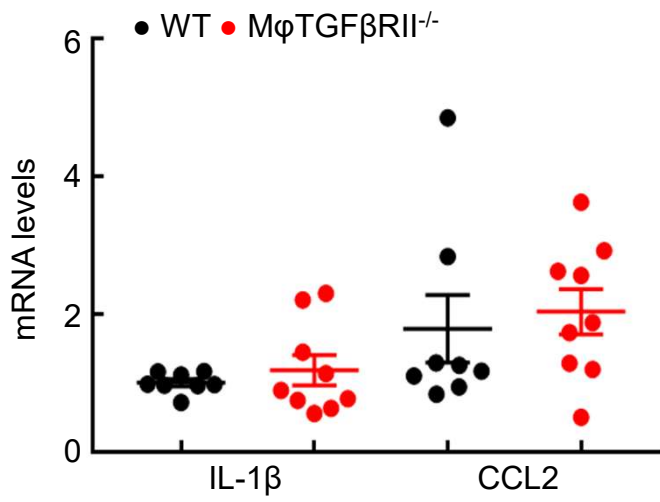
B



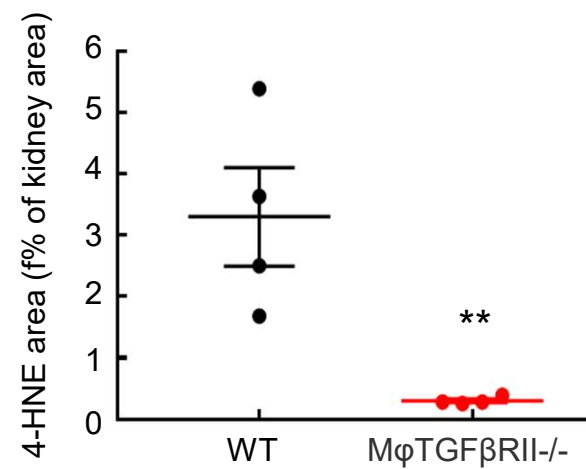
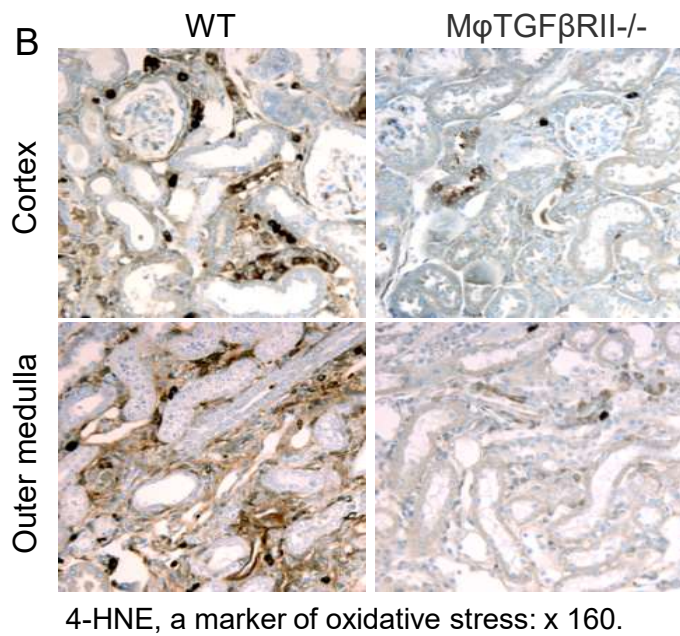
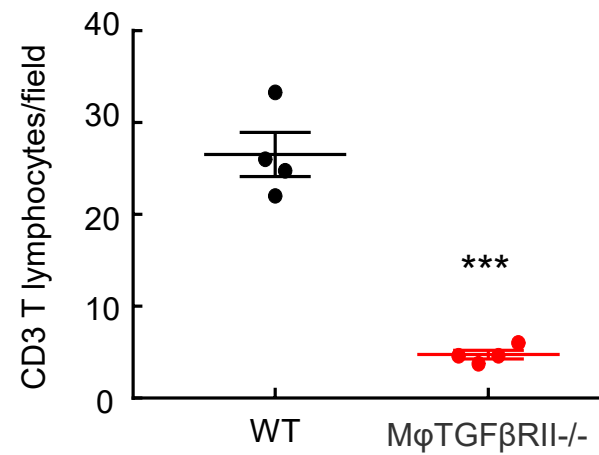
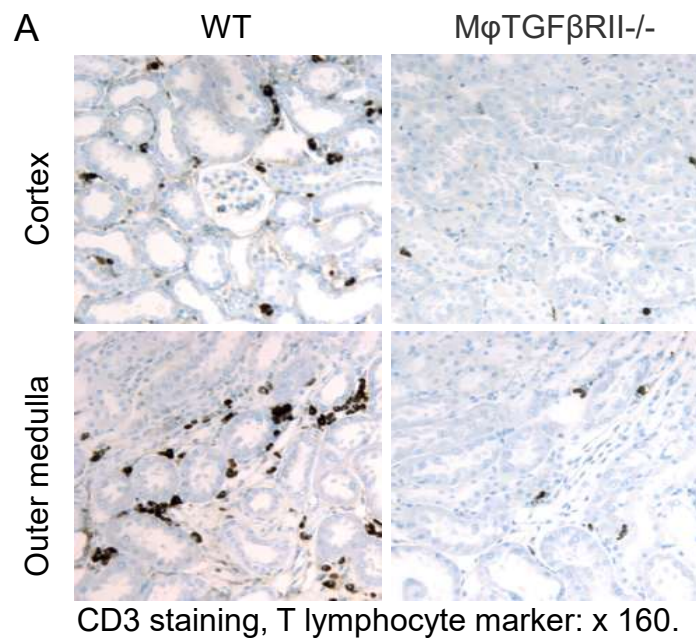
CD 206 (MR) staining: x 400.



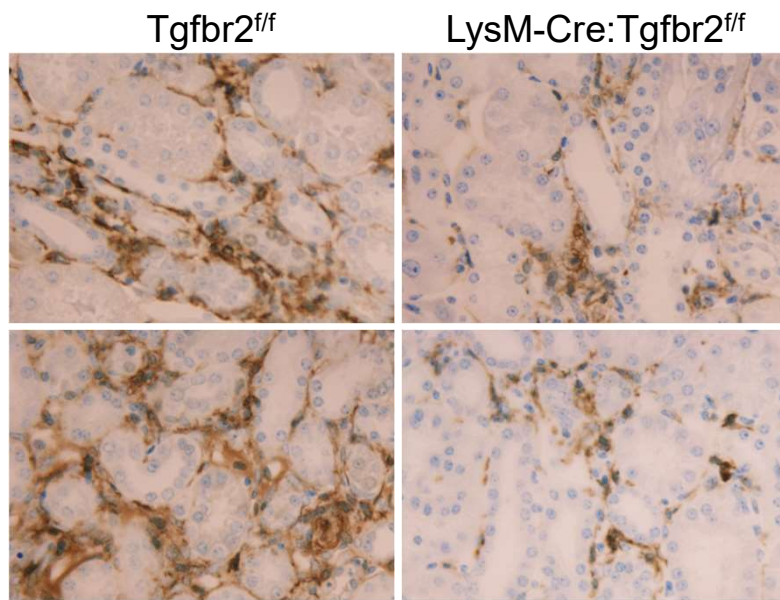
Supplemental Figure S11



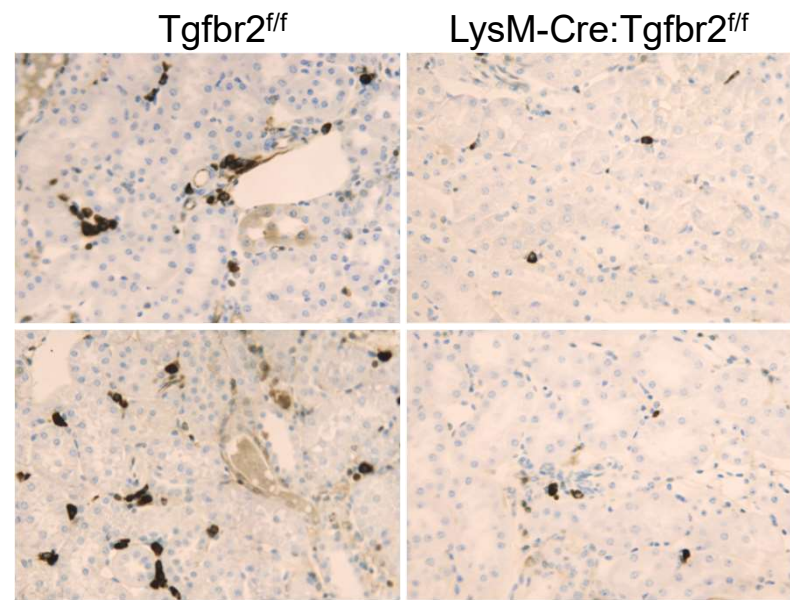
Supplemental Figure S12



Supplemental Figure S13

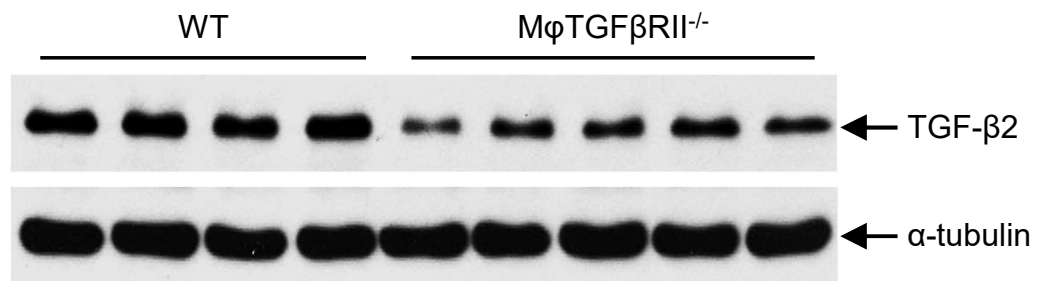
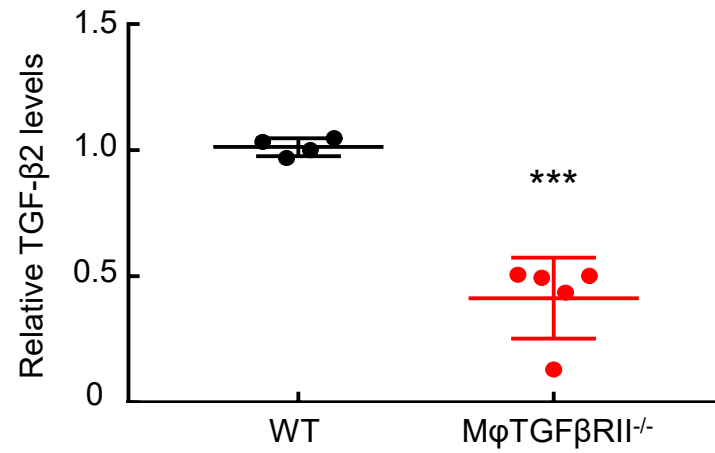


F4/80 staining, macrophage marker: x 250



CD3 staining, T lymphocyte marker: x 160

Supplemental Figure S14



Supplemental Figure S15