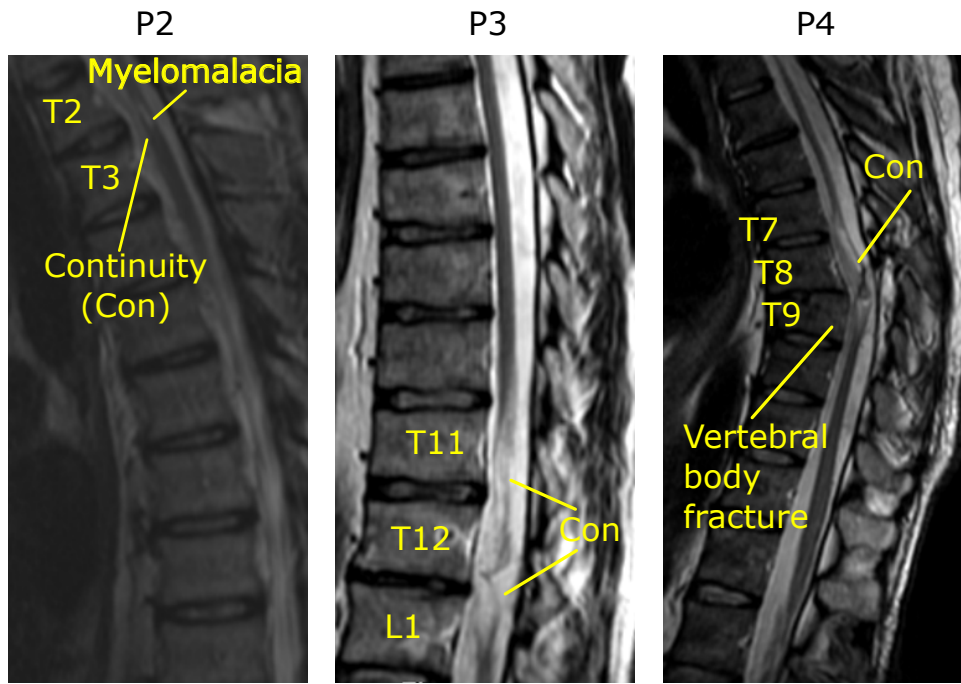



A. Spinal cord MRI Sagittal plane



C. Spinal cord 3D visualisation



B. Spinal cord MRI Axial plane

