

Prognostic factors of Erdheim–Chester disease: a nationwide survey in Japan

Takashi Toya,^{1*} Mizuki Ogura,^{1*} Kazuhiro Toyama,² Akihide Yoshimi,¹ Aya Shinozaki-Ushiku,³ Akira Honda,¹ Kenjiro Honda,⁴ Noriko Hosoya,⁵ Yukako Murakami,⁶ Hiroyuki Kawashima,⁷ Yasuhito Nannya,¹ Shunya Arai,¹ Fumihiko Nakamura,¹ Yusuke Shinoda,⁸ Masaomi Nangaku,⁴ Kiyoshi Miyagawa,⁵ Masashi Fukayama,³ Akiko Moriya-Saito,⁹ Ichiro Katayama,⁶ Takashi Ogura¹⁰ and Mineo Kurokawa^{1,2}

¹Department of Hematology & Oncology, Graduate School of Medicine, The University of Tokyo; ²Department of Cell Therapy and Transplantation Medicine, The University of Tokyo Hospital; ³Department of Pathology, Graduate School of Medicine, The University of Tokyo; ⁴Division of Nephrology and Endocrinology, The University of Tokyo Graduate School of Medicine; ⁵Laboratory of Molecular Radiology, Center for Disease Biology and Integrative Medicine, Graduate School of Medicine, The University of Tokyo; ⁶Department of Dermatology, Osaka University Graduate School of Medicine; ⁷Division of Orthopedic Surgery, Niigata University Graduate School of Medical and Dental Sciences; ⁸Department of Rehabilitation Medicine Graduate School of Medicine, The University of Tokyo; ⁹Clinical Research Center, National Hospital Organization Nagoya Medical Center, Aichi and ¹⁰Department of Respiratory Medicine, Kanagawa Cardiovascular and Respiratory Center, Yokohama, Japan

**TT and MO contributed equally to this work*

©2018 Ferrata Storti Foundation. This is an open-access paper. doi:10.3324/haematol.2018.190728

Received: February 8, 2018.

Accepted: July 4, 2018.

Pre-published: July 5, 2018.

Correspondence: kurokawa-ty@umin.ac.jp

Supplementary Data

Supplementary Table S1. First signs and involved organs in the clinical course

UP N	Age at onset	First signs	Involved organs	Outcome (survival year from onest)	REF
1	49	Bone pain	Bone, digestive organ (liver), kidney and retroperitoneal organ (renal infiltration), skin (erythema), breast, gingiva, lymph node	Alive (2.83+)	1
2	44	Xanthelasma	Bone, cardiovascular system (LVH, PE, coated aorta), endocrine organ (hypopituitarism), kidney and retroperitoneal organ (hydronephrosis), skin (xanthelasma)	Dead (10.92)	2,3
3	30	Bone pain, DI, fever	Bone, cardiovascular system (palpitation), endocrine organ (DI)	Alive (6.92+)	4,5
4	44	Fever, malaise	Bone, lung (interlobular septal thickening, cyst)	Dead (5.75)	N/A
5	40	DI	CNS (exophthalmos), endocrine organ (DI)	Dead (7.83)	N/A
6	41	Bone pain, fever	Bone	Alive (13.25)	6
7	67	Dyspnea	Bone, cardiovascular system (cardiac tamponade, coated aorta), CNS (exophthalmos, spinal tumor), digestive organ (liver, pancreas), kidney and retroperitoneal organ (hydronephrosis), lung (pleural thickening and fibrosis), adrenal gland, bladder, spleen, testis	Dead (0.58)	N/A
8	40	Bone pain	Bone, skin (papule)	Alive (10.08+)	N/A
9	68	Fever, malaise	Bone, CNS (meningeal tumor), glottis	Alive (1.08+)	N/A
10	33	Bone pain, fever	Bone	Alive (3.92+)	N/A
11	68	Bone pain, malaise	Bone	Alive (3.75+)	N/A
12	41	Bone pain, vertigo	Bone, CNS (parenchymal mass)	Alive (6.50+)	N/A
13	28	DI, xanthelasma	Bone, endocrine organ (DI), skin (xanthelasma)	Alive (5.25+)	N/A
14	56	Low vision	Cardiovascular system (coated aorta), CNS (exophthalmos), endocrine organ (hypothyroidism), kidney and retroperitoneal organ (hydronephrosis), skin (xanthelasma)	Dead (4.58)	7
15	44	Femoral tumor	Skin (subcutaneous tumor)	Alive (1.00+)	N/A
16	59	Body weight loss	Bone, cardiovascular system (coated aorta), endocrine organ (hypopituitarism), kidney and retroperitoneal organ (hydronephrosis), skin (xanthelasma)	Alive (3.58+)	N/A
17	53	Xanthelasma	Bone, endocrine organ (DI), kidney and retroperitoneal organ, skin (xanthelasma)	Alive (5.33+)	N/A
18	65	DI	Bone, cardiovascular system (heart failure, LVH, coated aorta), CNS (impaired consciousness), digestive organ (pancreatomegaly), endocrine organ (DI), kidney and retroperitoneal organ (hairy kidney), lung (details unknown)	Alive (2.75+)	N/A

19	40	Bone pain	Bone	Alive (10.08+)	N/A
20	68	Incidentally detected pulmonary infiltration	Bone, CNS (meningeal tumor), endocrine organ (pituitary tumor), cardiovascular system (heart failure), lung (centrilobular shadow, pleural thickening, fibrosis and pneumosclerosis)	Dead (4.50)	N/A
21	45	DI	Bone, CNS (cerebellar ataxia, exophthalmos), endocrine organ (DI), cardiovascular system (cardiac tamponade, mitral regurgitation, carotid stenosis), lung (cyst), kidney and retroperitoneal organ (retroperitoneal fibrosis, renal artery stenosis)	Alive (6.42+)	N/A
22	67	Dysarthria, vertigo, vomiting	CNS (cerebellar ataxia, meningeal tumor), kidney and retroperitoneal organ (hairy kidney)	Dead (0.25)	N/A
23	46	Dyspnea	Bone, cardiovascular system (heart failure, pulmonary hypertension), lung (interlobular septal thickening)	Dead (11.33)	N/A
24	27	Malaise	Bone, cardiovascular system (right atrial tumor), lung (cyst, obstructive disorder), kidney and retroperitoneal organ, skin (xanthelasma), gingiva, sinus	Alive (13.25+)	N/A
25	46	Bone pain	Bone, cardiovascular system (PE, coated aorta), CNS (parenchymal mass), digestive organ, endocrine organ (DI), kidney and retroperitoneal organ (hairy kidney, hydronephrosis)	Dead (3.58)	8,9
26	49	Dyspnea	Bone, lung (cyst, pleural thickening)	Alive (7.08+)	10
27	25	DI	Bone, endocrine organ (DI), kidney and retroperitoneal organ (hydronephrosis), skin (xanthelasma)	Dead (14.58)	11, 12
28	76	edema	Bone, CNS (papilledema), cardiovascular system (PE), kidney and retroperitoneal organ (hairy kidney), breast	Dead (2.25)	13
29	40	Amenorrhea, DI, malaise	Bone, CNS (parenchymal mass), endocrine organ (hypopituitarism), lung (detail unknown)	alive (4.00+)	N/A
30	62	Fever, malaise	Bone, CNS (parenchymal mass), skin (tumor), oral mucosa	Dead (0.75)	N/A
31	57	Dyspnea, fever, general malaise	Bone, cardiovascular system (cardiac tamponade), kidney and retroperitoneal organ (hydronephrosis, peritoneal fibrosis)	Alive (6.67+)	N/A
32	62	Pericardial effusion	cardiovascular system (cardiac tamponade, right atrium tumor), CNS (subdural tumor), skin (xanthelasma)	Dead (4.33)	14
33	48	Bone pain	Bone, skin (xanthelasma)	Alive (21.08+)	N/A
35	58	Neck pain, numbness	Bone, CNS (parenchymal mass), kidney and retroperitoneal organ (hairy kidney, renal hypertension)	Alive (5.08+)	N/A
36	72	Bone pain, fever	Bone, cardiovascular system (PE, atrioventricular block), CNS (cerebellar ataxia), endocrine organ (hypopituitarism), kidney and retroperitoneal organ (hydronephrosis), skin (erythema)	Alive (1.67+)	N/A
37	66	Numbness	Bone, cardiovascular system (coronary artery disease, coated aorta), CNS (parenchymal mass), skin (xanthelasma), lymph node	Dead (1.83)	N/A
38	67	Dry cough, fever	Cardiovascular system (mitral regurgitation, right bundle branch block), CNS (pia mater involvement), digestive organ (liver, pancreas, esophagus, stomach, intestine, colon) , endocrine organ (pituitary tumor),	Dead (0.83)	N/A

			lung (fibrosis, interlobular septal and pleural thickening), kidney and retroperitoneal organ (hairy kidney), skin (erosion), bone marrow, lymph node, spleen		
39	54	Bone pain	Bone	Alive (1.83+)	N/A
40	56	Bone pain, fever	Bone, cardiovascular system (coronary artery disease, mitral regurgitation, coated aorta), CNS (parenchymal mass), endocrine organ (DI), kidney and retroperitoneal organ (hairy kidney), lung (interlobular septal and pleural thickening)	Dead (7.42)	N/A
41	47	Bone pain, fever	Bone, cardiovascular system (pericarditis, coated aorta), CNS (exophthalmos), kidney and retroperitoneal organ (hydronephrosis), skin (phlebitis-like rash)	Dead (10.42)	N/A
42	66	Bone pain, headache	Bone, cardiovascular system (coated aorta), CNS (meningeal and parenchymal tumor), endocrine organ (DI), kidney and retroperitoneal organ (hilar tumor), lung (interlobular thickening)	Alive (3.17+)	N/A
43	70	Dyspnea	Bone, cardiovascular system (PE), kidney and retroperitoneal organ (hairy kidney), skin (xanthelasma)	Alive (1.17+)	N/A
44	23	Bone pain	Bone, cardiovascular system (right coronary invasion), CNS (parenchymal mass), endocrine organ (DI), kidney and retroperitoneal organ (hydronephrosis), lung (interlobular thickening)	Alive (11.08+)	N/A
45	68	Bone pain, dyschezia	Bone, digestive organ (rectal tumor), prostate	Dead (0.83)	N/A

UPN indicates unique patient number; REF indicates Supplemental references listed below and N/A indicates that no article about the patient has been reported; CNS indicates central nervous system; DI indicates diabetes insipidus; PE indicates pericardial effusion; LVH indicates left ventricular hypertrophy

Supplementary Table S2. Cause of death

UPN	Cause of death
2	Unknown
4	ECD
5	Unknown
7	Arrhythmia
14	Renal failure
20	Pneumonia
22	Brain hypertension
23	Respiratory failure
25	Heart and renal failure
27	Unknown
28	ECD
30	Infection
32	Heart failure
37	Invasive pulmonary aspergillosis
38	Sepsis due to rectal perforation
40	Heart failure
41	Heart failure
45	ECD

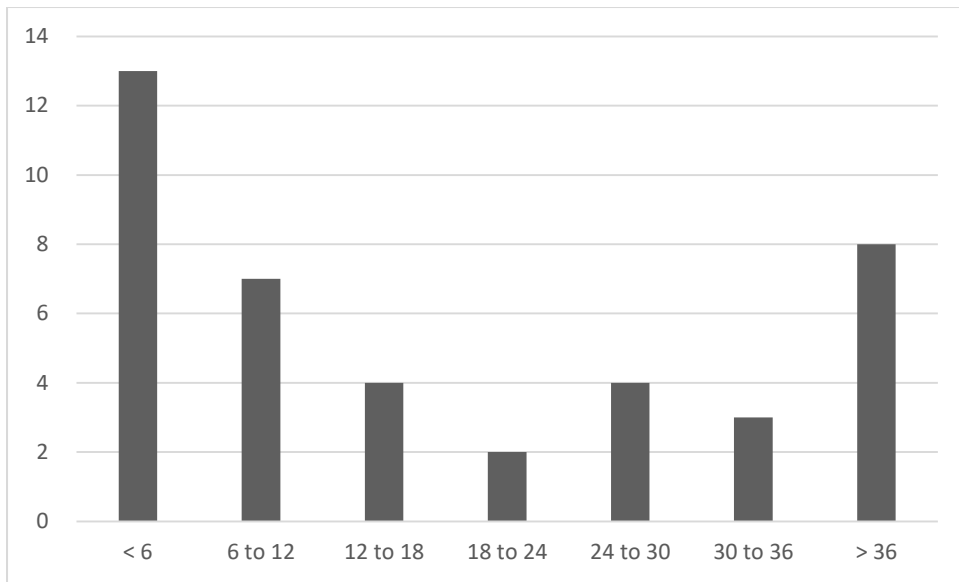
ECD indicates Erdheim–Chester disease;

Supplementary Table S3. *BRAF* mutation status of clinical samples

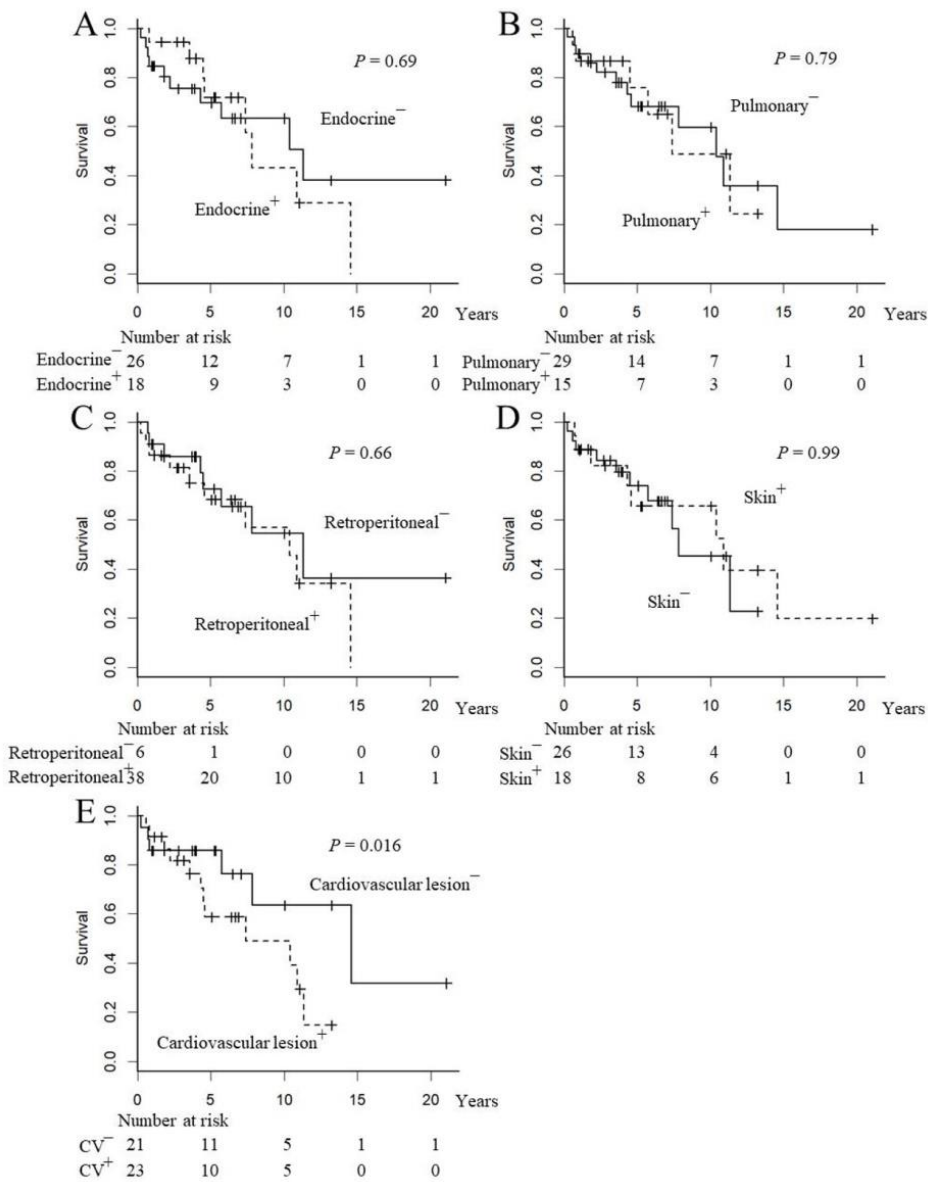
UPN	Type of sample	Sanger sequencing	<i>BRAF</i> mutation status of each patient
1	Skin	V600E	Mutation
	Bone	V600E	
2	Skin	V600E	Mutation
	Skin	V600E	
3	Bone	V600E	Mutation
7	Heart	V600E	Mutation
8	Tumor	V600E	Mutation
	PB (control)	Wild	
11	Bone	V600E	Mutation
	PB (control)	Wild	
16	Skin	Wild	Mutation
	Bone	V600E	
	PB (control)	Wild	
21	Bone	Wild	Wild
	PB (control)	Wild	
24	Skin	V600E	Mutation
29	Lung	Wild	Wild
	PB (control)	wild	
35	Brain	Wild	Wild
	Bone marrow (control)	Wild	
36	Skin	V600E	Mutation
	PB (control)	Wild	
39	Bone	V600E	Mutation
44	Bone	V600E	Mutation
	PB (control)	Wild	

UPN indicates unique patient number and PB, peripheral blood.

Wild means *BRAF*V600E mutation is absent.



Supplementary Figure S1. Duration between first sign of Erdheim-Chester disease and diagnosis. Patient number is shown according to the duration (months).



Supplementary Figure S2. Survival curve of patients with Erdheim–Chester disease. Kaplan–Meier estimation for survival from onset based on presence of (A) endocrine involvement, (B) pulmonary involvement, (C) retroperitoneal involvement, (D) cutaneous lesion, and (E) cardiovascular involvement. CV indicates Cardiovascular lesion.

Supplemental References

1. Furuta T, Kiryu S, Yamada H et al. Erdheim-Chester disease with an 18F-fluorodeoxyglucose-avid breast mass and BRAF V600E mutation. *Jpn J Radiol.* 2014; 32: 282-287.
2. Suzuki HI, Hosoya N, Miyagawa K et al. Erdheim-Chester disease: multisystem involvement and management with interferon-alpha. *Leuk Res.* 2010; 34:e21-24.
3. Tsukamoto M, Akahane M, Nangaku M. Image of Erdheim-Chester disease requiring hemodialysis. *Clin Exp Nephrol.* 2012; 16: 811-812.
4. Naruse H, Shoda H, Okamoto A et al. A case of osteoarthropathy due to Erdheim-Chester disease with overlapping Langerhans' cell infiltration. *Intern Med.* 2010; 49: 1225-1228
5. Manaka K, Makita N, Iiri T. Erdheim-Chester disease and pituitary involvement: a unique case and the literature. *Endocr J.* 2014; 61: 185-194.
6. Matsui K, Nagata Y, Hiraoka M. Radiotherapy for Erdheim-Chester disease. *Int J Clin Oncol.* 2007; 12: 238-241.
7. Takeuchi T, Sato M, Sonomura T et al. Erdheim-Chester disease associated with intramedullary spinal cord lesion. *Br J Radiol.* 2012; 85: e62-64.
8. Ono K, Oshiro M, Uemura K et al. Erdheim-Chester disease: a case report with immunohistochemical and biochemical examination. *Hum Pathol.* 1996; 27: 91-95.
9. Shimada S, Ono K, Hashizume Y et al. Intracranial lesion of Erdheim-Chester disease. *Hum Pathol.* 2007; 38: 950-951.
10. Yamaguchi M, Shiota T, Kobashi Y. Erdheim-Chester disease presenting with pneumothorax. *Respiration.* 2011; 82: 552-556
11. Taguchi T, Iwasaki Y, Asaba K et al. Erdheim-Chester disease: report of a case with PCR-based analysis of the expression of osteopontin and survivin in Xanthogranulomas following glucocorticoid treatment. *Endocr J.* 2008; 55: 217-223
12. Taguchi T, Sano S, Iwasaki Y, Terada Y. Symmetric giant xanthogranulomas in Erdheim-Chester disease. *Eur J Nucl Med Mol Imaging.* 2009; 36: 1198
13. Ota M, Sakamoto M, Sato K et al. Immunopathological analysis of Erdheim-Chester disease with massive ascites. *Intern Med.* 2012;51: 2825-2830
14. Kawashiri MA, Ishibashi-Ueda H, Funada A et al. Erdheim-Chester disease involving the brain and the heart. *J Am Coll Cardiol.* 2014; 63: 1121