

## **Additional file 2**

### **Kidney histopathology in lethal human sepsis: Heterogeneous damage and simultaneous repair**

**Adnan Aslan<sup>1,2</sup>, Marius C van den Heuvel<sup>3</sup>, Coen A Stegeman<sup>4</sup>, Eliane R Popa<sup>2</sup>, Annemarie M Leliveld<sup>5</sup>,  
Grietje Molema<sup>2</sup>, Jan G Zijlstra<sup>1\*</sup>, Jill Moser<sup>1,2</sup>, Matijs van Meurs<sup>1,2</sup>**

University of Groningen, University Medical Center Groningen

<sup>1</sup>Department of Critical Care

<sup>2</sup>Department of Pathology & Medical Biology, Medical Biology section

<sup>3</sup>Department of Pathology & Medical Biology, Pathology section

<sup>4</sup>Department of Nephrology

<sup>5</sup>Department of Urology

Hanzeplein 1

9700 RB Groningen, Netherlands

Correspondence: \* Jan G. Zijlstra, MD, PhD, BSc, University Medical Center Groningen,

University of Groningen, P.O. 30.001, 9700 RB Groningen, Netherlands.

E-mail: [j.g.zijlstra@umcg.nl](mailto:j.g.zijlstra@umcg.nl)

**Supplemental Table 3: Primary antibodies**

<b>Target antigen</b>	<b>target</b>	<b>clone</b>	<b>source</b>
Neutrophil elastase	Neutrophils	68672	Abcam, Cambridge, UK
CD3	Pan-T-lymphocytes	2GV6	Ventana Medical Systems, Tuscon, TX
CD4	Helper T-lymphocytes	SP35	Ventana
CD8	Cytotoxic T-lymphocytes	C8/144B	DAKO Heverlee, BE
CD20	B-lymphocytes	L-26	Ventana
CD68	Pan-macrophages	PG-M1	DAKO
IRF5	Type I macrophages		Proteintech, Manchester, UK
CD163	Type II macrophages	NCC-CD163	Novacastra Reagents, Leica, Eindhoven, NL
$\alpha$ -SMA	Myofibroblasts/SMC	1A4	Ventana
Ki-67	proliferation	30-9	Ventana
Act. caspase 3	apoptosis	9661	Cell Signaling, Danvers, MA

**Supplemental Table 4: Histopathological evaluation of glomeruli and tubulointerstitium**

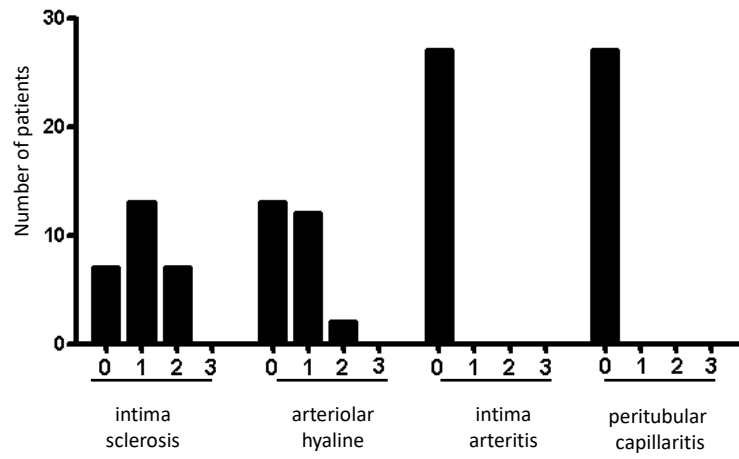
<b>Structure</b>	<b>Evaluation</b>
<b>Glomeruli</b>	
Total count (of all 27 patients)	926
Sclerotic (absolute count; percentage)	31 (3.35%)
Glomerulitis	None
Increase of mesangial matrix	All stage 0
<b>Tubulointerstitium</b>	
Tubulitis	None
Interstitial inflammation	2 (both patients stage 1)
Interstitial fibrosis	7 (all 7 patients stage 1)
Tubular atrophy	8 (all 8 patients stage 1)
<b>Vessels</b>	
Intima sclerosis	20 (13 patients stage 1, 7 patients stage 2)
Arteriolar hyaline	14 (12 patients stage 1, 2 patients stage 2)
Intima arteritis	None
Peritubular capillaritis	All patients stage 0

### Supplemental Table 5 Presence of acute tubular necrosis

	Sepsis	Control
<b>Signs of ATN (Yes/No)</b>	24/3	0/12
<b>Morphology</b>		
Stage 1	4	
Stage 2	18	n.a.
Stage 3	2	
<b>Extensiveness</b>		
Stage 1	19	
Stage 2	2	n.a.
Stage 3	2	
Stage 4	1	

n.a: not applicable

Figure S1



## Supplemental figure legend

### Figure S1: Vascular abnormalities

#### Intima sclerosis (%vessel lumen narrowing)

0: none; 1: -25%; 2: 25-50%; 3: >50%

#### Arteriolar hyaline

0: none, 1: small-moderate, 2: moderate-severe in multiple arteries, 3: severe in most arteries

#### Intima arteritis

0: none; 1: -25% vessel lumen narrowing; 2: >25% vessel lumen narrowing; 3: transmural arteritis, fibrinoid changes and media necrosis

#### Peritubular capillaritis

0: <10% capillaries containing inflammatory cells; 1: >10% capillaries containing 3-4 luminal cells; 2: >10% capillaries containing 5-10 luminal cells; 3: >10% capillaries containing >10 luminal cells