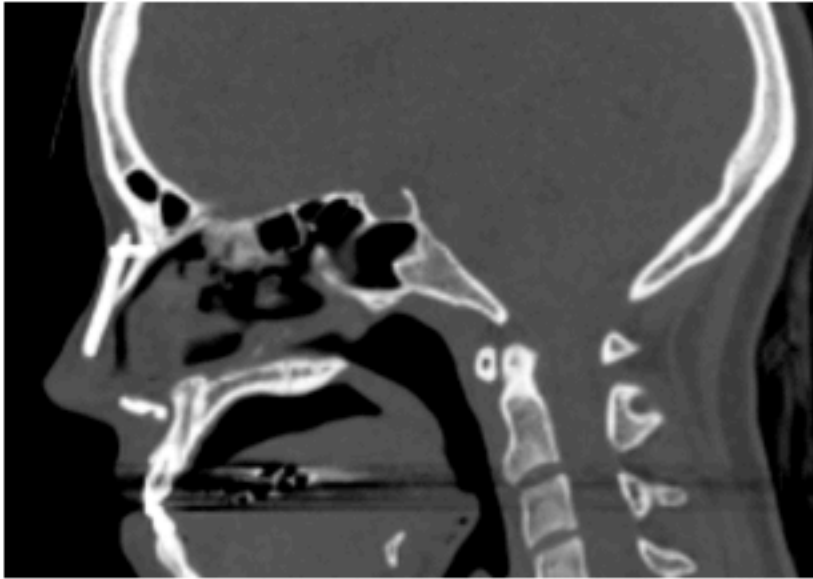
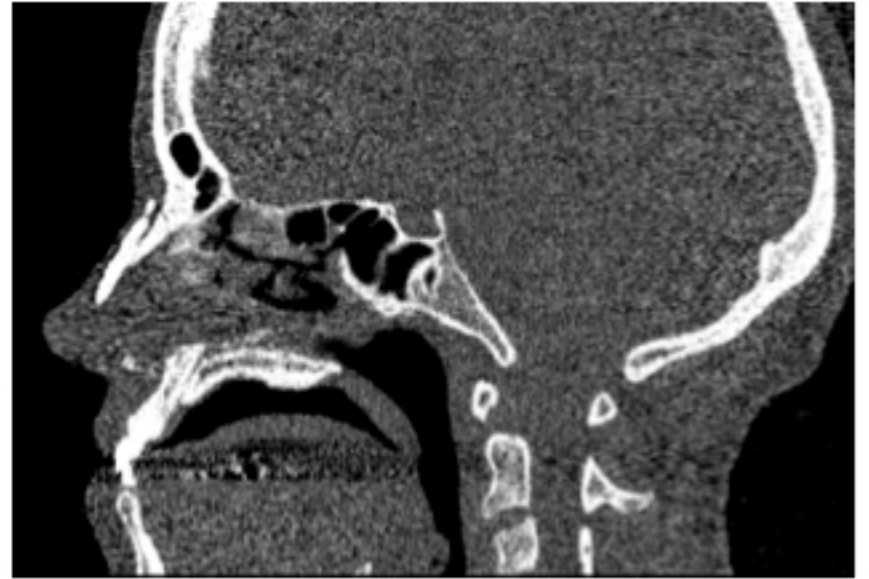

Case #1



CT Scan at 1 year



CT Scan at 8 years